

Received: 2019.07.10

Accepted: 2019.10.02

Published: 2019.12.14

# Omega-3 Fatty Acid Supplementation Reduces Intervertebral Disc Degeneration

Authors' Contribution:  
Study Design A  
Data Collection B  
Statistical Analysis C  
Data Interpretation D  
Manuscript Preparation E  
Literature Search F  
Funds Collection G

ABCDEFG 1,2  
ABDEF 1,3  
B 1,2,4  
B 1,2,4  
E 5  
BCDEF 5  
A 2  
DEG 1,2,4,6,7  
ADEF 1,2,3  
ABCDEFG 1,2,4

**Zachary NaPier**  
**Linda E.A. Kanim**  
**Yasaman Arabi**  
**Khosrowdad Salehi**  
**Barry Sears**  
**Mary Perry**  
**Sang Kim**  
**Dmitriy Sheyn**  
**Hyun W. Bae\***  
**Juliane D. Glaeser\***

1 Orthopaedic Stem Cell Research Laboratory, Cedars-Sinai Medical Center, Los Angeles, CA, U.S.A.  
2 Department of Orthopaedics, Cedars-Sinai Medical Center, Los Angeles, CA, U.S.A.  
3 Cedars-Sinai Spine Center, Cedars-Sinai Medical Center, Los Angeles, CA, U.S.A.  
4 Board of Governors Regenerative Medicine Institute, Cedars-Sinai Medical Center, Los Angeles, CA, U.S.A.  
5 Inflammation Research Foundation, Peabody, MA, U.S.A.  
6 Department of Surgery, Cedars-Sinai Medical Center, Los Angeles, CA, U.S.A.  
7 Department of Biomedical Sciences, Cedars-Sinai Medical Center, Los Angeles, CA, U.S.A.

\* Hyun W. Bae and Juliane D. Glaeser are shared senior authorship

Juliane D. Glaeser, e-mail: [Juliane.Glaeser@cshs.org](mailto:Juliane.Glaeser@cshs.org)

**Corresponding Author:**

**Source of support:**

This study was funded by the 2016 Cervical Spine Research Society Resident/Fellow Grant

**Background:** Intervertebral disc (IVD) degeneration is a common cause of lower back pain, which carries substantial morbidity and economic cost. Omega-3 fatty acids (n-3 FA) are known to reduce inflammatory processes with a relatively benign side effect profile. This study aimed to investigate the effect of n-3 FA supplementation on IVD degeneration.

**Material/Methods:** Two non-contiguous lumbar discs of 12 Sprague Dawley rats were needle-punctured to induce disc degeneration. Post-surgery, rats were randomly assigned to either a daily n-3 FA diet (530 mg/kg/day of eicosapentaenoic acid (EPA) and docosahexaenoic acid (DHA) in a 2: 1 ratio, administered in sucrose solution) or control diet (sucrose solution only), which was given for the duration of the study. After 1 month, blood serum arachidonic acid/eicosapentaenoic acid (AA/EPA) ratios were analyzed. After 2 months, micro-MRI (magnetic resonance imaging) analysis and histological staining of disc explants were performed to analyze the IVD.

**Results:** A reduction of blood AA/EPA ratios from 40 to 20 was demonstrated after 1 month of daily supplementation with n-3 FA. Micro-MRI analysis showed an injury-induced reduction of IVD hydration, which was attenuated in rats receiving n-3 FA. Histological evaluation demonstrated the destruction of nucleus pulposus tissue in response to needle puncture injury, which was less severe in the n-3 FA diet group.

**Conclusions:** The results of this study suggest that n-3 FA dietary supplementation reduces systemic inflammation by lowering AA/EPA ratios in blood serum and has potential protective effects on the progression of spinal disc degeneration, as demonstrated by reduced needle injury-induced dehydration of intervertebral discs and reduced histological signs of IVD degeneration.

**MeSH Keywords:** **Fatty Acids, Omega-3 • Intervertebral Disc Degeneration • Spine**

**Full-text PDF:** <https://www.medscimonit.com/abstract/index/idArt/918649>



2629



4



32



## Background

Intervertebral disc (IVD) degeneration is a common cause of low back pain, which carries substantial morbidity and economic cost. Low back pain is the fourth leading cause of physician visits in the United States [1], resulting in annual health-care costs ranging between \$50 and \$200 billion dollars [2].

IVD degeneration may be initiated by trauma, aging, or infection, which results in cellular and metabolic changes [3]. Structural failure of the nucleus pulposus (NP) is the hallmark feature of IVD degeneration, leading to subsequent defects in the surrounding annulus fibrosus and disc endplates [4].

Current pharmaceutical treatments for disc degeneration address symptoms but do not attenuate or delay the progression of this inflammatory and catabolic disease. Nonsteroidal anti-inflammatory drugs (NSAIDs), such as ibuprofen and naproxen, function via inhibition of cyclooxygenase (COX)-1 and -2 [5]. NSAIDs are the mainstay of nonsurgical treatment of discogenic pain despite having potentially devastating gastrointestinal, renal, and cardiovascular side effects [6].

Omega-3 fatty acids (n-3 FA) play an important role in the regulation and resolution of acute inflammation [7,8]. The anti-inflammatory properties of n-3 FA in musculoskeletal pathology have been comprehensively documented in peer-reviewed medical literature with a relatively benign adverse effect profile. Omega-3 FA supplementation has been demonstrated to reduce symptoms of osteoarthritis in canine [9,10] and human populations [11]. However, research related to n-3 FA supplementation for degenerative spinal pathology is very limited. A single retrospective study reported that n-3 FA dietary supplementation resulted in decreased pain and NSAID usage in patients with back pain due to degenerative disc disease or facet arthropathy. No significant adverse events were noted [12]. In a recent study, n-3 FA and co-enzyme Q10 administration through oral gavage in rats minimized immobilization-induced degeneration of tail discs [13]. To the authors' knowledge, the ability of n-3 FA to inhibit lumbar IVD degeneration has not been demonstrated.

Long chain fatty acids influence inflammation through different mechanisms. They are associated with changes in fatty acid composition of cell membranes, which can change membrane fluidity and cell signaling leading to altered gene expression [7]. Cells involved in the inflammatory response are typically rich in the n-6 FA, arachidonic acid (AA) [7]. Dietary uptake of the n-3 FA eicosapentaenoic acid (EPA) and docosahexaenoic acid (DHA) has been shown to diminish inflammation and pain via different pathways. EPA is a direct competitive inhibitor of AA, which is converted by cyclooxygenase (COX) and lipoxygenase (LOX) into the intermediate prostaglandin H<sub>2</sub>,

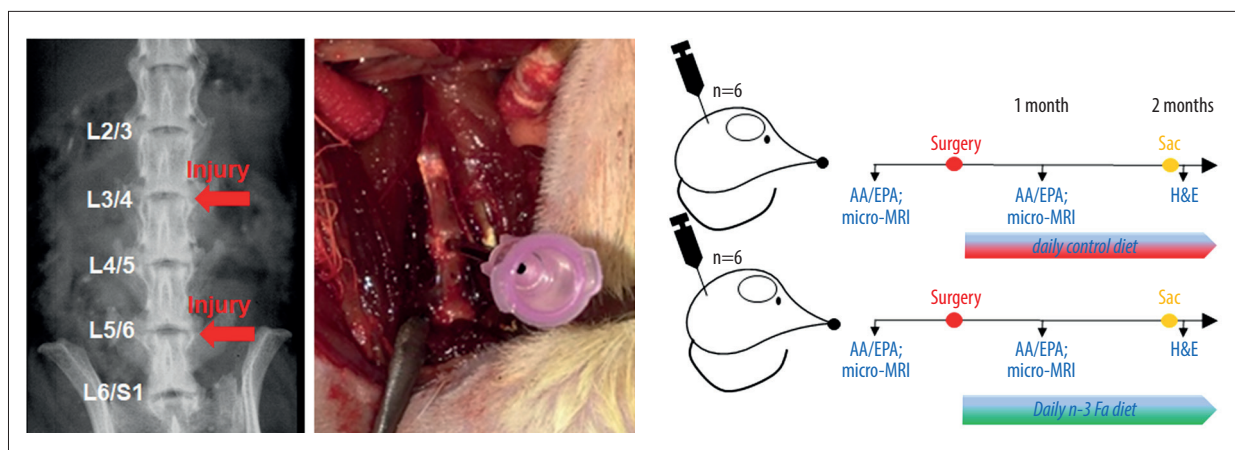
and further converted into pro-inflammatory eicosanoids [7]. Release of n-3 FA from cellular membranes in response to injury or natural degradation pathways has been shown to inhibit the production of pro-inflammatory eicosanoids [14]. Furthermore, both EPA and DHA are substrates for the production of specialized pro-resolving mediators (SPMs), a large and growing class of cell signaling molecules that play an important role in the resolution of acute inflammation and pain [15].

In this study, we hypothesize that dietary supplementation with n-3 FA attenuates lumbar IVD degeneration. Spinal disc injury was utilized to induce disc degeneration in rat. Rats were randomly assigned to a n-3 FA diet group or control diet group in the immediate postoperative period. Dietary supplementation was given daily for a duration of 2 months. Inflammation and spinal disc degeneration were detected via evaluation of serum AA/EPA ratios, micro-MRI and histology.

## Material and Methods

### Study design

To investigate the effect of n-3 FA supplementation on disc degeneration *in vivo*, a rat needle disc puncture model was employed as previously reported [16,17]. Twelve healthy, male CD<sup>®</sup> Sprague Dawley IGS rats (Charles River, MA, USA), 10 weeks of age were randomly assigned to either a n-3 FA (n-3 FA administered in sucrose solution) diet group or control (sucrose solution) diet group (6/12 rats per group). To avoid esophageal injury and restraint-associated distress as a result of daily gavage feeding, we administered n-3 FA by syringe feeding using 10% sucrose solution, a method that has been used to be an effective alternative to gavage feeding [18]. Starting on post-operative day 1, rats received a daily dose of n-3 FA (OmegaRx 2 Liquid Fish Oil, Zone Labs Inc., USA) applied with sucrose solution (0.25 mL of n-3 FA in 0.75 mL of 10% sucrose solution) or control diet (10% sucrose solution), given under supervision with a syringe for the duration of the experiment. Each mL of the n-3 FA solution contains 600 mg of EPA and 300 mg of DHA, and the average rat body weight was 425 g (350 g at surgery to 500 g at 2 months post-surgery). This results in a daily dose of 530 mg of EPA and DHA/kg body weight. This dose was chosen based on prior studies in showing anti-inflammatory effects of n-3 FA in diabetic rats when 500 mg/kg/day were administered [19]. Previous studies found no evidence of toxicity of oral n-3 FA supplementation at 2000 mg/kg/day in rats as summarized in a review by Chanda et al. [20]. Prior to surgery, rats were trained for a week to drink from the syringe. Pre-surgery and at 1-month post-surgery, blood values of arachidonic acid (AA, a pro-inflammatory omega 6 fatty acid) and eicosapentaenoic acid (EPA, an anti-inflammatory omega 3 fatty acid) were obtained and micro-MRI evaluation of the lumbar discs was performed. At 2 months



**Figure 1.** Study design. Left is a radiographic image of a rat lumbar spine. The red arrows indicate the sites of disc needle injury. Middle is anterior retroperitoneal approach to the lumbar spine with exposure of 3 consecutive discs with 18-gauge needle puncture of middle IVD. Right is post-surgery: rats were assigned to either the control (oral sucrose solution) group or n-3 FA diet group. Diet supplementation occurred daily for the duration of the experiment. AA/EPA blood and micro-MRI analyses were performed *in vivo*. Post-surgery, histological analysis was performed. Sac – day of sacrifice; IVD – intervertebral disc; n-3 FA – omega-3 fatty acids; AA/EPA – arachidonic acid/eicosapentaenoic acid; MRI – magnetic resonance imaging.

post-operatively, rats were sacrificed, and disc tissue was harvested for histological analysis of the IVD (Figure 1). Exclusion criteria were insufficient micro-MRI scan quality.

#### AA/EPA assay blot

After cleaning of the rat tail with ethanol, the tail vein was incised and approximately 0.1 mL of blood was collected on an AA/EPA assay blot card. The blood samples were analyzed using Arglient 5890 gas chromatography using flame ionization detection.

#### Animal surgery

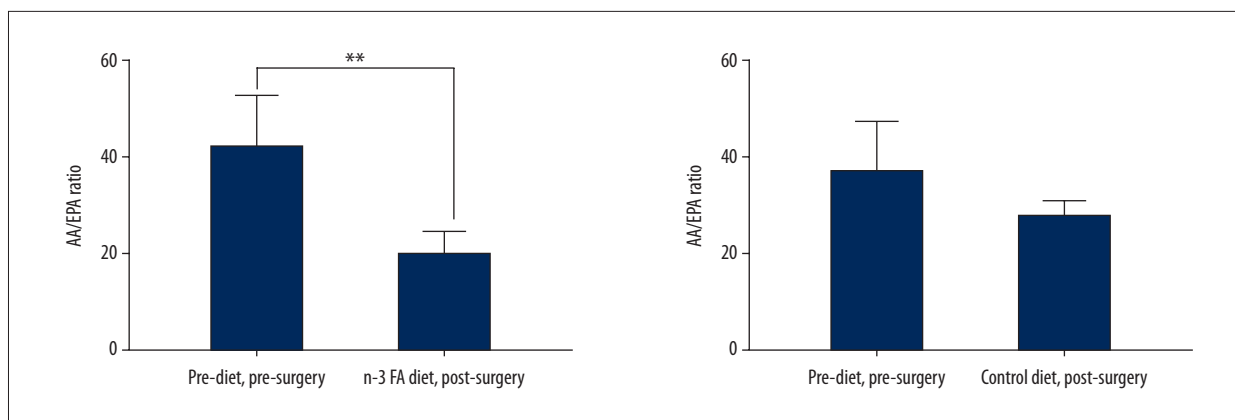
To investigate the effect of n-3 FA supplementation on disc degeneration *in vivo*, a rat needle disc puncture model was employed as previously reported [16,17]. Animal experiments were performed in accordance to Cedars-Sinai's Institutional Animal Care and Use Committee-approved protocol (#IACUC003364). Briefly, under anesthesia and after incision, a retroperitoneal approach to the lumbar spine was made and 2 non-continuous lumbar discs of L3/4 and L5/6 were punctured with an 18-gauge needle (1 mm diameter) to initiate injury in 12 Sprague Dawley rats, 3 months of age. The needle was inserted at the center of the disc level through the anulus fibrosus into the nucleus pulposus, rotated, held for 5 seconds, and removed. After treatment, the incision was closed, and warm fluids and pain medication (0.05 mg/kg buprenorphine, SC) were administered. Twelve hours after surgery, application of pain medication (0.05 mg/kg buprenorphine, SC) was repeated. Rats were single housed after surgery to minimize risk of injury through companions. The rats' welfare was assessed daily. No infections, poor conditions or drug related adverse events were detected.

#### Micro-MRI

Since reduction of water content is a common finding in intervertebral disc degeneration, disc hydration was measured using micro-MRI. Micro-MRI was conducted at the Imaging Core facility for MRI under the Imaging Core's approved protocol #003607 (Micro MRI Protocol for Molecular and Micro Imaging Core Facility for Rats). A small animal magnetic resonance imaging scanner, Bruker BioSpec 9.4T (94/20) with Advance III electronics 9.4T was employed with support of the Research Imaging Core, Cedars-Sinai Medical Center. Briefly, anesthetized rats were placed on the examining bed in the prone position. First, a series of axial, coronal and sagittal pilot proton density scans (TR: 50 ms, TE: 1.7 ms) were performed to ascertain the optimal angle for sagittal slice scanning. After obtaining satisfactory sagittal midsection proton density scans for outlining the disc location and size, sagittal T2-weighted scans with exact same imaging geometries were performed (TR: 5000 ms, TE: 30 ms). The level of disc hydration was quantitatively measured using MIPAV computer imaging software (Medical Image Processing, Analysis, and Visualization, NIH, Bethesda, MD, USA). Utilizing the iliac crest as the anatomical landmark for each scan, regions of interest (ROIs) of 5 consecutive intervertebral lumbar discs were manually contoured for measurements of high signal area values of the NP. In the figure, relative high signal area values of injured and uninjured NPs post-surgery compared to pre-surgery are shown.

#### Histology

After sacrifice, whole spines were explanted and fixed in 10% neutral-buffered formalin and decalcified in Leica Rapid



**Figure 2.** Reduction in serum AA/EPA ratio between pre-surgical and 4 weeks post-surgical rats receiving n-3 FA diet. Graphs show AA/EPA ratios tested in blood samples that were obtained pre-surgery, and after surgery in the n-3 FA diet group versus control diet group. n=4 per group. AA/EPA – arachidonic acid/eicosapentaenoic acid; n-3 FA – omega-3 fatty acids; MRI – magnetic resonance imaging.

Decalcifier II (Leica, USA) for 3 days. After decalcification, the spine was cut in the middle of the vertebral bodies from lumbar spine L2 until S1, resulting in single vertebral segments. Vertebral bodies were bisected in the mid-sagittal plane. Subsequently, the samples were rinsed, dehydrated, paraffin-embedded, and sectioned to a thickness of 5  $\mu$ m. The sections were stained with hematoxylin and eosin (H&E) and qualitatively analyzed by light microscopy for evidence of changes in the NP and AF. The stained slides were scanned with an Aperio R slide scanner (Leica Microsystems, USA). Features evaluated included the sharpness of the boundary between the NP and the AF and disruption of the AF.

### Statistics

All statistical analyses were performed using GraphPad Prism 7 software. For the AA/EPA ratio test, our analysis yielded a sample size of 3 to be sufficient to detect a 2-fold difference at a power of 80%. A paired *t*-test was performed for analysis of statistical differences between mean values of 1) blood values and one-way ANOVA was employed for analysis of 2) micro-MRI measures per spinal disc. Appropriate post hoc tests for multiple comparisons using Tukey's honestly significant was applied.  $P < 0.05$  was considered significant. In figures, mean values with standard deviations are shown.

## Results

### AA/EPA ratio is reduced with n-3 FA diet

In the n-3 FA group, average ratios of AA/EPA were significantly different between blood samples that were obtained pre-surgery versus post-surgery after rats had received daily n-3 FA diet supplementation for 1 month ( $P=0.0051$ , mean<sub>pre-surgery</sub>;

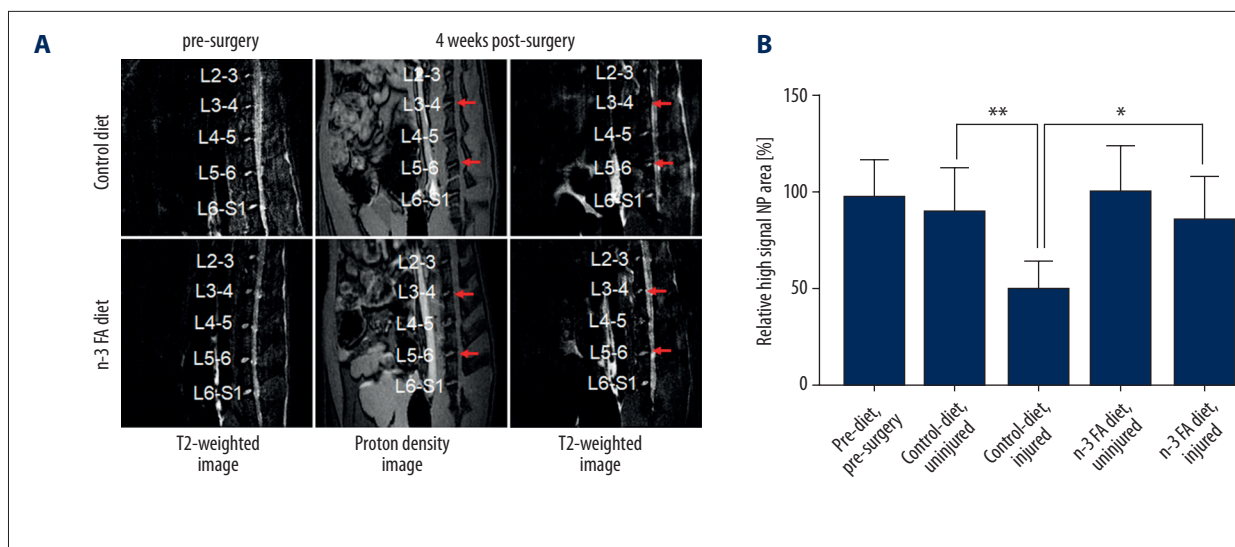
42.2±9.9 versus mean<sub>post-surgery</sub> 20.0±4.2). In the control group, no significant differences were detected between the pre-surgery and the post-surgery. At post-surgery, no statistical differences were found between n-3 FA and the control diet groups (Figure 2).

### Omega-3 FA diet rats demonstrate reduced disc dehydration

T2-weighted image analysis demonstrated a significant reduction of relative high signal NP area of injured versus uninjured discs ( $T2_{\text{control diet+uninjured}}: 89.8 \pm 11.4$ ,  $T2_{\text{control diet+injured}}: 49.6 \pm 13.7$ ;  $P=0.0003$ ). Furthermore, comparison of injured discs demonstrated a significantly higher relative high signal NP area in the n-3 FA group compared to the diet control group ( $T2_{\text{n-3 FA diet+injured}}: 85.4 \pm 22.2$ ;  $P=0.027$ ). No significant differences were observed between uninjured and injured discs of the n-3 FA diet group (Figure 3).

### Omega-3 FA diet rats demonstrate histologic evidence of attenuated disc degeneration

Qualitative evaluation of the histological sections of injured discs harvested from rats receiving control diet or n-3 FA diet showed morphological changes after needle puncture in both groups, which included destruction of the interface between nucleus pulposus and annulus fibrosus. However, in the n-3 FA diet group the degeneration appeared less severe with a visible interface between the NP and AF as well as relative preservation of NP architecture. In the uninjured groups, no differences were observed in the IVD morphology of rats receiving control diet or n-3 FA diet (Figure 4).



**Figure 3.** Injury-induced reduction in disc hydration is attenuated in rats receiving n-3 FA diet. **(A)** Representative T2-weighted and proton density images of the n-3 FA diet and control diet groups pre- and 1-month post-surgery. **(B)** Shows relative high signal NP area values of T2-weighted images. Data were normalized to pre-surgery/pre-diet scans.  $n \geq 6$  per group. n-3 FA – omega-3 fatty acids; NP – nucleus pulposus.

## Discussion

This study is the first to demonstrate that a n-3 FA diet of EPA and DHA attenuates IVD degeneration in a rat lumbar disc degeneration model. Daily oral supplementation of pharmaceutical grade n-3 FA for 2 months decreased injury-induced dehydration of intervertebral discs and reduced histological signs of IVD degeneration.

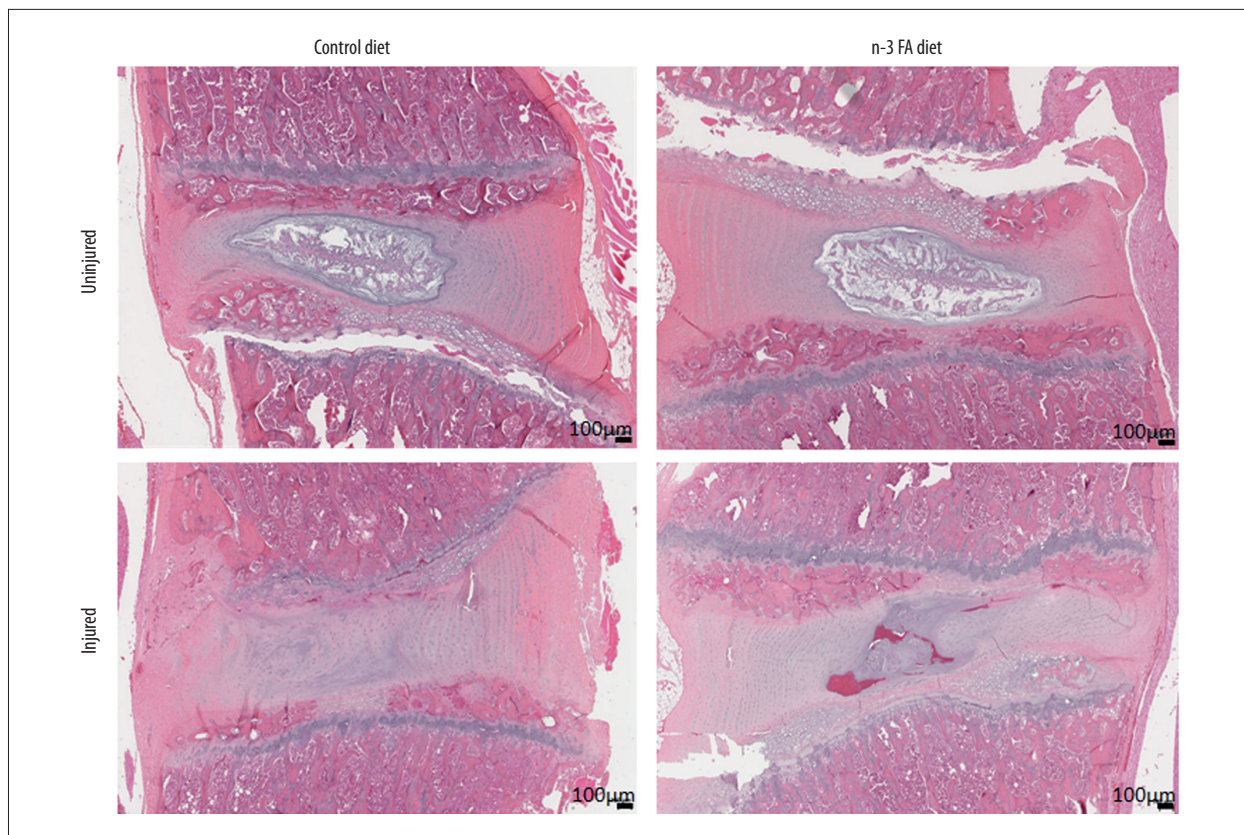
Successful oral n-3 FA intake was confirmed by detecting lower AA/EPA ratios in blood serum. Our study demonstrated a reduction of blood AA/EPA ratios from 40 to 20 after 1 month of daily oral supplementation with 530 mg/kg/day of pharmaceutical grade n-3 FA. In comparison, a 2-month n-3 FA diet (200 mg/kg/day) in Wistar rats resulted in a 3-fold to 4-fold decrease of the AA/EPA ratio [21]. Administration of 5 g of EPA and DHA per day for 6 weeks to healthy human subjects reduced levels of inflammatory cytokines and the AA/EPA ratio from 23 to 2.5 [22]. Differences between studies are likely a result of differences in baseline values, doses administered, duration of diet, or differences in the metabolism between species.

Micro-MRI analysis revealed a significant reduction in disc hydration in response to needle puncture in the control diet group. These results are in line with the literature, which demonstrate that needle puncture injuries in rodent IVDs reliably induce disc degeneration [23,24]. In the n-3 FA diet group, disc-dehydration was significantly diminished compared to the control diet group. While our study investigated a systemically applied therapeutic, local injection of anti-inflammatory agents has also been shown to reduce disc degeneration [24,25].

For example, intradiscal injection of an TNF- $\alpha$  blocking antibody has been shown to limit long-term pain and degeneration in a rat model [24]. Furthermore, injection of a PCL-PEG-PCL hydrogel releasing a COX-2 inhibitor into discs reduced IVD degeneration-associated back pain in dogs [26]. However, to our knowledge, there is no prior study showing the efficacy of a systemically delivered therapeutic for the reduction of disc degeneration in a rat model.

Histological analysis of the injured and uninjured IVDs at 2 months post-surgery indicated less pronounced disc degeneration in response to IVD needle puncture in the n-3 FA diet group compared to injured discs in the control diet group. Similar to our findings, reduced signs of IVD degeneration in response to local application of anti-inflammatory agents were demonstrated in prior studies [17,24]. For example, TNF $\alpha$  inhibition at time of IVD injury was shown to prevent IVD structural degeneration, including a less distinct NP-AF boundary [24]. While both systemic and local treatments may have the potential to attenuate IVD degeneration, a dietary approach has the benefit to be less invasive than injections into the IVD.

There are various mechanisms that may contribute to the observed effect of n-3 FA oral supplementation on the reduction of IVD degeneration: First, the detected reduction in the serum AA/EPA ratio in animals receiving a n-3 FA diet may result in a reduced production of AA-generated pro-inflammatory eicosanoids [27]. This in turn may diminish inflammatory processes and therefore attenuate disc degeneration, as demonstrated via micro-MRI and histological analysis in our study. Second, enhanced production of specialized pro-resolving



**Figure 4.** Destruction of nucleus pulposus in response to needle puncture injury is decreased in the n-3 FA diet group compared to control diet group. Shown are H&E staining of injured and uninjured rat lumbar discs from both groups at 2 months post-surgery. n-3 FA – omega-3 fatty acids; H&E – hematoxylin and eosin.

mediators (SPMs) derived from EPA and DHA [15], may be involved in the attenuation of disc degeneration in n-3 FA diet treated rats. The SPMs evoke potent anti-inflammatory mechanisms involving immune cells [28]. Although our study did not include the analysis of immune cells, we observed a more hydrated and intact disc tissue in n-3 FA diet treated rats, indicating either an attenuated degeneration process or an enhanced repair of the damaged tissue. Finally, antioxidant effects of n-3 FA, as previously reported in combinatory application with vitamin E [29], may contribute to the observed reduction of disc degeneration, since an association between oxidative stress and disc degeneration has been shown [30].

## Conclusions

This study suggests that n-3 FA dietary supplementation might have potential protective effects on the progression of spinal disc degeneration. Daily oral supplementation with 530 mg/kg/day of pharmaceutical grade n-3 FA for 2 months

decreased AA/EPA ratios in blood serum, and reduced signs of IVD degeneration, as demonstrated via micro-MRI analysis and histology. Omega-3 fatty acids might even more effectively resolve acute inflammation via SPM production than NSAIDs and COX-2 inhibitors; while n-3 FA are known to produce SPMs, NSAIDs and COX-2 inhibitors might inhibit this class of COX-2-activated cell signaling molecules [31,32]. Further research is needed to evaluate the effect of n-3 FA on disc degeneration in larger cohorts with different degrees of disc degeneration. Furthermore, n-3 FA dosing needs to be optimized. Randomized prospective clinical studies in humans as well as histologic and radiographic analysis of human discs are needed to further elucidate the efficacy of n-3 FA in reducing disc degeneration.

## Acknowledgements

The authors thank Shawn Wagner, PhD for help with micro-MRI analysis and Derek Ju, MD for copy editing the manuscript.

## References:

1. Deyo RA, Mirza SK, Martin BI: Back pain prevalence and visit rates: Estimates from US national surveys 2002. *Spine*, 2006; 31: 2724–27
2. Freburger JK, Holmes GM, Agans RP et al: The rising prevalence of chronic low back pain. *Arch Intern Med*, 2009; 169: 251–58
3. Risbud MV, Shapiro IM: Role of cytokines in intervertebral disc degeneration: pain and disc content. *Nat Rev Rheumatol*, 2014; 10: 44–56
4. Yang S-H, Hu M-H, Sun Y-H, Lin F-H: Differential phenotypic behaviors of human degenerative nucleus pulposus cells under normoxic and hypoxic conditions: influence of oxygen concentration during isolation, expansion, and cultivation. *Spine J*, 2013; 13: 1590–96
5. Hilario MO, Terreri MT, Len CA: Nonsteroidal anti-inflammatory drugs: Cyclooxygenase 2 inhibitors. *J Pediatr (Rio J)*, 2006; 82: S206–12
6. Harewood G: Gastrointestinal toxicity of nonsteroidal antiinflammatory drugs. *N Engl J Med*, 1999; 341: 1398; author reply 1398–99
7. Calder PC: Omega-3 fatty acids and inflammatory processes. *Nutrients*, 2010; 2: 355–74
8. Basil MC, Levy BD: Specialized pro-resolving mediators: Endogenous regulators of infection and inflammation. *Nat Rev Immunol*, 2016; 16: 51–67
9. Fritsch DA, Allen TA, Dodd CE et al: A multicenter study of the effect of dietary supplementation with fish oil omega-3 fatty acids on carprofen dosage in dogs with osteoarthritis. *J Am Vet Med Assoc*, 2010; 236: 535–39
10. Roush JK, Cross AR, Renberg WC et al: Evaluation of the effects of dietary supplementation with fish oil omega-3 fatty acids on weight bearing in dogs with osteoarthritis. *J Am Vet Med Assoc*, 2010; 236: 67–73
11. Gruenwald J, Petzold E, Busch R et al: Effect of glucosamine sulfate with or without omega-3 fatty acids in patients with osteoarthritis. *Adv Ther*, 2009; 26: 858–71
12. Maroon JC, Bost JW: Omega-3 fatty acids (fish oil) as an anti-inflammatory: An alternative to nonsteroidal anti-inflammatory drugs for discogenic pain. *Surg Neurol*, 2006; 65: 326–31
13. Mushtaq F, Qamar A, Ali M, Rauf SE: Immobilization induced degeneration in intervertebral discs of rats and protective effects of omega 3 fatty acids and CoQ10. *Europe Journal of Anatomy*, 2018; 22: 383–87
14. Wall R, Ross RP, Fitzgerald GF, Stanton C: Fatty acids from fish: The anti-inflammatory potential of long-chain omega-3 fatty acids. *Nutr Rev*, 2010; 68: 280–89
15. Norris PC, Skulas-Ray AC, Riley I et al: Identification of specialized pro-resolving mediator clusters from healthy adults after intravenous low-dose endotoxin and omega-3 supplementation: A methodological validation. *Cli Rep*, 2018; 8: 18050
16. Zhang H, La Marca F, Hollister SJ et al: Developing consistently reproducible intervertebral disc degeneration at rat caudal spine by using needle puncture. *J Neurosurg Spine*, 2009; 10: 522–30
17. Than KD, Rahman SU, Wang L et al: Intradiscal injection of simvastatin results in radiologic, histologic, and genetic evidence of disc regeneration in a rat model of degenerative disc disease. *Spine J*, 2014; 14: 1017–28
18. Atcha Z, Rourke C, Neo AH et al: Alternative method of oral dosing for rats. *J Am Assoc Lab Anim Sci*, 2010; 49: 335–43
19. Ghadge A, Harsulkar A, Karandikar M et al: Comparative anti-inflammatory and lipid-normalizing effects of metformin and omega-3 fatty acids through modulation of transcription factors in diabetic rats. *Genes Nutr*, 2016; 11: 10
20. Chanda W, Joseph TP, Guo XF et al: Effectiveness of omega-3 polyunsaturated fatty acids against microbial pathogens. *J Zhejiang Univ Sci B*, 2018; 19: 253–62
21. Bacova B, Sec P, Certik M, Tribulova N: Intake of n-3 polyunsaturated fatty acids increase omega-3 index in aged male and female spontaneously hypertensive rats. *ISRN Nutr*, 2013; 2013: 209360
22. Endres S, Ghorbani R, Kelley VE et al: The effect of dietary supplementation with n-3 polyunsaturated fatty acids on the synthesis of interleukin-1 and tumor necrosis factor by mononuclear cells. *N Engl J Med*, 1989; 320: 265–71
23. Li D, Yang H, Huang Y et al: Lumbar intervertebral disc puncture under C-arm fluoroscopy: A new rat model of lumbar intervertebral disc degeneration. *Exp Anim*, 2014; 63: 227–34
24. Evashwick-Rogler TW, Lai A, Watanabe H et al: Inhibiting tumor necrosis factor-alpha at time of induced intervertebral disc injury limits long-term pain and degeneration in a rat model. *JOR Spine*, 2018; 1: pii: e1014
25. Wu X, Liu Y, Guo X et al: Prolactin inhibits the progression of intervertebral disc degeneration through inactivation of the NF-kappaB pathway in rats. *Cell Death Dis*, 2018; 9: 98
26. Tellegen AR, Willems N, Beukers M et al: Intradiscal application of a PCLA-PEG-PCL hydrogel loaded with celecoxib for the treatment of back pain in canines: What's in it for humans? *J Tissue Eng Regen Med*, 2018; 12: 642–52
27. Lone AM, Tasken K: Proinflammatory and immunoregulatory roles of eicosanoids in T cells. *Front Immunol*, 2013; 4: 130
28. Serhan CN, Chiang N, Dalil J: The resolution code of acute inflammation: Novel pro-resolving lipid mediators in resolution. *Semin Immunol*, 2015; 27: 200–15
29. Sepidarkish M, Akbari-Fakhrabadi M, Daneshzad E et al: Effect of omega-3 fatty acid plus vitamin E co-supplementation on oxidative stress parameters: A systematic review and meta-analysis. *Clin Nutr*, 2019 [Epub ahead of print]
30. Feng C, Yang M, Lan M et al: ROS: Crucial intermediators in the pathogenesis of intervertebral disc degeneration. *Oxid Med Cell Longev*, 2017; 2017: 5601593
31. Gilroy DW, Colville-Nash P, Willis D et al: Inducible cyclooxygenase may have anti-inflammatory properties. *Nat Med*, 1999; 5: 698
32. Serhan CN, Chiang N, Van Dyke TE: Resolving inflammation: Dual anti-inflammatory and pro-resolution lipid mediators. *Nat Rev Immunol*, 2008; 8: 349–61