



Multiple fractures in infants who have Ehlers-Danlos/hypermobility syndrome and or vitamin D deficiency: A case series of 72 infants whose parents were accused of child abuse and neglect

M. F. Holick, A. Hossein-Nezhad & F. Tabatabaei

To cite this article: M. F. Holick, A. Hossein-Nezhad & F. Tabatabaei (2017) Multiple fractures in infants who have Ehlers-Danlos/hypermobility syndrome and or vitamin D deficiency: A case series of 72 infants whose parents were accused of child abuse and neglect, *Dermato-Endocrinology*, 9:1, e1279768, DOI: [10.1080/19381980.2017.1279768](https://doi.org/10.1080/19381980.2017.1279768)

To link to this article: <https://doi.org/10.1080/19381980.2017.1279768>



© 2018 The Author(s). Published with license by Taylor & Francis© M. F. Holick, A. Hossein-Nezhad, and F. Tabatabaei



Published online: 16 Feb 2017.



Submit your article to this journal [↗](#)



Article views: 11089



View related articles [↗](#)

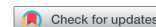
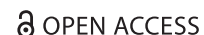
View Crossmark data [↗](#)



Citing articles: 16 View citing articles [↗](#)

RESEARCH PAPER



Multiple fractures in infants who have Ehlers-Danlos/hypermobility syndrome and or vitamin D deficiency: A case series of 72 infants whose parents were accused of child abuse and neglect

M. F. Holick ^a, A. Hossein-Nezhad^{a,b}, and F. Tabatabaei^a

^aDepartment of Medicine, Section of Endocrinology, Nutrition, and Diabetes, Vitamin D, Skin, and Bone Research Laboratory, Boston University Medical Campus, Boston, MA, USA; ^bOsteoporosis Research Center, Endocrinology and Metabolism Clinical Sciences Institute, Tehran University of Medical Sciences, Tehran, Iran

ABSTRACT

Objective: To increase the level of awareness that Ehlers-Danlos/hypermobility syndrome (EDS) and vitamin D deficiency are associated with infantile fragility fractures and radiologic features that may be mistakenly reported to be caused by non-accidental trauma due to Child Abuse and Neglect (CAN).

Patients and Methods: We constructed a case series, the largest to date, of infants with EDS who were vitamin D sufficient, insufficient and deficient and infants without EDS but with documented vitamin D deficiency and radiologic evidence of rickets who presented with multiple fractures originally diagnosed as being non-accidental and caused by child abuse. These infants were referred to the outpatient Bone Health Care Clinic at Boston University Medical Campus over a 6-year (2010–2015) period. We also present 6 index cases in which the court concluded that there was no convincing evidence of child abuse and the infants were returned to their parents. Institutional Review Board (IRB) approval was obtained.

Results: We present 72 cases of infants with multiple fractures diagnosed to be caused by non-accidental trauma. All infants were younger than one year of age. Among them, 93%(67) had clinical evidence of EDS and/or a family history with a confirmed clinical diagnosis of at least one parent having EDS and the other 7%(5) without evidence of EDS had vitamin D deficiency/infantile rickets. Three of the EDS infants were diagnosed as osteogenesis imperfecta (OI)/EDS overlap syndrome. The most common fractures noted at diagnosis were ribs and extremity fractures (including classic metaphyseal lesions). Serum levels of 25-hydroxyvitamin D [25(OH)D] were reported in 48 infants (18.0 ± 8.5 ng/ml) and in 30 mothers (21.3 ± 11.7 ng/ml). Sixty-three percent (27) of the EDS infants who had their serum 25(OH)D measured were vitamin D deficient 25(OH)D < 20 ng/ml and 5 were vitamin D sufficient 25(OH)D > 30 ng/ml. The mean serum level for infants with vitamin D deficiency/rickets was (10.2 ± 3.0 ng/ml)

Conclusion: EDS, OI/EDS and vitamin D deficiency/infantile rickets are associated with fragility fractures in infants that can be misinterpreted as caused by non-accidental trauma due to child abuse.

ARTICLE HISTORY

Received 23 November 2016
Revised 16 December 2016
Accepted 1 January 2017



KEYWORDS

CAN; child abuse and neglect; classic metaphyseal lesions; Ehlers-Danlos syndrome; fracture; fragility fracture; hypermobility; infant; rickets; vitamin D deficiency

Introduction

Child Abuse and Neglect (CAN) is a serious public health crisis that has major implications for the welfare of the child involved. Inflicted non-accidental skeletal injuries are the second most common manifestation of child abuse after soft tissue injuries.¹ There are several genetic disorders and congenital defect conditions that have been associated with bone fragility and fractures that can be misdiagnosed as child

abuse.²⁻⁴ Osteogenesis Imperfecta (OI) is the most common genetic abnormality associated with multiple unexplained fractures in an infant or child that can be misdiagnosed as child abuse.³⁻⁶ Moreover, rickets and Ehlers-Danlos/hypermobility syndrome (EDS), which are associated with normal or low bone density and increased bone fragility, can also result in X-ray findings that can be mistaken for child abuse.⁷⁻¹³

CONTACT M. F. Holick  mfholick@bu.edu  Vitamin D, Skin and Bone Research Laboratory, Division of Endocrinology, Diabetes and Nutrition, Department of Medicine, Boston University School of Medicine, 85 East Newton Street, Boston, MA 02118, USA.

© 2018 M. F. Holick, A. Hossein-Nezhad, and F. Tabatabaei. Published with license by Taylor & Francis.

This is an Open Access article distributed under the terms of the Creative Commons Attribution-NonCommercial-NoDerivatives License (<http://creativecommons.org/licenses/by-nc-nd/4.0/>), which permits non-commercial re-use, distribution, and reproduction in any medium, provided the original work is properly cited, and is not altered, transformed, or built upon in any way.

EDS is a genetic disease that affects collagen synthesis and structure resulting in multisystem connective tissue involvement with twelve different subtypes.¹⁴ The clinical manifestations of EDS include skin hyperextensibility, skin fragility, joint hypermobility, muscle hypotonia, easy bruising, and mast cell hypersensitivity.¹⁴ Moreover, fragility fractures with normal or low bone density has been reported among both pediatric and adult patients with EDS.¹⁵⁻¹⁹ EDS has been reported in the literature to be misdiagnosed as CAN due to unexplained facial scars and skin lesions,^{8,9,11} It has also been reported that EDS can present with a congenital skull fracture at birth.²⁰ To our knowledge there has been no reported cases in the literature that link non-accidental fractures among infants with EDS and OI/EDS. However, concerns regarding the likelihood of increased risk for fractures among infants with EDS and the OI overlap syndrome and the possibility for misdiagnosing CAN have been raised.²¹

Rickets is a metabolic bone disease most commonly caused by vitamin D deficiency.²²⁻²⁷ This deficiency results in demineralization of the skeleton due to secondary hyperparathyroidism as well as a mineralization defect of newly laid down osteoid. Vitamin D also plays a critical role in chondrocyte maturation and as a result vitamin D deficiency results in growth plates that have abnormal mineralization and ossification.²⁵⁻²⁷ The poorly mineralized skeleton of a rachitic child increases risk for fragility fractures^{13,22-24} and has been reported to be misdiagnosed as CAN.^{7,10,12} Similar bone lesions can be seen on an X-ray in both vitamin D deficiency rickets and infants and children suspected of being abused making it difficult to differentiate between these two conditions.¹² Moreover, these two conditions can be found simultaneously in one patient.²⁸

Classic Metaphyseal Lesions (CMLs), also referred to as corner fractures or bucket handle fractures, were first attributed to Caffey who noted unusual radiologic lucencies in the growth plates in the long bones in 6 infants born between 1925 and 1942 who presented with subdural hematomas.²⁹ Originally it was concluded that this radiologic finding was caused by a small piece of bone that was avulsed and considered due to shearing forces on the fragile growth plate. As a result of this interpretation of this radiologic finding most pediatric radiologists and child abuse experts consider it to be pathognomonic for non-accidental trauma.³⁰ However Kleinman et al³¹ who introduced the term metaphyseal lesion (now known as classic metaphyseal lesion;CML) proposed that

this radiologic lucency was not an avulsion but rather was due to a transplanar micro-fracture of unknown etiology. They also concluded that most bucket-handle lesions are not associated with displaced fractures but were in fact a result of a nonorthograde radiologic protection. These radiographic findings are often subtle and easily misinterpreted as fractures³² These lesions can be found in infants and children with vitamin D deficiency rickets as well as in children with the collagen matrix genetic disorder OI.^{3,4,7}

Acquired and genetic disorders of bone, such as vitamin D deficiency and EDS, are quite common^{26,33-35} and may be overlooked in infants who present with rib or extremity fractures in various stages of healing at several skeletal sites including CMLs. The importance of recognizing these conditions is stressed as it may save these families from the horrific consequences of being considered a child abuser including loss of their child and their other children to adoption, the possibility of being incarcerated as a felon and having their names placed on the child abuse registry limiting their present and future employment possibilities.

We present 72 cases of infants who presented with multiple fractures. Most were evaluated along with their parents for evidence of acquired or inherited bone diseases.

Patients and methods

Case series

This is a case series of 72 infants with multiple fractures originally diagnosed as caused by alleged child abuse at other institutions and came to the Bone Health Care Clinic at Boston University Medical Campus (BUMC) for a second opinion. The parents were first interviewed on the phone to determine if there were extenuating circumstances that could help explain the cause and origin of the fractures before being evaluated in the clinic. Once it was determined by the telephone conversation that there was clinical evidence for vitamin D deficiency or that one of the parents had clinical signs for hypermobility syndrome that was often unbeknownst to them, they (and when possible their infant) were scheduled and seen in the clinic over a 6-year (2010–2016) period. Medical records from BUMC and the accompanied medical records from other institutions were reviewed. The following information was gathered from the records: previous diagnosis at other institutions, age in weeks, number of fracture fractures and their location

(s), past medical history for Joints Hypermobility Syndrome (JHS), EDS, OI, clinical signs and symptoms of rickets and EDS, family history for EDS, laboratory results, radiology reports and images, and genetic testing results. Parent(s) were evaluated for clinical evidence of EDS. The infants of these parents, who were often accompanied by a caretaker, were also evaluated for clinical evidence of EDS and signs and symptoms of vitamin D deficiency and evidence for infantile rickets. Six cases of infants presenting with multiple fractures in various stages of healing that were adjudicated resulting in the child/children returned to their parent(s) were selected as index cases. This study for reviewing patient's medical records was approved by the Boston University Medical Center's IRB.

Results

Seventy-two infants (41 boys; 57%) including 6 twins (8%) presented with conditions including multiple fractures and soft tissue injury that were allegedly considered to be caused by child abuse. The mean age of these infants who initially presented with fractures was 12 ± 8.4 weeks (range between 2–40 weeks; 10.3 weeks in males and 14.3 weeks in females). Ninety-three percent (67) had clinical evidence of EDS and/or a family history of at least one parent having clinical symptoms of EDS who was evaluated in the clinic confirming the diagnosis. Most of these parents were not aware that they had this genetic disorder. Seven percent (5) of the infants had no evidence of EDS. Infants were categorized into two main categories, infants with EDS who were vitamin D deficient, insufficient, or sufficient^{3,4,7} and infants with no family history or clinical evidence of EDS but who had evidence for vitamin D deficiency and radiologic evidence and or clinical evidence for rickets. Family members and the infant were evaluated in 64% (43) of the cases from the EDS group. Due to the unavailability of the infant only family members were evaluated in 36% (24) of the cases from the EDS group. Moreover, 3 of the EDS infants had evidence of OI/EDS overlap syndrome and were vitamin D deficient.

Specific fractures

The most common fractures noted at diagnosis were ribs and extremity fractures. Sixty-one percent (44) of the infants had rib fracture(s). CMLs were reported in 18% (13) of the cases. Thirty-nine percent (28) of the

Table 1. Site distribution of fractures in all infants.

Fracture sites ^a	EDS N = 67% (n)	Vitamin D deficiency/Rickets N = 5%(n)
Ribs (left or right)	23(39)	100(5)
Femur	41(24)	80(4)
Humerus	41(16)	0(0)
Tibia	18(22)	60(3)
Skull	10(6)	60(3)
Other ^b	31(19)	60(3)
CMLs	18(11)	40(2)

^aAt least one fracture in these sites.

^bOther fractures sites were in scapula, pelvic, radius, ulna, fibula, clavicle, and metatarsals.

extremity fractures occurred in femur, 22% (16) in humerus and 35%(25) in tibia. Skull fractures were noted in 13% (9) of the infants. (Table 1)

Clinical features

The clinical features of the infants with fractures at various stages of healing at diagnosis that were diagnosed with EDS are represented in Table 2. The clinical features identified among infants with EDS who were evaluated were family history of joint hypermobility and blue/gray sclera in the infants, doughy textured skin, increased skin elasticity, soft tissue involvement, and hypermobility/flexibility (Table 2).^{3,4,7,36} The parenteral history of joint hypermobility was confirmed when one or both parents were evaluated in the clinic and demonstrated classic clinical signs for Ehlers Danlos/hypermobility syndrome with a Beighton score of at least 5/9 which is diagnostic for this genetic disorder.^{3,4,7,37} The

Table 2. Diagnostic basis for infants with EDS.

Basis of EDS diagnosis	Total EDS N = 67%(n)
Infant cases seen at BUMC ^a N = 43	
Family history of hypermobility confirmed in clinic with mean (SD) Beighton score ^b 8(±1)	100(43)
Soft tissue involvement ^c	58(25)
Easy bruising	21(9)
Flushing	42(18)
Blue/gray sclera	77(33)
Doughy skin	84(36)
Skin elasticity	74(32)
Hypermobility/flexibility	100(43)
Frontal bossing	47(20)
Parents of infants not seen at BUMC N = 24	
Hypermobility/flexibility	100(24)
Mean (SD) Beighton score	8(±1)

^aBoston University Medical Campus

^bData were available for 19 cases

^cGastroparesis, Gastric reflux, or Heart murmur

Table 3. Clinical and radiological features in infants with rickets.

Case #	Radiological evidence of rickets
1	Rachitic rosary, classic metaphyseal lesion and hypertrophied costochondral junctions.
2	Wide anterior fontanelle, shell like teeth, and craniotabes.
3	Rachitic rosary, zones of provisional calcification, and parasutural hypomineralization, classic metaphyseal lesion.
4	Rachitic rosary and Looser's zone.
5	Craniotabes, rachitic rosary, and zones of provisional calcification

radiological signs of rickets among infants who presented with fractures at various stages of healing at diagnosis were rachitic rosary, wide anterior fontanel(s), craniotabes, and perisutural hypomineralization (Table 3). Clinical evidence for rickets included frontal bossing and rachitic rosary.^{3,4,7}

Genetic screening

Genetic screening for OI was performed in 65%(47) of the infants; no causative variants in the COL1A1 and COL1A2 genes were found. However 4%(3) of the infants were diagnosed with OI/EDS overlap syndrome; a causative variant in the SERPINF1 gene was found in two of the cases and in the third case the diagnosis was confirmed by ultrastructural analyses of a skin biopsy.

Table 4. Biochemical measurements in all infants.

Serum levels	EDS (Mean \pm SD) (N)	Vitamin D Deficiency/Rickets (Mean \pm SD) (N)
Infant 25(OH)D ^a (ng/mL)	18.5 \pm 8.7 (43)	12.8 \pm 5 (4) ^e
25(OH)D <20 (ng/mL)	13.1 \pm 4.5 (27)	
25(OH)D >20 (ng/mL)	27.7 \pm 5.7 (16)	
Mother 25(OH)D ^a (ng/mL)	22.8 \pm 11.7 (28)	14 \pm 0 (2)
ALP ^b (U/L)	490.3 \pm 225 (23)	478.6 \pm 288.1 (5)
For infants with 25(OH)D <20 (ng/mL) ^c	533.8 \pm 224.7 (16)	—
For infants with 25(OH)D >20 (ng/mL) ^c	325.6 \pm 92.3 (5)	—
Calcium (mg/dL)	9.8 \pm 0.8 (21)	10 \pm .2 (4)
Phosphorus (mg/dL)	5.4 \pm 0.9 (16)	5.5 \pm 1.2 (4)
PTH ^d (pg/mL)	48.5 \pm 29.5 (16)	89.7 \pm 25.1 (4)
For infants with 25(OH)D <20 (ng/mL) ^c	50.7 \pm 28.5 (11)	—
For infants with 25(OH)D >20 (ng/mL) ^c	31.3 \pm 4.2 (3)	—

^a25-hydroxyvitamin D,

^balkaline phosphatase,

^cOnly data for infants with available 25(OH)D level were included in the analysis.

^dParathyroid hormone

^eOne infant was excluded from the analysis because 25(OH)D level was done after receiving high dose of vitamin D; 25(OH)D was reported to be 20.7 ng/mL and the mean would be (14.3 \pm 5.6) if the result was included in the analysis.

Biochemical findings

The biochemical findings are presented in Table 4. Serum levels of 25(OH)D were reported in 47 infants (18 \pm 8.5 ng/mL) and 31 of them were deficient (<20 ng/mL). Sixty-three percent (27) of the EDS infants who had their serum 25(OH)D level measured were vitamin D deficient [25(OH)D<20ng/mL]. Of the other 37% (16), 11 were vitamin D insufficient [25(OH)D 21–29 ng/mL and 5 were vitamin D sufficient [25(OH)D> 30 ng/mL].³⁸ Moreover, the 25(OH)D level was reported in 30 mothers and the mean was 21.3 ng/mL (\pm 11.7 ng/ml), and 16 of them were deficient (<20 ng/mL). Alkaline phosphatase, parathyroid hormone (PTH), calcium, and phosphorus mean values were reported Table 4.

Selected study patients

Index cases of parents who had their child/children returned to their care.

Case 1. Vitamin D deficiency rickets

This is a 2 month old black male who presented with a skull depression with no scalp swelling. Head CT scan showed a skull depression on the left parietal bone. There was no intracranial hemorrhage, or evidence of brain injury.

Skeletal survey reported the following 14 fractures: depressed deformity of the left parietal calvarium, acute/subacute fractures involving the left 2nd-8th ribs posteriorly, cortical irregularity of the distal left ulna, and metaphyseal irregularity consistent with remote fractures involving the bilateral distal femurs and proximal and distal tibiae. There was asymmetric periosteal reaction of the diaphyseal right tibia. There was periosteal elevation of the left proximal ulna and waviness of radius. There was also periosteal reaction noted along the right tibia.

The initial physical examination of the infant upon presentation revealed that he had a skull depression. The patient was thought to have stable fractures and no neurosurgical intervention was indicated. Skin was normal and sclera did not appear to be gray/blue. The patient had no visible bruising. The extremities had normal range of motion with no obvious tenderness or angular deformities. There was no clinical evidence of OI. The fractures were considered to be due to non-accidental trauma. The mother, a New York City lawyer and the father, a software engineer, were arrested

and accused of felony child abuse. The infant was removed from the parents and given to the care of the grandmother. The mother suffered from hyperemesis due to emesis gravidarum during most of her pregnancy and was unable to take any calcium supplementation or a prenatal vitamin.

An evaluation of the infant's blood biochemistries revealed a 25(OH)D of 11 ng/mL and elevated levels of alkaline phosphatase 755 U/L (reference range 65–500U/L), PTH 125 pg/mL (reference range 15–85 pg/ml), and 1,25(OH)₂D 115 pg/mL (reference range 10–75 pg/ml). The patient was evaluated for OI and found to be negative for a causative variant in the COL1A1 and COL1A2 genes.

Case 2. Vitamin D deficiency rickets

This 3 month old black female infant presented with lower right leg swelling and tenderness. An evaluation revealed a non-displaced fracture of the right tibia and possible healing fracture of the right femur. A further evaluation with skeletal survey revealed an acute fractures of the distal right tibia and right first metatarsal and healing fractures of the left tibia, posterior right 10th and 11th ribs, right clavicle, right acromion, mid-portion of the left radius and ulna, and mid-portions of the right radius and ulna and of the proximal phalanx of the left third digit. There was periosteal reaction around the right humerus and suspected metaphyseal fractures of the distal humerus, distal left radius and distal left femur. Her vital signs were normal. Growth parameter were abnormal for weight (4.18 kg at 3 month old) and head circumferences (35.5) being <3rd percentile. Head, ears, eyes, nose, and oral examination was normal. Skin was normal and sclera did not appear to be gray/blue. The fractures were considered to be caused by non-accidental trauma and the parents (both in the Air Force) were arrested for child abuse and the child was removed from their care.

The mother had history of vitamin D deficiency and sarcoidosis. The infant was breast fed for the first three months of life.

Serum chemistries revealed that the infant had a calcium of 10.0 mg/dL (reference range is 8.5–10.2 mg/dl), phosphorus of 4.0 mg/dL (reference range is 3.5–6.6 mg/dl), elevated levels of alkaline phosphatase of 967 U/L (reference range is 60–260 U/l and parathyroid hormone level of 67 pg/mL (reference range is 10–65 pg/ml) and a undetectable level of 25(OH)D of

<13 ng/mL (reference range 20–100 ng/mL). A repeat blood level after one month also revealed that the infant remained vitamin D deficient with a 25(OH)D of 14.8 ng/mL. Her mother was found to be vitamin D deficient with a 25(OH)D of 14 ng/mL.

A genetic evaluation was performed and there was no evidence of OI in this patient.

Case 3. EDS and Vitamin D deficiency

This is a 4 month old white female who presented with a left femoral fracture. At 16 weeks of age the patient fell on an armrest while dad was holding her. She was fussy and taken to the emergency department. The next day she was found to have a left femoral fracture. A skeletal survey reported the following 12 fractures: two linear fractures through the right parietal bone, healing fracture of the lateral right fifth rib, non-displaced fracture through the anterolateral fifth and sixth ribs with no adjacent callus, expansion of the anterior end of the seventh and eighth ribs, healing mid-diaphyseal fractures through the right radius and ulna with abundant adjacent callus formation, an acute greenstick fracture of the distal left radius, acute comminuted mid-diaphyseal fracture through the left femur with one shaft width anterior displacement of the distal fracture fragment, and subtle contour abnormality of the left distal anterior femoral metaphysis suspicious of buckle injury. An evaluation of her twin sister revealed a similar number of fractures in various stages of healing. The CT 3D reconstruction of the skull showed areas of thinning, wide sutures, large anterior fontanel in the skull, and shell like teeth. The fractures were considered to be caused by non-accidental and the mother, who is a physical therapist and the father, who is in the special-forces in the Army, were arrested for child abuse. The twins as well as their other 3 children were removed from their care and placed in foster care.

On physical examination, the infant had square-like skull and mild frontal bossing. She had blue sclera and marked increased flexibility of her finger joints, elbows, shoulders, and hips. She was able to arch her head backward in almost a C-like position. During physical examination she had flushing of her face with no obvious precipitating cause.

The 33-year-old mother had preeclampsia and the patient was born approximately halfway through the third trimester alongside her twin sister. The twin girls were placed in the NICU for 2 weeks for severe

jaundice. The patient and her twin sister were breast-fed for the first 4 months and were not provided with vitamin D supplementation.

The mother had been previously diagnosed with EDS type 3. On physical examination she had doughy textured skin with increased elasticity and increased flexibility of most of her joints. She was evaluated for joint hypermobility using the standard Beighton scoring evaluation³⁹ and she exhibited a score of 9 out of 9. She mentioned that her mother, grandmother, and son were also extremely flexible.

Both twins were found to be vitamin D deficient. The patient had a 25(OH)D of 7 ng/mL. She also had an elevated PTH of 97 pg/mL (reference range 10–55 pg/mL) and an elevated alkaline phosphatase of 783 U/L (reference range is 65–500 U/L). She had low phosphorus level of 3.3 mg/dL and normal calcium of 8.8 mg/dL. Her twin sister had a 25(OH)D of 9 ng/mL, PTH of 36 pg/mL (reference range 10–55 pg/mL), phosphorus of 2.6 mg/dL (reference range 4.0–5.5 mg/dL for infants), and calcium of 9.3 mg/dL (reference range 8.6–10.5 mg/dL).

The patient and her twin were evaluated for OI and found to be negative for a causative variant in the COL1A1 and COL1A2 genes.

Case 4. EDS and Vitamin D deficiency

This 4 month old white female presented with unexplained right femoral transverse fracture. A radiological evaluation concluded that there was a fracture of the right mid-femoral shaft with ventral angulation of approximately 69 degrees. No significant displacement is identified. No additional fractures were identified. No definitive dislocation is identified. Mineralization was within normal limits. No focal bone destruction was identified. The fracture was considered to be caused by non-accidental and the mother, a board-certified nephrologist and the father, a physician were accused and arrested for child abuse and the child was removed from their care and placed into foster care.

The infant was breast-fed and did not receive any vitamin D supplementation. The initial physical examination of the infant upon presentation showed that her sclera were bluish in color. Her skin was doughy in texture with increased elasticity. She was able to hyperextend the fifth digits of her hands. She had hyperextensible elbows and knees. Her skull exam revealed that it was square in shape with frontal bossing.

The 33 year old mother had no family history for osteoporosis, but had family history of hypermobility. She also stated she often had partial dislocation of her left hip when she walked. Physical exam of the mother revealed that her skin was very doughy in texture with increased elasticity. She had marked increased flexibility of her joints and she had a Beighton score of 9/9 with hyperextendable elbows, knees, first digit of her fingers and she was able to touch the floor with the palms of her hands.

A metabolic evaluation of the infant at the time of fracture revealed a 25(OH)D of 12 ng/mL (reference range 30–100 ng/mL), PTH of 46 pg/mL (reference range 15–65 pg/mL), calcium of 8.9 mg/dL (reference range 8–10.5 mg/dL), phosphorus of 5.3 mg/dL (reference range 4.2 – 6.5 mg/dL) and alkaline phosphatase of 339 U/L (reference range 65 – 500 U/L). Whereas the infant was vitamin D deficient all of the other biochemistries were normal and not indicative for infantile rickets.

Case 5. EDS and Vitamin D deficiency

The father, who is in the Army, noted leg swelling in his 7 week old Native Alaskan American daughter when he was changing her diaper before putting her down to sleep. The next morning the patient was noted to have a swelling on her upper right leg and was brought to the emergency department for further evaluation. A radiological evaluation concluded that there was a right mid-femur fracture, classic metaphyseal lesions of the left distal tibia and right distal tibia. The bone survey showed healing fracture mid-shaft left clavicle, healing fracture with abundant callus formation involving the right first through eight ribs and the left sixth and seventh ribs, subtle fracture of the distal left femoral metaphysis and the proximal and distal medial metaphysis of the right tibia. Also bone survey showed spiral fracture of the proximal diaphysis of the right femur which is angulated with apex projecting anterior and overriding of the fracture fragments. Head and brain CT without contrast indicated that no acute intracranial pathology or evidence for traumatic injury. These fractures were considered to be caused by non-accidental trauma and the parents were arrested for child abuse and the infant was placed in foster care.

She was term with a history of a NICU stay for clinical sepsis since mom had choriomnionitis (intra-amnionic infection). On physical examination, she was crying and fussy. Sclerae were white. She had bruise over her face, near the left eye and her mother stated that she bruises

easily and this bruise might have developed while she was holding her while breastfeeding. She had conjunctival hemorrhage on the medial aspect of her right eye. She had normal vital signs without acute distress. There was no pathological finding in head and neck, respiratory, cardiovascular, gastrointestinal, genitourinary, musculoskeletal, integumentary and neurological system. Anterior fontanel was open, soft and flat.

The infant was breast-fed and did not receive any vitamin D supplementation. The 27 year old native Alaskan mother, who worked as an executive secretary before they took her child away, had been previously diagnosed with Ehlers-Danlos syndrome. She stated as a child and young adult she experienced easy flushing without any precipitating cause and developed light-headedness when she stood up quickly. On physical exam she was extremely flexible with hyperextensible elbows, knees, easily able to hyperextend her fingers and to extend her thumbs to touch her wrists. She was unable to touch the floor with the palm of her hands but this could have been due to her being overweight. She had a Beighton score of 8/9. Infant's father did not complain of being hyperflexible or having any signs or symptoms for Ehlers-Danlos/hypermobility syndrome.

Serum biochemistries of the infant revealed a calcium of 8.1 mg/dL (reference range 7.6–11 mg/dL), phosphorus of 3.5 mg/dl (reference range 4.5–6.5 mg/dL) and elevated levels of PTH that was 258 pg/mL (reference range 15–65 pg/mL), alkaline phosphatase of 1,015 U/L (reference range 40–417 U/L) and 1,25 (OH)D of 100 pg/mL (no reference range was established by this reference laboratory for children under 1 year of age; reference range above one year 10–75 pg/mL). The 25(OH)D was 4 ng/mL (reference range 30–100 ng/mL). The patient was evaluated for OI and found to be negative for a causative variant in a dominant OI panel and a combined OI panel.

Case 6. EDS and Vitamin D sufficiency

This is a 2 month male infant who presented with left leg swelling and nasal abrasion. The infant was born by normal spontaneous vaginal delivery at home at a nurse midwife assisted delivery. His mother had pregnancy-induced hypertension which was controlled with diet. An X-ray revealed a spiral fracture of the left femur. Skeletal survey reported the following 10 fractures: corner fracture at the distal tibial metaphyseal reaction, possible fracture of the anterior 3rd-7th ribs, compression fracture of L2 vertebral body,

healing fractures of the right mid-clavicle and distal left clavicle, and a bucket handle type metaphyseal fracture of the distal right tibia (Fig. 1). MRI was

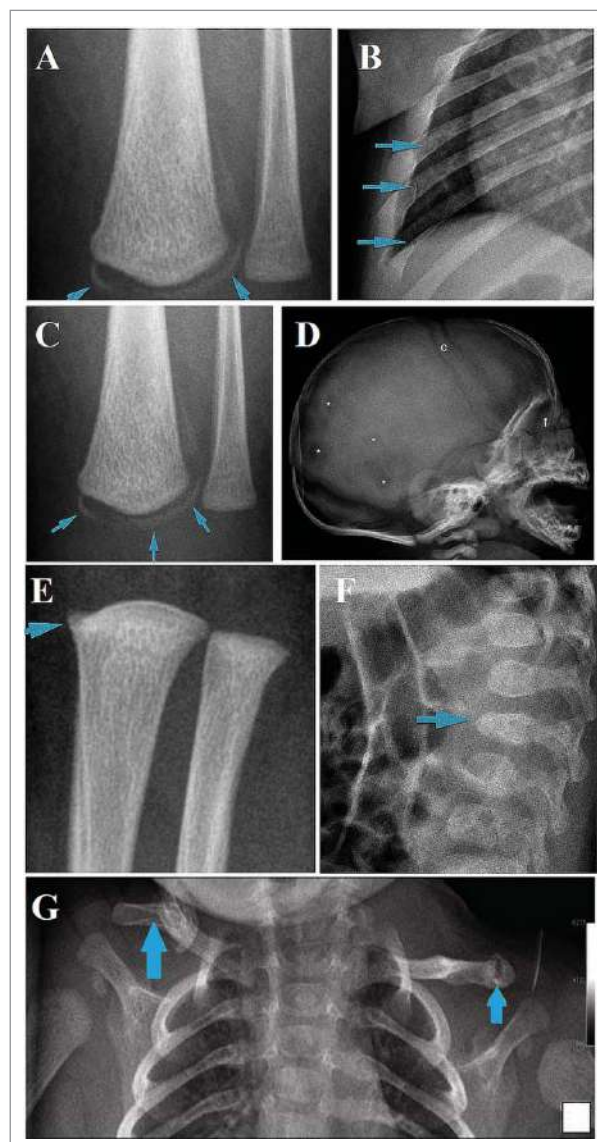


Figure 1. (A) Lower left leg x-ray shows a slipped epiphysis with migration of a thickened perichondrial ring (blue arrows), early periosteal reaction and callus. (B) Right rib films shows transverse fractures (blue arrows) of several right anterior ribs with cupping of the costochondral margins. (C) The distal right tibia shows a prominent perichondrial ring or spur (blue arrows). (D) Lateral skull film shows poor mineralization of the mid facial bones (f) and along the coronal sutures (c) with numerous posterior calvarial defects or craniotabes (*). (E) Right wrist film shows prominent perichondrial ring or spur (arrows) of the distal radius. There are also subtle Park-Harris lines in the distal radial metaphysis. (F) Lateral spine film shows non acute compression deformity of L2 vertebra (blue arrow). (G) There is a fracture in the mid shaft of the right clavicle; the left clavicle has a lucent hole, most likely an osteoid seam. The right clavicle appears as disorganized old callus. These presentations most likely occurred at birth and healed slowly and poorly.

normal. On physical examination the infant was found to have blue sclera, doughy-textured skin, increased skin elasticity, joint popping (partial subluxation) of his right shoulder, and hypermobility of his fingers and elbow joints. There was no evidence of frontal bossing or rickets either in his wrists or in his legs. At the time of the fracture he had a 25(OH)D of 36 ng/mL, calcium of 11.3 mg/dL, phosphorus of 6 mg/dL, PTH of 3 pg/mL, and alkaline phosphatase of 409 U/L. Genetic testing was done for the COL1A1 and COL1A2 and it was negative. Both parents who were nursing students were arrested and charged with felony child abuse and their infant was removed from her care and placed in foster care.

There was strong family history of grandmother and mother having EDS. On physical exam the mother's sclera were slightly blue, especially around the cornea bilaterally. She had marked increased elasticity, doughy textured skin, and increased flexibility in her joints. She was able to extend her knees and elbows to greater than 10 degrees. She had hyperflexibility of her thumbs and was able to touch the floor with the palms of her hands. She had a Beighton score of 9/9. She stated she bruised easily without trauma. She also has a history of irritable bowel syndrome. All of her symptoms including gastroparesis, orthostatic hypotension, marked increased flexibility and easy bruising were consistent with her having EDS. Early in her pregnancy, she was found to be vitamin D deficient and placed on 12,000 IUs of vitamin D a day for 6 weeks and then switched to 10,000 IUs a day throughout her pregnancy, and continued this until the infant was 2 months of age. She was evaluated for 25(OH)D during her third trimester, and it was found to be 47 ng/mL.

Discussion

To our knowledge, there are no reports in the literature of EDS that may be mistaken as caused by non-accidental trauma in infants who were also evaluated for their vitamin D status. We presented 72 infants with documented multiple fractures, some with soft tissue injury and X-ray findings that were alleged to be caused by non-accidental trauma and the parents either under suspicion or arrested for felony child abuse. What is remarkable is that in 93% of these cases at least one parent had clinically documented evidence for the EDS (even though most were not aware they had this genetic disorder); a genetic disorder that

compromises the structural integrity of the collagen/elastin matrix and is well recognized as a cause for fractures in adults.^{14,15,36} The other 7% had no clinical evidence for EDS but did have clear evidence for vitamin D deficiency with blood levels of 25(OH)D of 10.3 ± 3.0 which is associated with rickets and fragility fractures.^{13,25,28,40,41} In addition 63% of the infants with EDS who were tested for their vitamin D status were also vitamin D deficient.

There has been an enormous amount of contentious controversy regarding vitamin D deficiency, rickets and other metabolic bone disorders other than OI as the causative factor for fragility fractures that can be misdiagnosed as being caused by non-accidental trauma due to child abuse.^{5,29,30,32,42-46} Current knowledge for the differential diagnosis of non-accidental trauma and fractures is based on numerous publications dating back to 1946.^{5,29,30,32,42-46} It is recognized by the child abuse community and law enforcement that there are several genetic disorders including OI that are associated with bone fragility that can result in an infant presenting with multiple fractures in various stages of healing and thus infants suspected of CAN are routinely tested for these genetic disorders with various biochemical tests as well as the genetic test for OI.³⁰

Hess in 1929 in his treatise on rickets reported an ulnar midshaft fracture as an incidental finding in an X-ray of child with rickets.²⁴ Shore and Chesney⁴⁷ documented that vitamin D deficiency and insufficiency causes hypo-mineralization of the skeleton increasing risk for minimal trauma fractures as documented in a 1-year-old child who fell out of bed and sustained a midshaft femoral fracture.²⁷ Cannell and Holick reported 2 cases of parents being accused of child abuse because their infants presented with multiple fractures. The infants had documented biochemical and radiologic evidence for rickets and the children were returned to their parents. In addition, metaphyseal dysplasia, disorders of phosphate metabolism, temporary brittle bone disease, and infantile rickets are also documented in the literature as causative factors for bone fragility resulting in infantile fractures.^{4,5,10}

Vitamin D deficiency during infancy and early childhood affects the skeleton in 3 separate ways compromising its structural integrity increasing risk for fragility fractures and X-ray findings that can be misdiagnosed as fractures.^{25,26} Vitamin D deficiency reduces the efficiency

of intestinal calcium absorption leading to secondary hyperparathyroidism. PTH interacts with its receptor on osteoblasts to increase the expression and production of receptor activator of NF κ B ligand (RANKL). RANKL interacts with precursor monocytic cells inducing them to amalgamate and becoming multi-nucleated osteoclasts. Osteoclasts release HCl to dissolve the calcium hydroxyapatite in the skeleton as well as collagenases to dissolve the matrix resulting in a decrease in bone mineral content. PTH also causes phosphate wasting in the kidneys resulting in a decrease in serum phosphate levels. Although the serum calcium is preserved in the normal range by the dissolution of the skeleton by osteoclasts the lower phosphate level results in an inadequate calcium phosphate product and any new collagen matrix laid down in the skeleton by osteoblasts cannot be mineralized i.e. vitamin D deficiency causes a mineralization defect. In addition to these two skeletal insults caused by vitamin D deficiency the third consequence is a disruption in chondrocyte maturation at the ends of the growth plates that can appear as classic metaphyseal lesions and so-called corner or bucket-handle fractures.^{22-24,40} disruption leads to potential fraying and disruption of the epiphyseal plates.^{22-24,40} When observed these radiolucencies are considered by many in the child abuse community to be pathognomonic for nonaccidental trauma due to child abuse.⁴⁸ However due to growth plate hypomineralization and alteration in chondrocyte maturation in rachitic children, their bones are softer (osteomalacia/rickets) and can bend, bow, and are more prone to having epiphyseal fragility and separation resulting in a radiolucency.^{24,22-24,28}

Ayoub et al.⁷ reported that these lesions are not specific for child abuse and they can be found in other conditions, specifically in healing infantile rickets supporting Chesney²⁸ who found that CMLs and rib fractures can be seen in children alleged to being abused and in infants and children with rickets. However, Perez-Rossello et al.⁴⁹ reported an archival review (1984–2012) of 46 consecutive infant fatalities referred for possible child abuse. Nine infants mean age 3.9 months (age range 1–9 months) were identified with CML's and no histologic evidence of rickets. As noted by the authors they had no biochemical information on the infants including their vitamin D status, thus to conclude that infantile vitamin D deficiency was not associated with CML's cannot be ascertained from their study. Also, their conclusion was based in part on their observation of excessive hypertrophic

chondrocytes as a reliable indicator of healing CML's. However this is also a histologic finding for rickets.⁷ It has been reported by experts reading high resolution radiographs of wrists and knees that radiolucencies in the growth plate are not uncommon but that CML's were not observed.⁵⁰ It is quite possible that to a less experienced pediatric radiologist that these radiolucencies could be misinterpreted as CML's. Epiphyseal separations are designated as a moderate-specificity injury. This separation occurs through the cartilaginous physis usually with displacement of the epiphysis^{29,30} because the epiphyses are not mineralized in young infants or are only slightly ossified. This displacement may either not be apparent to the casual observer or may appear as a subtle irregularity at the metaphyseal end. Alteration in chondrocyte maturation due to vitamin D deficiency could exacerbate the presence of this radiolucency observed in a skeletal survey. The so-called rib fractures occurring at the costochondral junctions both anteriorly and posteriorly could also be due to costochondral hypertrophy due to the vitamin D deficiency induced alteration of chondrocyte maturation rather than caused by an accidental trauma.^{10,12}

Vitamin D deficiency rickets with a radiologic diagnosis of multiple fractures caused by non-accidental trauma has been reported.^{7,10,51} Keller and Barnes¹⁰ published four cases of non-accidental fractures and discussed that these fractures are not due to abuse but due to vitamin D deficiency rickets. They concluded that many of the so-called fractures were classic radiologic signs for rickets including transverse lucencies with sclerotic borders also misinterpreted as classic metaphyseal lesions; horizontal lucencies at the growth plate interpreted as fractures and flared hypertrophied ribs at the growth plates of the costochondral junctions interpreted as rib fractures in various stages of healing. Paterson¹² in his review concluded that fractures in rickets are often spontaneous and often asymptomatic and may lead to the suggestion of nonaccidental injury as the cause. These two papers generated a hot debate.⁵¹⁻⁵⁵ Contreras et al.⁵⁶ could not find any relationship between vitamin D deficiency and increasing risk for fracture; this could be due to the fact that there was no evidence for rickets. El Sakka et al.⁵⁷ did observe that vitamin D deficiency was two times more prevalent for fracture compared to a non-fracture group. This observation is consistent with Chapman et al.⁵⁸ who retrospectively evaluated

X-rays of 45 children between the ages of 2 and 24 months (4 under the age of 7 months) who had rickets. Of the 40 children with nutritional, congenital or secondary rickets 7 were found to have at least one fracture and all had nutritional rickets. They found that the fractures that occurred in older infants and toddlers with overt rickets were mobile and that the fractures were different to those observed as caused by nonaccidental trauma.

Schilling et al.⁵⁹ reported on vitamin D status in abused and non-abused children younger than 2 years and found only 8% were vitamin D deficient [25(OH)D <20 ng/mL] while 31% were insufficient [25(OH)D 20–29 ng/mL]. Although they recognized that rib and metaphyseal radiographic abnormalities occurred in several metabolic bone disorders including rickets they concluded that vitamin D insufficiency was not associated with multiple fractures or diagnosis of child abuse. A prospective study of 40 infants and toddlers with vitamin D deficiency [25(OH)D <20 ng/mL] who had bilateral wrist and knee computed radiographs reported that rachitic changes and hypomineralization were uncommon and fracture risk was low.⁵⁰ This study had a small sample size of rachitic infants; however, they did acknowledge in an 11-month-old child with a 25(OH)D of 11 ng/mL had partial lucency of the zone of provisional calcification and loss of metaphyseal margin in the medial and lateral distal femoral metaphysis and the lateral proximal tibia metaphysis. They did not however see any metaphyseal fragmentation. This study did not include a skeletal survey so it is unknown whether any additional skeletal abnormalities might have been observed including hypertrophy of costochondral junctions of the rib cage.

Marfan's syndrome and OI are conditions that result from compromised structural integrity of the collagen/elastin/fibrin matrix. The compromised matrix results in well-known clinical consequences including aortic dissection and brittle bones respectively.^{60,61} Astley et al.³ reported small metaphyseal fractures in children with OI that resembled those seen in non-accidental injury. In 2011 Singh-Kocher and Dichtel⁴ reported 33 cases with confirmed diagnosis of OI that were misdiagnosed as child abuse. Children were removed from the family in 70% of the cases and older siblings were removed from the family in 62% of cases.

EDS belongs to a spectrum of genetic disorders including Marfan's syndrome and OI affecting the

structural integrity of the collagen/elastin/fibrin matrix. The compromised matrix in EDS patients has several consequences including hyperextensible and fragile skin, easy bruising, poor wound healing and atrophic scarring and joint laxity resulting in subluxation and joint destruction. More subtle consequences are gastroparesis, orthostatic hypotension, and postural orthostatic tachycardia syndrome (POTS), and unexplained allergies-flushing-hives due to mast cell hypersensitivity.^{14,36,62} The diagnosis for EDS in adults is made based on a variety of maneuvers demonstrating joint hypermobility known as a Beighton score; a score of at least 5 of a total of 9 maneuvers is considered to be characteristic for EDS/hypermobility.^{36,37,39,63} In addition the diagnosis is supported by doughy-textured skin that can also have increased elasticity.^{39,63} Although blue sclerae are classic physical sign for OI, it has been reported that 67% of patients with EDS also have blue sclerae.^{33,39,63} In our case series blue sclera was found in 77% of the cases.

Since collagen/elastin/fibrin is a major component of the skeleton that provides the scaffolding for calcium hydroxyapatite, it would not be at all unexpected that a defect in the scaffolding would result not only in decreased bone mineralization but also a mineralized structure that had inherent weaknesses. It would be similar to constructing a bridge using plastic Rebar in place of steel. The cement i.e., calcium hydroxyapatite would crack with minimum stress. Thus, children and adults with EDS can have normal or decreased bone mineral density and increased risk for fragility fractures.^{17,64-66}

What is remarkable about this case series is that 93% of parents accused of CAN had a clinical diagnosis of at least one parent having EDS. Most of the parents were unaware they had this genetic disorder and it was made for the first time in our clinic. It is unlikely that this genetic disorder predisposes parents to abuse their children. Our observations are consistent with the report of increased joint laxity among parents of 81 children with temporary brittle bone disease and fractures in which 40 had at least one parent with joint laxity.⁶⁷

At the present time an infant presenting with multiple fractures in various stages of healing with or without CML's is considered to be a victim of child abuse and neglect. Typically several metabolic bone diseases are ruled out with observing normal biochemistries associated with bone metabolism including calcium, phosphorus and alkaline phosphatase. The genetic

abnormality most associated as a major cause for these fractures is OI resulting in genetic screening for a causative variant in the COL1A1 and COL1A2 genes. If this genetic test is negative the parents are accused of abusing their child and the child and often all of the children are removed from their care and, if fortunate enough, given to a family member or worse case scenario given to foster care often resulting in the infant and other children being placed for adoption.

We report 72 cases of infants with multiple fractures diagnosed as caused by non-accidental trauma and who have at least one documented metabolic bone disease EDS, OI/EDS syndrome or vitamin D deficiency/rickets. These metabolic bone diseases are well documented in the literature to independently be associated with fragility fractures as well as CML's which is sometimes the only radiologic defect observed on a skeletal survey but considered by many pediatric radiologists and child abuse experts as can only be caused by non-accidental trauma. Therefore it would not at all be unexpected that for an infant to have both metabolic bone disorders that the infant would be at additional risk for fragility fractures.

An infant(s) presenting with multiple fractures suspected to be caused by non-accidental trauma should be evaluated for EDS along with other metabolic disorders that cause bone fragility. (Table 5) A family history should be obtained and an evaluation of parents and family members should be evaluated for EDS. Since EDS is an autosomal dominant disorder the infant has a 50% chance of also acquiring it. The parents should be medically evaluated and a Beighton score should be

performed along with taking careful clinical history for evidence of gastroparesis, mast cell hypersensitivity, capillary fragility with easy bruisability, poor wound healing, joint laxity, orthostatic hypotension, and postural orthostatic tachycardia syndrome that are among the many clinical signs for this, genetic disorder.^{14,15,33,36} A strong family history of fragility fractures in parents and family members with minimum trauma as children and adults is also helpful in confirming the diagnosis of skeletal fragility.

Biochemical studies on collagen molecules are possible with cultured skin fibroblasts to confirm some types of EDS.^{68,69} Genetic screening in children diagnosed with multiple fractures due to non-accidental trauma typically only screen for OI. For example, one of our cases was initially evaluated for a causative variant in the COL5A1, COL5A2, FKBP14, and TNXB genes, which were negative, but she was found later to have a causative variant in SEPRINF1 gene. A causative variation in the serpin peptidase inhibitor, clade F, member 1 (SERPINF1) gene has been associated with OI/EDS overlap syndrome and the mutation in this gene causes type VI OI.⁷⁰ Moreover, Electron Microscopy of a skin biopsy in a child suspected of being abused who either has clinical evidence of EDS or a parent with EDS may be worthwhile obtaining to evaluate for classic histologic evidence for disturbed collagen fibrillogenesis. A "cauliflower" deformity of collagen fibrils is characteristic.⁷¹ The dermatopathology analysis of the skin biopsy of one infant and his mother in this case series were reported to be consistent with osteogenesis imperfect (OI) and hypermobile EDS from a morphological standpoint respectively.

Table 5. Recommendations that should be considered when evaluating a child who presents with multiple fractures suspected to be caused by non-accidental trauma.

1. A medical history should be obtained on the infant for signs of gastroparesis often diagnosed as GERD, mast cell hypersensitivity i.e., unprovoked flushing or hives often misdiagnosed as allergies or in some cases leaves fingerprint marks or red marks on the skin areas that had pressured put on it that can be misdiagnosed as excessive force applied to the infant and bruising caused by capillary fragility. These infants are usually able to maneuver their thoracic spine, legs, arms, feet and shoulders in unusual positions and able to get out of restraints including swaddling with ease. Joint laxity is often detected by a history of popping and clicking of the joints.^{15, 36}
2. Evaluation of the mother to determine if and how much calcium and vitamin D was taken during pregnancy. She should be evaluated with a complete metabolic profile as well as a 25(OH)D and PTH. It should be determined if the infant received as sole source of nutrition human breast milk which contains little if any vitamin D and whether the infant received vitamin D supplementation. Ask if the infant experienced profuse head sweating at night, which can be an early sign of infantile vitamin D deficiency.⁷²
3. Both parents should be evaluated for evidence of EDS by an experienced clinician using the Beighton scoring system as well as evaluating skin texture and sclera for the presence of a bluish hue. A history of fragility fractures, gastroparesis, orthostatic hypotension, easy bruising, poor wound healing, and atrophic scarring help to confirm the diagnosis.^{15, 36}
4. Physical examination of the infant should include evaluating for skin texture including increased elasticity, blue sclerae, hyperextensibility of shoulders, hips, fingers, elbows and knees to a greater degree than a normal infant. Often the infant can demonstrate unprovoked flushing or profuse sweating a sign for mast cell hypersensitivity. During the evaluation dermatographism may also be present.
5. A metabolic bone profile should be obtained on the infant at the time of the evaluation. The profile should contain a serum 25(OH)D, PTH, alkaline phosphatase, calcium, phosphate and albumin. A 1,25(OH)2D can also be helpful because if elevated is diagnostic of vitamin D deficiency and secondary hyperparathyroidism or could be caused by vitamin D resistant rickets.^{26, 71}
6. Genetic screening in children diagnosed with multiple fractures due to non-accidental trauma typically only screen for OI and are negative. Next-generation sequencing panel may be of value in guiding future clinical pathways for genetic diagnosis in EDS75.

Unfortunately, there is no genetic test for most forms of EDS including the hypermobility form, EDS type 3. Thus, a careful medical history for the infant should be undertaken. Although it's not possible to perform a Beighton score on an infant there are many classic symptoms that should be obtained in the interview to help rule in or rule out this diagnosis. Often infants with EDS have a history of being unable to ingest a full meal of breast milk or infant formula; constantly spitting up sometimes with projectile vomiting and often losing weight during their first few weeks of life. This is a classic sign for gastroparesis that is often misdiagnosed as gastrointestinal reflux and even pyloric stenosis. Infants that profusely sweat and develop redness or red blotchiness to their skin is a classic sign for mast cell hypersensitivity. The blotchiness can often be misinterpreted as due to rough handling of the infant and in some cases areas of pressure just holding the infant can result in red impressions of fingerprints suggestive of child abuse. Some infants with EDS have capillary fragility and therefore bruise easily.^{2,8,11}

Parents often inform their pediatrician that they could feel and hear the infant's joints clicking. This is often dismissed by pediatricians as being perfectly normal. However, joint laxity is a common finding in patients with EDS and is a likely cause for the observed joint clicking and popping reported by parents and should be documented. On physical examination hyperextensibility of fingers, shoulders, thoracic spine (parents often note that their infants are able to bend themselves backward into almost a C-like position), hyperextensibility of their ankles, knees and elbows can often be elicited to a much greater degree than what can be accomplished in a normal infant. (Table 5)

A diagnosis of metabolic bone disease, predisposing the child to fracture, does not conclusively rule out the possibility of the fractures caused by non-accidental trauma. However, it does suggest an alternative reason for bone fractures other than CAN, or that fractures occurred at a level of mechanical insult to the child that otherwise might not have qualified as CAN. Sorting through these issues, in light of our current findings, will require additional reflection by both medical and legal scholars, applied on a case-by-case basis, to each clinical scenario.

Therefore, identification of non-accidental injuries is as important as distinguishing them from accidental injuries and injuries caused by normal handling

because of a genetic defect of the collagen elastin matrix of the skin and skeleton. It is vital to verify if a case of multiple fractures is caused either by child abuse or some metabolic bone disease. When evaluating a child presenting with multiple fractures with parents suspected of CAN the steps listed in Table 5 should be considered before this diagnosis is made.

Multiple fractures

Both EDS and vitamin D deficiency rickets have been associated with low bone mass and bone fragility fractures^{7,9,10,12,15,17,28,50,52,58,61,63-67,74} however neither of them independently or in combination is/are typically considered as the cause for unexplained fractures in infancy. Our case series suggests that they should be.

Abbreviations

25(OH)D	25-hydroxyvitamin D
CAN	Child abuse and neglect
EDS	Ehlers-Danlos syndrome/hypermobility
IRB	Institutional Review Board
JHS	Joints Hypermobility Syndrome
OI	osteogenesis imperfect
VDD	Vitamin D Deficiency

Disclosure of potential conflicts of interest

No potential conflicts of interest were disclosed.

Funding

Institutional resources.

ORCID

M. F. Holick  <http://orcid.org/0000-0001-6023-9062>

References

- [1] Sink EL, Hyman JE, Matheny T, Georgopoulos G, Kleinman P. Child abuse: the role of the orthopaedic surgeon in nonaccidental trauma. *Clin Orthop Relat Res* 2011; 469:790-7; PMID:20941649; <https://doi.org/10.1007/s11999-010-1610-3>
- [2] Wardinsky TD. Genetic and congenital defect conditions that mimic child abuse. *J Fam Pract* 1995; 41:377-83; PMID:7561712
- [3] Astley R. Metaphyseal fractures in osteogenesis imperfecta. *Br J Radiol* 1979; 52:441-3; PMID:465918; <https://doi.org/10.1259/0007-1285-52-618-441>
- [4] Singh Kocher M, Dichtel L. Osteogenesis imperfecta misdiagnosed as child abuse. *J Pediatr Orthop B* 2011;

- 20:440-3; PMID:21716141; <https://doi.org/10.1097/BPB.0b013e328347a2e1>
- [5] Pandya NK, Baldwin K, Kamath AF, Wenger DR, Hosalkar HS. Unexplained fractures: child abuse or bone disease? A systematic review. *Clin Orthop Relat Res* 2011; 469:805-12; PMID:20878560; <https://doi.org/10.1007/s11999-010-1578-z>
- [6] Paterson CR, McAllion SJ, Shaw JW. Clinical and radiological features of osteogenesis imperfecta type IVA. *Acta Paediatr Scand* 1987; 76:548-52; PMID:3630672; <https://doi.org/10.1111/j.1651-2227.1987.tb10519.x>
- [7] Ayoub DM, Hyman C, Cohen M, Miller M. A critical review of the classic metaphyseal lesion: traumatic or metabolic? *AJR Am J Roentgenol* 2014; 202:185-96; PMID:24370143; <https://doi.org/10.2214/AJR.13.10540>
- [8] Owen SM, Durst RD. Ehlers-Danlos syndrome simulating child abuse. *Arch Dermatol* 1984; 120:97-101; PMID:6691721; <https://doi.org/10.1001/archderm.1984.01650370103020>
- [9] Roberts DL, Pope FM, Nicholls AC, Narcisi P. Ehlers-Danlos syndrome type IV mimicking non-accidental injury in a child. *Br J Dermatol* 1984; 111:341-5; PMID:6477831; <https://doi.org/10.1111/j.1365-2133.1984.tb04733.x>
- [10] Keller KA, Barnes PD. Rickets vs. abuse: a national and international epidemic. *Pediatr Radiol* 2008; 38:1210-6
- [11] Abtahi-Naeini B, Shapouri J, Masjedi M, Saffaei A, Pourazizi M. Unexplained facial scar: child abuse or ehlers-danlos syndrome? *N Am J Med Sci* 2014; 6:595-8; PMID:25535610; <https://doi.org/10.4103/1947-2714.145482>
- [12] Paterson CR. Vitamin D deficiency rickets and allegations of non-accidental injury. *Acta Paediatr* 2009; 98:2008-12; PMID:19572990; <https://doi.org/10.1111/j.1651-2227.2009.01407.x>
- [13] Cannell JJ, Holick MF. Multiple unexplained fractures in infants and child physical abuse. *J Steroid Biochem Mol Biol* 2016; In press; PMID:27641737
- [14] De Paepe A, Malfait F. The Ehlers-Danlos syndrome, a disorder with many faces. *Clin Genet* 2012; 82:1-11; PMID:22353005; <https://doi.org/10.1111/j.1399-0004.2012.01858.x>
- [15] Yen JL, Lin SP, Chen MR, Niu DM. Clinical features of Ehlers-Danlos syndrome. *J Formos Med Assoc* 2006; 105:475-80; PMID:16801035; [https://doi.org/10.1016/S0929-6646\(09\)60187-X](https://doi.org/10.1016/S0929-6646(09)60187-X)
- [16] Eller-Vainicher C, Bassotti A, Imeraj A, Cairoli E, Ulivieri FM, Cortini F, Dubini M, Marinelli B, Spada A, Chiodini I. Bone involvement in adult patients affected with Ehlers-Danlos syndrome. *Osteoporos Int* 2016; 27:2525-31; PMID:27084695; <https://doi.org/10.1007/s00198-016-3562-2>
- [17] Grahame R, Edwards JC, Pitcher D, Gabell A, Harvey W. A clinical and echocardiographic study of patients with the hypermobility syndrome. *Ann Rheum Dis* 1981; 40:541-6; PMID:7332373; <https://doi.org/10.1136/ard.40.6.541>
- [18] Mazziotti G, Dordoni C, Doga M, Galderisi F, Venturini M, Calzavara-Pinton P, Maroldi R, Giustina A, Colombi M. High prevalence of radiological vertebral fractures in adult patients with Ehlers-Danlos syndrome. *Bone* 2016; 84:88-92; PMID:26708925; <https://doi.org/10.1016/j.bone.2015.12.007>
- [19] Stern CM, Pepin MJ, Stoler JM, Kramer DE, Spencer SA, Stein CJ. Musculoskeletal Conditions in a Pediatric Population with Ehlers-Danlos Syndrome. *J Pediatr* 2017; 181:261-6
- [20] Solomons J, Coucke P, Symoens S, Cohen MC, Pope FM, Wagner BE, Sobey G, Black R, Cilliers D. Dermatosparaxis (Ehlers-Danlos type VIIC): prenatal diagnosis following a previous pregnancy with unexpected skull fractures at delivery. *Am J Med Genet A* 2013; 161A:1122-5; PMID:23495203; <https://doi.org/10.1002/ajmg.a.35802>
- [21] Castori M. Ehlers-Danlos syndrome(s) mimicking child abuse: Is there an impact on clinical practice? *Am J Med Genet C Semin Med Genet* 2015; 169:289-92; PMID:26452443; <https://doi.org/10.1002/ajmg.c.31460>
- [22] Barlow T, Bury JS. Constitutional diseases, and diseases of nutrition. In: Keating JM, editors. *Cyclopaedia of the diseases of children, medical and surgical*. Philadelphia (PA): J. B. Lippincott Company; 1889
- [23] Eliot MM, Park EA. Rickets. In: Mcquarrie I, editors. *Brennemann's practice of pediatrics*. Hagerstown (MD): W. F. Prior company, Inc; 1939
- [24] Hess AF. Rickets, osteomalacia, and tetany. Philadelphia (PA): Lea & Febiger; 1929
- [25] Holick MF. Resurrection of vitamin D deficiency and rickets. *J Clin Invest* 2006; 116:2062-72; PMID:16886050; <https://doi.org/10.1172/JCI29449>
- [26] Holick MF. Vitamin D deficiency. *N Engl J Med* 2007; 357:266-81; PMID:17634462; <https://doi.org/10.1056/NEJMra070553>
- [27] Shore RM, Chesney RW. Rickets: Part I. *Pediatr Radiol* 2013; 43:140-51; PMID:23208530; <https://doi.org/10.1007/s00247-012-2532-x>
- [28] Chesney RW. Rickets or abuse, or both? *Pediatr Radiol* 2008; 38:1217-8; PMID:18810405; <https://doi.org/10.1007/s00247-008-0993-8>
- [29] Caffey J. Multiple fractures in the long bones of infants suffering from chronic subdural hematoma. *Am J Roentgenol Radium Ther* 1946; 56:163-73; PMID:20995763
- [30] Kemp AM, Dunstan F, Harrison S, Morris S, Mann M, Rolfe K, Datta S, Thomas DP, Sibert JR, Maguire S. Patterns of skeletal fractures in child abuse: systematic review. *BMJ* 2008; 337:a1518; PMID:18832412; <https://doi.org/10.1136/bmj.a1518>
- [31] Kleinman PK, Marks SC, Blackburne B. The metaphyseal lesion in abused infants: a radiologic-histopathologic study. *AJR Am J Roentgenol* 1986; 146:895-905; PMID:3485907; <https://doi.org/10.2214/ajr.146.5.895>
- [32] Dwek JR. The radiographic approach to child abuse. *Clin Orthop Relat Res* 2011; 469:776-89; PMID:20544318; <https://doi.org/10.1007/s11999-010-1414-5>
- [33] Callewaert B, Malfait F, Loeys B, De Paepe A. Ehlers-Danlos syndromes and Marfan syndrome. *Best Pract Res Clin Rheumatol* 2008; 22:165-89; PMID:18328988; <https://doi.org/10.1016/j.berh.2007.12.005>

- [34] Bodnar LM, Simhan HN, Powers RW, Frank MP, Cooperstein E, Roberts JM. High prevalence of vitamin D insufficiency in black and white pregnant women residing in the northern United States and their neonates. *J Nutr* 2007; 137:447-52; PMID:17237325
- [35] Lee JM, Smith JR, Philipp BL, Chen TC, Mathieu J, Holick MF. Vitamin D deficiency in a healthy group of mothers and newborn infants. *Clin Pediatr (Phila)* 2007; 46:42-4; PMID:17164508; <https://doi.org/10.1177/0009922806289311>
- [36] Gazit Y, Jacob G, Grahame R. Ehlers-Danlos Syndrome-Hypermobility Type: A Much Neglected Multi-systemic Disorder. *Rambam Maimonides Med J* 2016; 7(4):e0034
- [37] Beighton P, Horan F. Orthopaedic aspects of the Ehlers-Danlos syndrome. *J Bone Joint Surg Br* 1969; 51:444-53; PMID:5820785
- [38] Holick MF, Binkley NC, Bischoff-Ferrari HA, Gordon CM, Hanley DA, Heaney RP, Murad MH, Weaver CM, Endocrine S. Evaluation, treatment, and prevention of vitamin D deficiency: an Endocrine Society clinical practice guideline. *J Clin Endocrinol Metab* 2011; 96:1911-30; PMID:21646368; <https://doi.org/10.1210/jc.2011-0385>
- [39] Sobey G. Ehlers-Danlos syndrome: how to diagnose and when to perform genetic tests. *Arch Dis Child* 2015; 100:57-61; PMID:24994860; <https://doi.org/10.1136/archdischild-2013-304822>
- [40] Corvol MT, Dumontier MF, Garabedian M, Rappaport R. Vitamin D and Cartilage. II. Biological Activity of 25-Hydroxycholecalciferol and 24,25- and 1,25-Dihydroxycholecalciferols on Cultured Growth Plate Chondrocytes. *Endocrinology* 1978; 102:1269-74; <https://doi.org/10.1210/endo-102-4-1269>
- [41] Holick MF. The vitamin D epidemic and its health consequences. *J Nutr* 2005; 135:2739S-48S; PMID:16251641
- [42] Greenberg MI. Greenberg's Text-atlas of Emergency Medicine. Philadelphia (PA): Lippincott Williams & Wilkins; 2005
- [43] Kleinman PK. Diagnostic imaging in infant abuse. *AJR Am J Roentgenol* 1990; 155:703-12; PMID:2119097; <https://doi.org/10.2214/ajr.155.4.2119097>
- [44] Kleinman PK, Blackbourne BD, Marks SC, Karellas A, Belanger PL. Radiologic contributions to the investigation and prosecution of cases of fatal infant abuse. *N Engl J Med* 1989; 320:507-11; PMID:2915652; <https://doi.org/10.1056/NEJM198902233200807>
- [45] Kleinman PK, Nimkin K, Spevak MR, Rayder SM, Madansky DL, Shelton YA, Patterson MM. Follow-up skeletal surveys in suspected child abuse. *AJR Am J Roentgenol* 1996; 167:893-6; PMID:8819377; <https://doi.org/10.2214/ajr.167.4.8819377>
- [46] Rustamzadeh E, Truwit CL, Lam CH. Radiology of non-accidental trauma. *Neurosurg Clin N Am* 2002; 13:183-99; PMID:12391703; [https://doi.org/10.1016/S1042-3680\(01\)00004-3](https://doi.org/10.1016/S1042-3680(01)00004-3)
- [47] Shore RM, Chesney RW. Rickets: Part II. *Pediatr Radiol* 2013; 43:152-72; PMID:23179485; <https://doi.org/10.1007/s00247-012-2536-6>
- [48] Caffey J. Some traumatic lesions in growing bones other than fractures and dislocations: clinical and radiological features: the mackenzie davidson memorial lecture. *Br J Radiol* 1957; 30:225-38; PMID:13426502; <https://doi.org/10.1259/0007-1285-30-353-225>
- [49] Perez-Rossello JM, McDonald AG, Rosenberg AE, Tsai A, Kleinman PK. Absence of rickets in infants with fatal abusive head trauma and classic metaphyseal lesions. *Radiology* 2015; 275:810-21; PMID:25688889; <https://doi.org/10.1148/radiol.15141784>
- [50] Perez-Rossello JM, Feldman HA, Kleinman PK, Connolly SA, Fair RA, Myers RM, Gordon CM. Rachitic changes, demineralization, and fracture risk in healthy infants and toddlers with vitamin D deficiency. *Radiology* 2012; 262:234-41; PMID:22106354; <https://doi.org/10.1148/radiol.11110358>
- [51] Feldman KW, Done S. Vitamin D deficiency rickets and allegations of non-accidental injury. *Acta Paediatr* 2010; 99:486-7; PMID:20353519; <https://doi.org/10.1111/j.1651-2227.2010.01751.x>
- [52] Ayoub D, Plunkett J, Keller KA, Barnes PD. Are Pater-son's critics too biased to recognize rickets? *Acta Paediatr* 2010; 99:1282-3; PMID:20939834; <https://doi.org/10.1111/j.1651-2227.2010.01927.x>
- [53] Feldman K. Commentary on "congenital rickets" article. *Pediatr Radiol* 2009; 39:1127-9; PMID:19415253; <https://doi.org/10.1007/s00247-009-1285-7>
- [54] Slovis TL, Chapman S. Evaluating the data concerning vitamin D insufficiency/deficiency and child abuse. *Pediatr Radiol* 2008; 38:1221-4; PMID:18810404; <https://doi.org/10.1007/s00247-008-0994-7>
- [55] Strouse PJ. Vitamin D deficiency vs. child abuse: what do we know now and where do we go? *Pediatr Radiol* 2009; 39:1033; PMID:19727700; <https://doi.org/10.1007/s00247-009-1377-4>
- [56] Contreras JJ, Hiestand B, O'Neill JC, Schwartz R, Nadkarni M. Vitamin D deficiency in children with fractures. *Pediatr Emerg Care* 2014; 30:777-81; PMID:25343741; <https://doi.org/10.1097/PEC.0000000000000258>
- [57] El-Sakka A, Penon C, Hegazy A, Elbatrawy S, Gobashy A, Moreira A. Evaluating Bone Health in Egyptian Children with Forearm Fractures: A Case Control Study. *Int J Pediatr* 2016; 2016:7297092; PMID:27651803; <https://doi.org/10.1155/2016/7297092>
- [58] Chapman T, Sugar N, Done S, Marasigan J, Wambold N, Feldman K. Fractures in infants and toddlers with rickets. *Pediatr Radiol* 2010; 40:1184-9; PMID:20012034; <https://doi.org/10.1007/s00247-009-1470-8>
- [59] Schilling S, Wood JN, Levine MA, Langdon D, Christian CW. Vitamin D status in abused and nonabused children younger than 2 years old with fractures. *Pediatrics* 2011; 127:835-41; PMID:21482609; <https://doi.org/10.1542/peds.2010-0533>
- [60] Hirata K, Triposkiadis F, Sparks E, Bowen J, Wooley CF, Boudoulas H. The Marfan syndrome: abnormal aortic elastic properties. *J Am Coll Cardiol* 1991; 18:57-63; PMID:2050942; [https://doi.org/10.1016/S0735-1097\(10\)80218-9](https://doi.org/10.1016/S0735-1097(10)80218-9)

- [61] Plotkin H. Syndromes with congenital brittle bones. *BMC Pediatr* 2004; 4:16; PMID:15339338; <https://doi.org/10.1186/1471-2431-4-16>
- [62] Gazit Y, Nahir AM, Grahame R, Jacob G. Dysautonomia in the joint hypermobility syndrome. *Am J Med* 2003; 115:33-40; PMID:12867232; [https://doi.org/10.1016/S0002-9343\(03\)00235-3](https://doi.org/10.1016/S0002-9343(03)00235-3)
- [63] Yeowell HN, Steinmann B. Ehlers-Danlos Syndrome, Kyphoscoliotic Form. In: Pagon RA, Adam MP, Ardinger HH, Wallace SE, Amemiya A, Bean LJH, Bird TD, Fong CT, Mefford HC, Smith RJH, et al., editors. *GeneReviews*(R). Seattle (WA): University of Washington, Seattle; 1993
- [64] Carbone L, Tylavsky FA, Bush AJ, Koo W, Orwoll E, Cheng S. Bone density in Ehlers-Danlos syndrome. *Osteoporos Int* 2000; 11:388-92; PMID:10912839; <https://doi.org/10.1007/s001980070104>
- [65] Dolan AL, Arden NK, Grahame R, Spector TD. Assessment of bone in Ehlers Danlos syndrome by ultrasound and densitometry. *Ann Rheum Dis* 1998; 57:630-3; PMID:9893576; <https://doi.org/10.1136/ard.57.10.630>
- [66] Theodorou SJ, Theodorou DJ, Kakitsubata Y, Adams JE. Low bone mass in Ehlers-Danlos syndrome. *Intern Med* 2012; 51:3225-6; PMID:23154741; <https://doi.org/10.2169/internalmedicine.51.7778>
- [67] Paterson CR, Mole PA. Joint laxity in the parents of children with temporary brittle bone disease. *Rheumatol Int* 2012; 32:2843-6; PMID:21881991; <https://doi.org/10.1007/s00296-011-2073-x>
- [68] Mayer K, Kennerknecht I, Steinmann B. Clinical utility gene card for: Ehlers-Danlos syndrome types I-VII and variants - update 2012. *Eur J Hum Genet* 2013; 21(1):162; PMID:22669413
- [69] Pepin M, Schwarze U, Superti-Furga A, Byers PH. Clinical and genetic features of Ehlers-Danlos syndrome type IV, the vascular type. *N Engl J Med* 2000; 342:673-80; PMID:10706896; <https://doi.org/10.1056/NEJM200003093421001>
- [70] Homan EP, Rauch F, Grafe I, Lietman C, Doll JA, Dawson B, Bertin T, Napierala D, Morello R, Gibbs R, et al. Mutations in SERPINF1 cause osteogenesis imperfecta type VI. *J Bone Miner Res* 2011; 26:2798-803; PMID:21826736; <https://doi.org/10.1002/jbmr.487>
- [71] Hausser I, Anton-Lamprecht I. Differential ultrastructural aberrations of collagen fibrils in Ehlers-Danlos syndrome types I-IV as a means of diagnostics and classification. *Hum Genet* 1994; 93:394-407; PMID:8168810; <https://doi.org/10.1007/BF00201664>
- [72] Holick MF. Osteomalacia and rickets In: Marc C., Hochberg AJS, Josef S. Smolen, Michael E. Weinblatt, Michael H. Weisman, editors. *Rheumatology*. Philadelphia, PA: Mosby Ltd; 2014:1680-7
- [73] Holick MF, Lim R, Dighe AS. Case records of the Massachusetts General Hospital. Case 3-2009. A 9-month-old boy with seizures. *N Engl J Med* 2009; 360:398-407; PMID:19164191; <https://doi.org/10.1056/NEJMcp0807821>
- [74] Gordon CM, Feldman HA, Sinclair L, Williams AL, Kleinman PK, Perez-Rossello J, Cox JE. Prevalence of vitamin D deficiency among healthy infants and toddlers. *Arch Pediatr Adolesc Med* 2008; 162:505-12; PMID:18524739; <https://doi.org/10.1001/archpedi.162.6.505>
- [75] Weerakkody RA, Vandrovcova J, Kanonidou C, Mueller M, Gampawar P, Ibrahim Y, Norsworthy P, Biggs J, Abdullah A, Ross D, et al. Targeted next-generation sequencing makes new molecular diagnoses and expands genotype-phenotype relationship in Ehlers-Danlos syndrome. *Genet Med* 2016; 18(11):1119-1127; PMID:27011056