



Daily oral vitamin D3 without concomitant therapy in the management of psoriasis: A case series

Renu Mahtani^a, Pradeep M.K. Nair^{b,*}

^a Dr. Renu Mahtani's Param Health - Autoimmunity Treatment Centre, Pune, India

^b Sant Hirdaram Medical College of Naturopathy & Yogic Sciences, Sant Hirdaram Nagar, Bhopal 462020, India



ARTICLE INFO

Keywords:

Vitamin D3
Psoriasis
Vitamin D resistance
Autoimmune disorders
Skin disorders
Case report

ABSTRACT

Evidence suggests vitamin D3 resistance with gene polymorphisms related to its metabolism to have a potential role in the patho-prognosis of psoriasis. We report 6 cases of psoriasis treated with daily oral Vitamin D3 (25 hydroxy cholecalciferol) in doses ranging from 30,000 IU to 60,000 IU over a period of 2 to 6 months and then followed by lower daily maintenance dose. The dose of vitamin D3 was adjusted based on the drop in the level of parathyroid hormone as the ionized calcium levels were also periodically monitored to prevent hypercalcemia. Complete control of psoriasis was observed within a span of 2–6 months, which was measured by Psoriasis Area and Severity Index (PASI) and a symptom Visual analog scale. Our observations suggest that supervised, daily oral higher than usual Vitamin D3 can be given safely as an effective therapeutic modality for treating psoriasis.

Introduction

Recent understanding of psoriasis from a mere skin disease to a systemic disease has paved way to exploring the role of new targeted therapies for psoriasis [1]. Population based surveys reports about the insufficiency of the current therapies, severe impairments in the quality of life and increased stigmatism about psoriasis in the society as a substantial burden in the management of psoriasis [2]. The global burden of psoriasis is up to 11.4% and varies from country to country [3]. The circulating levels of D3 have been found to share an inverse relationship with the progression of autoimmune disorders [4]. Reports have suggested a potential role of vitamin D deficiency in the pathophysiology of psoriasis. The active form of vitamin D and its receptors are responsible for the upregulation of keratinocytes [5,6]. Many studies have demonstrated the impact of vitamin D on the proliferation and differentiation of the keratinocytes, a rate limiting factor which balances the cutaneous immune system and apoptosis. A lower level of vitamin D concentration promotes proliferation and a higher concentration of the same inhibits the same [5,7,8]. Further, the genetic polymorphisms of the vitamin D receptors have been found to induce a high level of vitamin D resistance in autoimmune diseases warranting higher doses of vitamin D to combat this resistance and achieve meaningful clinical effects [9,10]. Studies suggest that Vitamin D3 concentrations in serum lower than 300 ng/mL do not induce any toxicity [11].

Monitoring parathyroid hormone levels in the serum can be used as the best biological indicator to estimate the optimal therapeutic doses

of vitamin D3 in treating psoriasis [10]. Low Vitamin D levels result in an elevated level of parathyroid hormone (PTH) due to the direct feedback mechanism it shares with Vitamin D system. With Vitamin D3 therapy, the PTH levels are expected to come down. However, due to the Vitamin D resistance at the VDR (Vitamin D receptors) found in those with autoimmune disorders, the drop in PTH could be suboptimal, warranting an increase in the dose of vitamin D to combat this resistance and better biological actions [10,12].

Optimal doses of Vitamin D enhances both the natural and adaptive immunity, which makes this practice effective and worth considering over the present day management of psoriasis with immunosuppressive drugs [10,12]. However, limited clinical studies are available on the use of daily oral Vitamin D3 in higher doses in the management of psoriasis. Here we report the case of 6 patients diagnosed as psoriasis of varying duration treated with daily oral Vitamin D3.

Case presentation

All the six patients started the supervised oral vitamin D3 daily therapy between January to April 2020 and are being followed till date. They were under standard conventional therapy for an extended period of time and had discontinued it due to non-responsiveness, side effects and recurrence. After the initial assessment, they signed a written consent to take supervised Vitamin D3 orally on a daily basis. Those with severe vitamin D deficiency (2 patients) were given a onetime loading dose of 600,000 IU vitamin D. Further, these patients were put on a daily dose of 30,000 IU Vitamin D3 (Cholecalciferol) similar to the other four

* Corresponding author.

E-mail address: drpradeep18bnys@gmail.com (P.M.K. Nair).

<https://doi.org/10.1016/j.clicom.2022.01.001>

Received 5 October 2021; Received in revised form 2 January 2022; Accepted 3 January 2022

2772-6134/© 2022 The Authors. Published by Elsevier Inc. This is an open access article under the CC BY-NC-ND license

(<http://creativecommons.org/licenses/by-nc-nd/4.0/>)

Table 1
Baseline summary of the patients treated with high dose vitamin D3.

Patient	Sex	Age in years	Type of Psoriasis	Duration of Psoriasis (Years)	Duration of severity(Years)	Baseline VAS Score	Baseline PASI
1	Female	58	Psoriasis Vulgaris	30	6	7	25.5
2	Female	63	Palmo-plantar	4	1	8	16
3	Female	55	Psoriasis Vulgaris	12	2	9	44.2
4	Male	37	Psoriasis Vulgaris	8	3	9	54
5	Female	48	Palmo plantar	2	1.5	8	22.8
6	Female	55	Palmo-plantar	8	3	8	16

VAS- Visual Analog Scale; PASI- Psoriasis Area and Severity Index.

patients who did not need the loading dose as their baseline vitamin D levels were optimal.

The dose of vitamin D3 was modified based on the degree of drop in parathyroid hormone levels that was checked periodically once in 2 months till significant clinical benefit was observed. The ionized calcium levels were monitored simultaneously to prevent hypercalcemia. The response time varied from patient to patient, ranging from 3 to 6 months. The daily vitamin D3 dose was then reduced to a maintenance dose established for each patient. While under high dose Vitamin D3 therapy, no other concomitant therapies were prescribed by the investigators. The prognosis of the therapy was evaluated through Psoriasis Area and Severity Index (PASI) score, where the average redness, thickness, and scaliness of the lesions scored in a scale of 0–4 is weighed by the body area involved [13]. Further the subjective improvement in itching was assessed through a Visual Analog Scale (VAS), where the value 0 signifies no itching and 10 represents severe itching [14]. All the measurements were collected at the baseline, at the end of 3, 6 and 12 months. Baseline summary of the patients treated are depicted in Table 1. The photographs of pre and post changes are shown in Figs. 1, 2 and 3.

Case 1

A 58 year old woman with psoriasis for 30 years, severe from 6 years, presented with intense itching, and erythematous scaly plaques all over the body. Her baseline Vitamin D level was very low at 11 ng/ml with a PTH value of 65 pg/ml. After the loading dose of 600,000 IU of vitamin D3 she was put on 30,000 IU of Vitamin D3 daily for 2 months. The PTH levels reduced to 37.5 pg/ml indicating vitamin D3 response and significant clinical improvement was also noticed. Therefore, the vitamin D3 dose was reduced to 25,000 IU per day. The ionized calcium was 4.26 mg/dL indicating normocalcemia. By three months, the patient presented with complete control of the disease (PASI= 0.4) with no itching (VAS=0). The before and after changes of vitamin D3 therapy are presented in Fig. 1-panel (a). No recurrence was reported during the period of follow-up and the patient is currently on a maintenance dose of 20,000 IU per day with PTH and ionized Calcium levels well in range.

Case 2

A 63-year-old woman with history of psoriasis for 4 years presented with itching and thick scaly eruptions largely involving the palms and plantar region. The Vitamin D level at the onset was 45 ng/ml and PTH level was 37.5 pg/mL. She was treated with Vitamin D3 doses of 30,000 IU daily for a period of 3 months. Her PTH level came down to 21.2 pg/ml whereas the ionized calcium remained within normal range (1.25 mg/dl). She showed complete control of disease by the end of the 3rd month with an improvement of PASI score (0) and VAS score (0). The before and after changes of vitamin D3 therapy are presented in Fig. 1-panel (b). Since the 4th month she is on a maintenance dose of 20,000 IU daily and no relapse of symptoms were reported at the end of the one year follow-up.

Case 3

A 55 year old woman with history of psoriasis for 12 years localized in the face, reported exacerbation since 2 years, with whole body involvement, severe eruptions and erythematous scaly plaques. Laboratory investigations revealed very low vitamin D levels as 9.44 ng/ml and PTH levels was 52.2 pg/mL. Her PASI scores (44.2) indicated severe psoriasis along with extreme itching (VAS=9). Owing to the severe vitamin D deficiency, she was given a single dose of 600,000 IU of Vitamin D3 followed by 30,000 IU daily. After 2 months, the PTH was recorded as 35.38 pg/mL and ionized calcium levels were 1.20 mg/dL. As there was no improvement and the PTH levels were still not at the lowest, the dose of Vitamin D3 was escalated to 45,000 IU from the third month. The patient continued the therapy under monitoring, until complete control (PASI=0.8; VAS=1) was achieved by the end of 6th month (PTH 29.6 and Ionised Calcium 1.2). The before and after changes of vitamin D3 therapy are presented in Fig. 2-panel (c). The Vitamin D3 dose was then progressively reduced and now the patient is under a maintenance dose of 15,000 IU of Vitamin D3 daily and she continues to be in remission.

Case 4

A 37 year old male with 8 years history of psoriasis, presented with erythematous scaly plaques and pruritis since 3 years. His Vitamin D and PTH levels were 61.5 ng/ml and 24 pg/mL respectively. He was started on the initial daily dose of 30,000 IU for the first 2 months. Considering the clinical improvement and lowering of PTH levels (7.76 pg/ml), the dose of Vitamin D3 was reduced to 20,000 IU daily from the 3rd month onwards. Complete control of the disease was achieved by the end of 4th month (PTH 18.3 pg/ml, ionised calcium 1.16 mg/dL). The before and after changes of vitamin D3 therapy are presented in Fig. 2-panel (d). Presently, the patient is on a maintenance dose of 15,000 IU daily and complete remission with PASI (0) and VAS score (0).

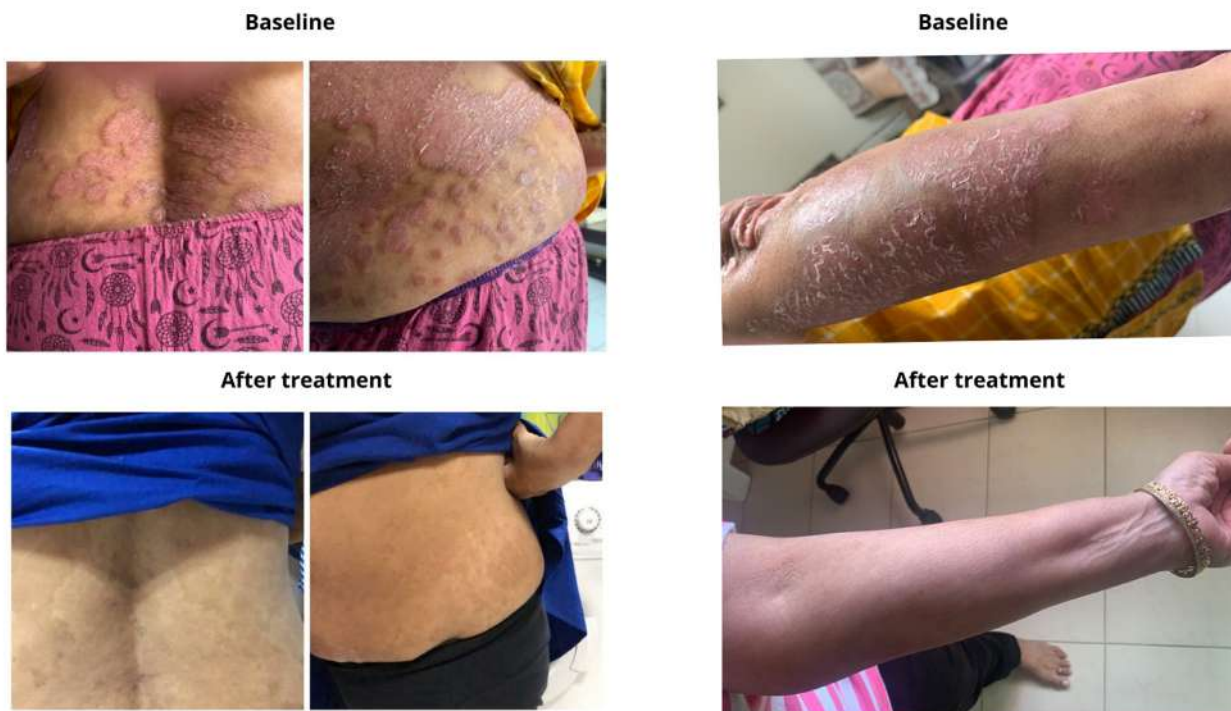
Case 5

A 48-year-old female presented with erythematous and pruritic plaques in the palmar and plantar region for 2 years. Her laboratory reports revealed Vitamin D3 levels of 21.3 ng/ml and high level (113 pg/mL) of PTH. She was started on 30,000 IU of vitamin D3 daily, which was reduced to 15,000 IU daily after 2 months owing to 90 percent subsidence in the progression of disease (PTH 83.3 pg/ml and ionized Calcium 1.33). The dose was further reduced to 10,000 IU daily by the end of 4th month as there was complete remission (PASI=0.4) and the itching was also under control (VAS=1). The before and after changes of vitamin D3 therapy are presented in Fig. 3-panel (e). No further relapse was reported and the patient is under a stable dose of 10,000 IU of Vitamin D3 daily.

Case 6

A 55-year-old female with 8 years history of psoriasis presented with severe itching and erythrodermic lesions involving the palms and plantar region. She presented with vitamin D levels of 39 ng/ml and PTH

(a) Case 1



(b) Case 2

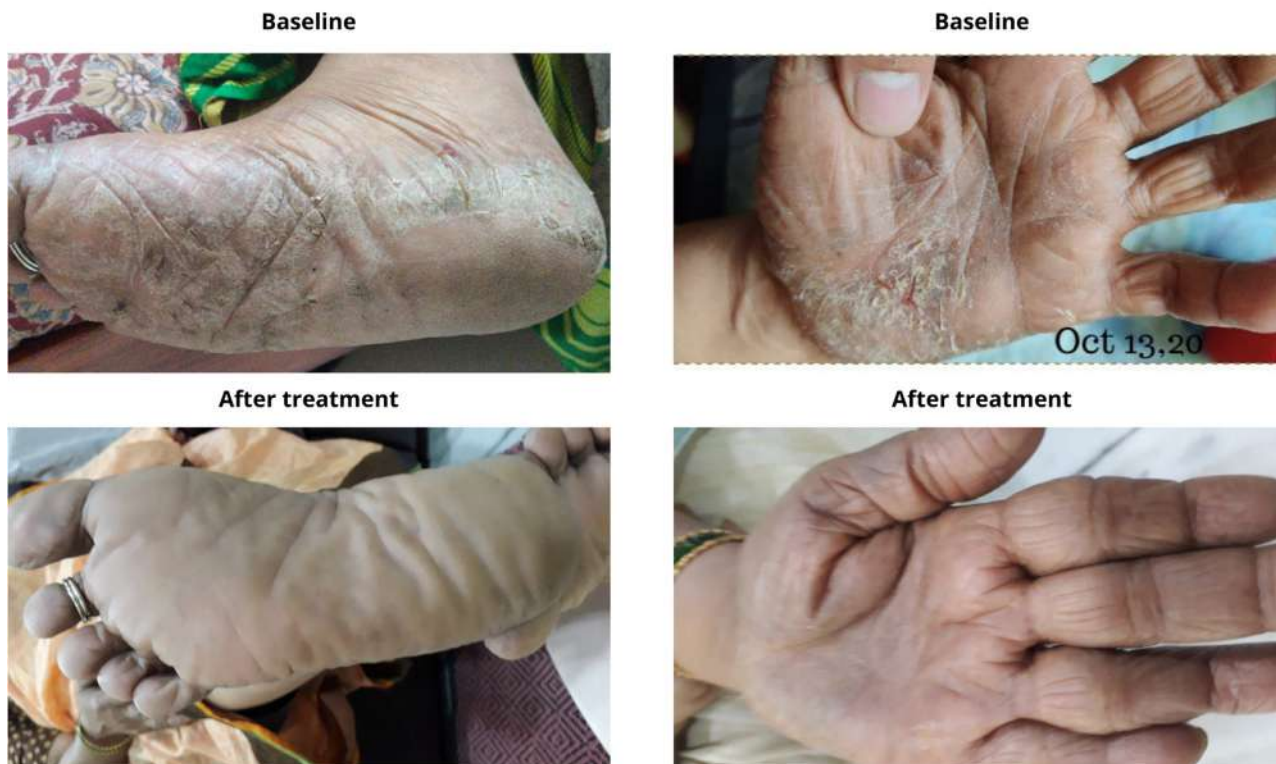
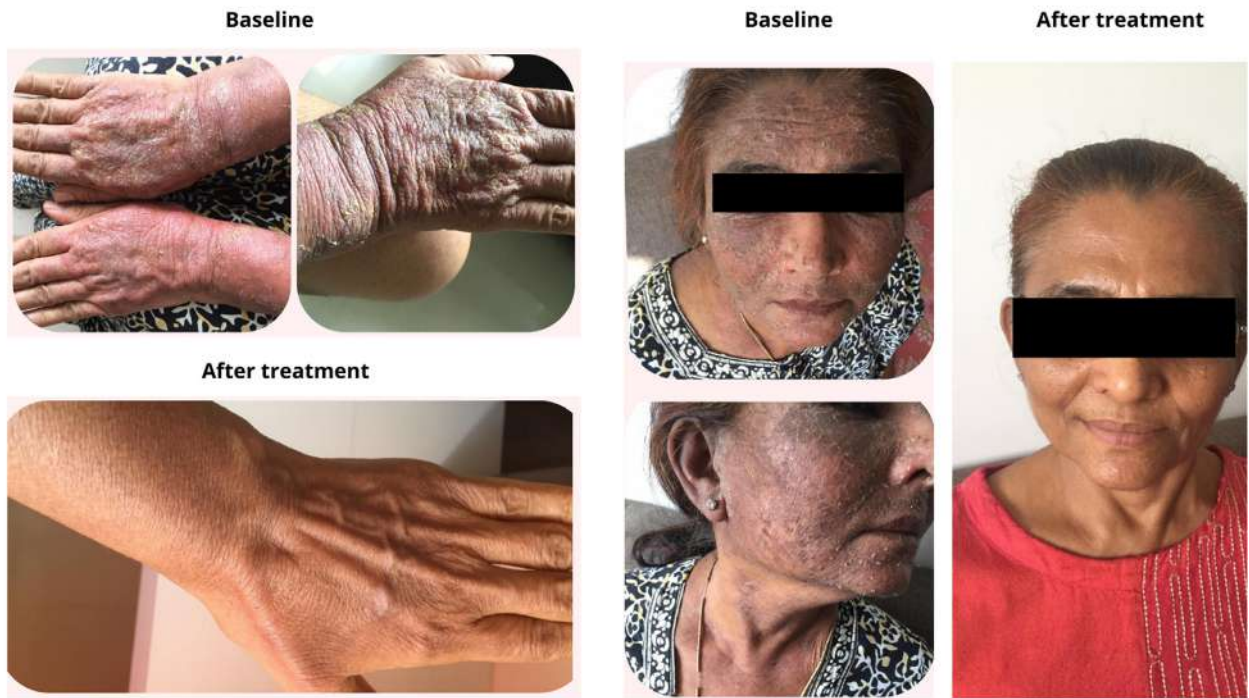
Fig. 1. Baseline through follow-up changes in the psoriatic lesions of cases 1and 2.

(c) Case 3



(d) Case 4

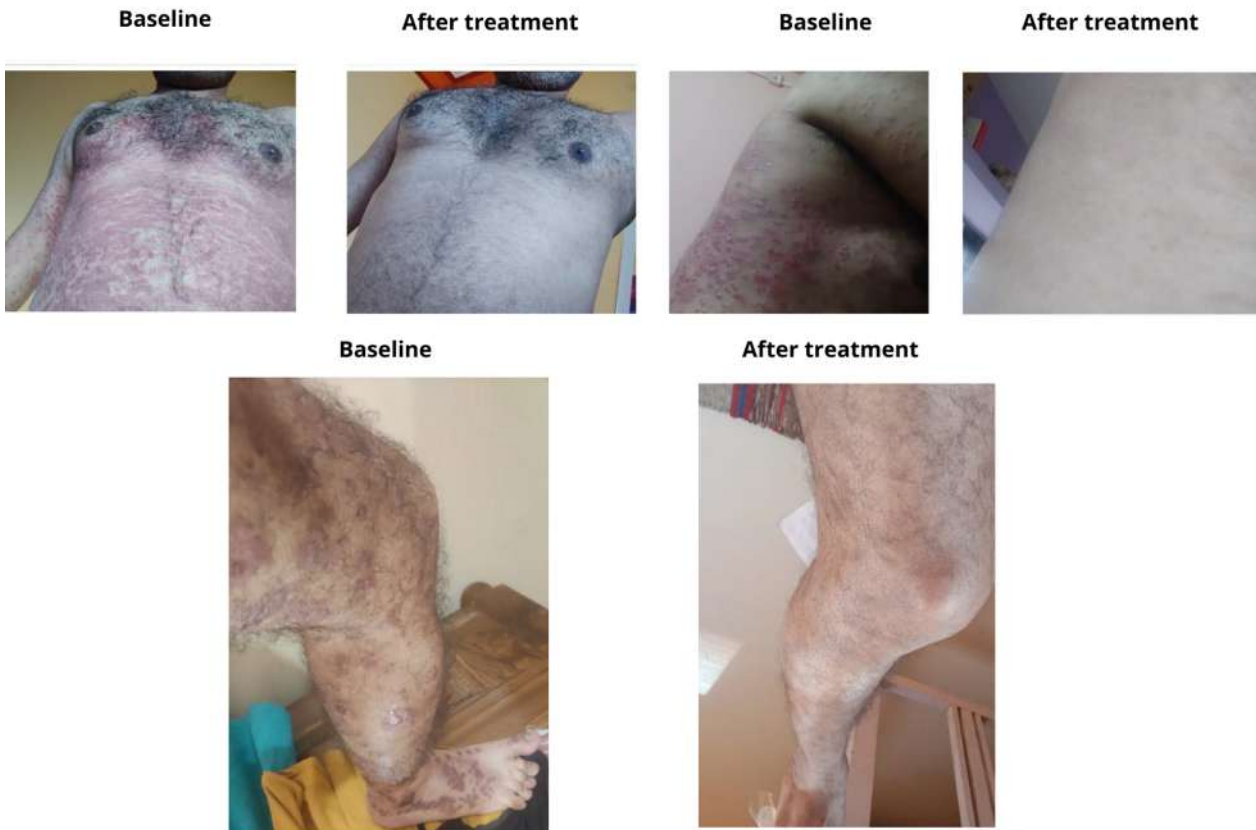

Fig. 2. Baseline through follow-up changes in the psoriatic lesions of cases 3 and 4.

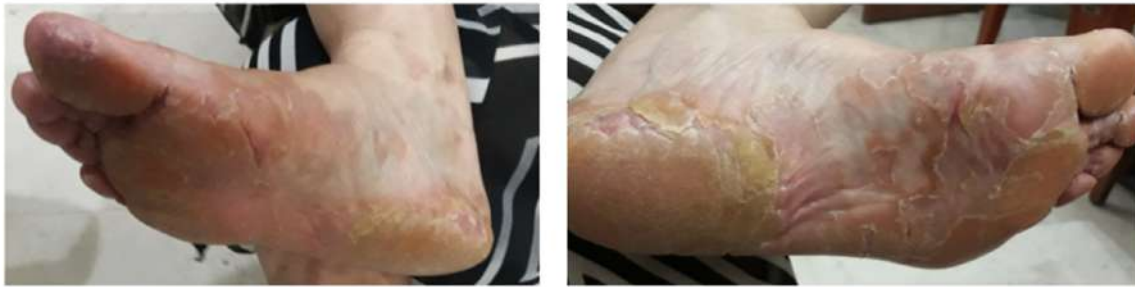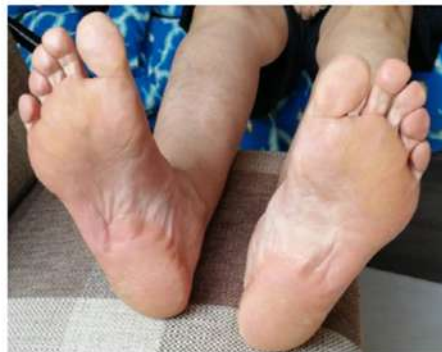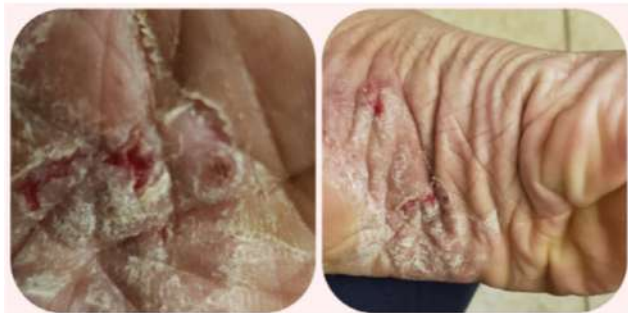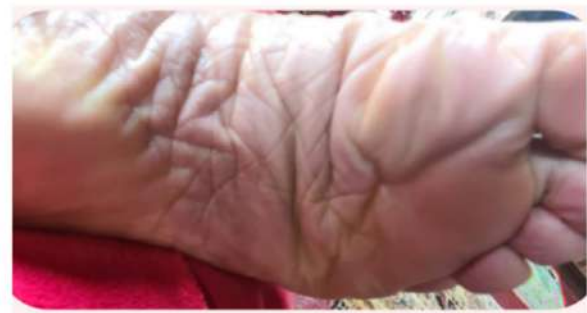(e) Case 5**Baseline****After treatment****(f) Case 6****Baseline****After treatment**

Fig. 3. Baseline through follow-up changes in the psoriatic lesions of cases 5 and 6.

levels at 26 pg/mL. She was put on 30,000 IU vitamin D3 daily, but as her BMI was > 35, the vitamin D3 dose was increased to 40,000 IU within a week. The dose was further increased to 50,000 IU daily after 30 days. PTH values checked after 2 months of therapy, showed a marginal reduction from 26 pg/ml to 22 pg/ml, indicating a high degree of vitamin D resistance. The ionized calcium levels were maintained in the normal range. Therefore, from the third month, the vitamin D dose was further increased to 60,000 IU daily with strict restriction of calcium rich foods. PTH checked after a month of 60,000 IU daily was 19 pg/ml and ionized calcium levels within normal range.

The same dose was continued for another one month owing to a marginal improvement. By then, the PTH had reached its lower limit of normal ranges i.e. 15 pg/ ml. Then, the dose of vitamin D3 was reduced at a rate of 10,000 IU per month i.e. 50,000 IU daily during 5th month and 40,000 IU daily during the 6th month. By the eighth month, the patient achieved a complete control of the disease with PASI and VAS scores as 0.8 and 1 respectively. Similarly laboratory reports revealed a stable PTH level of 24 pg/mL and ionized calcium level of 5 mg/dL.

The patient is currently under a maintenance dose of 40,000 IU daily with no relapse and no hypercalcemia.. The before and after changes of vitamin D3 therapy are presented in Fig. 3-panel (f)

Discussion

Psoriasis is a systemic entity which affects the body and mind in totality. Reports suggest management of psoriasis as challenging, due to multiple issues like relapses, poor adherence, non-responsiveness to standard conventional care. Recent literature warrants introduction of novel therapies that can offer sustainable outcomes, improved patient satisfaction and adherence [15]. The role of vitamin D3 as an immunomodulator, especially in autoimmune disorders has been evidenced in many studies [16]. Further Vitamin D receptor (VDR) is reckoned as a nuclear hormone that has a large role to play in the differentiation as well as proliferation of keratinocytes. A recent study reported the use of VDR in maintaining the homoeostasis of the skin barrier in psoriatic skin [17]. Skin barrier homoeostasis reinstates the expression of tight

junctions (TJ) present in the epithelial and endothelial cells, which are otherwise weakened the psoriasis. This prevents excess inflammatory responses of the skin, which is considered as major step in the pathogenesis of psoriasis [17,18]. This warrants the use of vitamin D3 supplementation in the management of psoriasis.

The observations from this case series demonstrate promising and durable control of the signs and symptoms in psoriasis, with no adverse events or relapse after regular oral supplementation of Vitamin D3. The drop in PTH levels and clinical prognosis were utilized as the guide for deciding the vitamin D dosage. The results inferred in this study concur with the previous study that has reported Vitamin D3 administration at a dose of 35,000 IU/day for 6 months to offer better prognosis in psoriasis [10]. Further, reports suggest high doses of vitamin D up to 50,000 IU daily can be safely used in autoimmune conditions [19]. This has shown to alleviate the individual Vitamin D resistance and induce clinically meaningful results.

This case series reports 100% adherence to Vitamin D3 therapy, as the patients were motivated by the results. This is encouraging as adherence is reckoned as one of the important factors in producing meaningful outcomes [20]. The effect of Vitamin D3 in this case series may be attributed to the immunomodulatory effects of Vitamin D3 on monocytes, macrophages, T cells, and dendritic cells that plays an important role in the pathogenesis of psoriasis [21].

To our knowledge this is the first case report demonstrating the safety and efficacy of daily oral Vitamin D3 in higher doses for treating psoriasis, especially in those patients who show poor response or adherence to conventional therapy. However, this is a case report and the findings have to be carefully evaluated through well-designed large scale randomized control trials with more outcome measures like quality of life, mental health measures and inflammatory marker levels.

Consent to participate

All the participants signed a written consent to express their consent to participate in the study.

Consent to publish

All the participants consented to publish their de-identified data on a medical journal.

Funding

No funds were received for this study.

Declaration of Competing Interest

The authors whose names are listed immediately below certify that they have NO affiliations with or involvement in any organization or en-

tity with any financial interest (such as honoraria; educational grants; participation in speakers' bureaus; membership, employment, consultancies, stock ownership, or other equity interest; and expert testimony or patent-licensing arrangements), or non-financial interest (such as personal or professional relationships, affiliations, knowledge or beliefs) in the subject matter or materials discussed in this manuscript.

This statement is signed by all the authors to indicate agreement that the above information is true and correct

References

- [1] R. Parisi, I.Y.K. Iskandar, E. Kontopantelis, M. Augustin, C.E.M. Griffiths, D.M. Ashcroft, G P, *BMJ* 369 (2020) m1590 -m1590 <https://doi.org/10.1136/bmj.m1590>.
- [2] R.S. Stern, T. Nijsten, S.R. Feldman, D.J. Margolis, T. Rolstad, J. Invest. Dermatol. Symp. Proc. 9 (2004) 136–139 <https://doi.org/10.1046/j.1087-0024.2003.09102.x>.
- [3] World Health Organization, Global report on Psoriasis, Geneva, 2016. [https://apps.who.int/iris/bitstream/handle/10665/204417/9789241565189_eng.pdf.psoriasis?sequence=1#%3A~:text=Psoriasis occurs worldwide.,and 5%25 \(27\)](https://apps.who.int/iris/bitstream/handle/10665/204417/9789241565189_eng.pdf.psoriasis?sequence=1#%3A~:text=Psoriasis occurs worldwide.,and 5%25 (27)).
- [4] N. Charoenngam, M.F. Holick, *Nutrients* (2020) 12 <https://doi.org/10.3390/nu12072097>.
- [5] L. Barrea, M.C. Savanelli, C. Di Somma, M. Napolitano, M. Megna, A. Colao, S. Savastano, *Rev. Endocr. Metab. Disord.* 18 (2017) 195–205 <https://doi.org/10.1007/s11154-017-9411-6>.
- [6] R. Gniadecki, *J. Invest. Dermatol.* 106 (1996) 510–516 <https://doi.org/10.1111/1523-1747.ep12343866>.
- [7] J. Reichrath, *Exp. Dermatol.* 16 (2007) 618–625 <https://doi.org/10.1111/j.1600-0625.2007.00570.x>.
- [8] K. Matsumoto, K. Hashimoto, Y. Nishida, M. Hashiro, K. Yoshikawa, *Biochem. Biophys. Res. Commun.* 166 (1990) 916–923 [https://doi.org/10.1016/0006-291x\(90\)90898-w](https://doi.org/10.1016/0006-291x(90)90898-w).
- [9] F. Zhang, A. Moayyeri, T.D. Spector, *Curr. Cardiovasc. Risk Rep.* 6 (2012) 549–555.
- [10] D.C. Finamor, R. Sinigaglia-Coimbra, L.C.M. Neves, M. Gutierrez, J.J. Silva, L.D. Torres, F. Surano, D.J. Neto, N.F. Novo, Y. Juliano, *Dermatoendocrinol* 5 (2013) 222–234.
- [11] G. Jones, *Am. J. Clin. Nutr.* 88 (2008) 582S–586S.
- [12] D. Lemke, R.J. Klement, F. Schweiger, B. Schweiger, J. Spitz, *Front. Immunol.* 12 (2021) 1110.
- [13] S.R. Feldman, G.G. Krueger, *Ann. Rheum. Dis.* 64 (2005) LPii65–LPii68 <https://doi.org/10.1136/ard.2004.031237>.
- [14] N.Q. Phan, C. Blome, F. Fritz, J. Gerss, A. Reich, T. Ebata, M. Augustin, J.C. Szepietowski, S. Ständer, *Acta Derm. Venereol.* 92 (2012) 502–507 <https://doi.org/10.2340/00015555-1246>.
- [15] S.R. Feldman, B. Goffe, G. Rice, M. Mitchell, M. Kaur, D. Robertson, D. Sierka, J.A. Bourret, T.S. Evans, A. Gottlieb, *Am. Heal. Drug Benefits.* 9 (2016) 504–513 <https://pubmed.ncbi.nlm.nih.gov/28465778>.
- [16] J.R. Goldsmith, *Healthc. (Basel, Switzerland)* 3 (2015) 219–232 <https://doi.org/10.3390/healthcare3020219>.
- [17] B. Visconti, G. Paolino, S. Carotti, A.L. Pendolino, S. Morini, A.G. Richetta, S. Calvieri, *J. Eur. Acad. Dermatol. Venereol.* 29 (2015) 2038–2042 <https://doi.org/https://doi.org/10.1111/jdv.12736>.
- [18] E.D.O. Roberson, A.M. Bowcock, *Trends Genet* 26 (2010) 415–423 <https://doi.org/10.1016/j.tig.2010.06.006>.
- [19] M.F. Holick, *Mayo Clin. Proc.* 90 (2015) 561–564 <https://doi.org/10.1016/j.mayocp.2015.03.015>.
- [20] C.L. Carroll, S.R. Feldman, F.T. Camacho, R. Balkrishnan, *Br. J. Dermatol.* 151 (2004) 895–897 <https://doi.org/10.1111/j.1365-2133.2004.06174.x>.
- [21] M.F. Holick, *N. Engl. J. Med.* 357 (2007) 266–281.