

Vitamin D and tear fluid cytokines in predicting outcomes in viral conjunctivitis - A new outlook

Gairik Kundu, Rohit Shetty, Durgalaxmi Modak, Ameeta Koul, Srihari Balaraj, Harsha Nagaraja, Swaminathan Sethu¹

Purpose: To determine the association between systemic vitamin D (VD) and immunoglobulin E (IgE) levels with severity and ocular surface inflammatory profile in patients with epidemic keratoconjunctivitis (EKC). **Methods:** 210 eyes of 105 patients who were clinically diagnosed with EKC were included in the study. The levels of serum VD and serum IgE were measured. Schirmer's strip-based tear fluid (TF) was used to determine levels of IL-1 β , IL-6, IL-10, IL-17A, TNF α , MMP9, sICAM1, and VEGF-A in a subset of patients. **Results:** Levels of VD were significantly ($P < 0.05$) lower and levels of IgE were significantly higher in patients with severe forms of conjunctivitis compared to those with nonsevere forms. Majority of the patients with severe forms of the disease exhibited VD deficiency and/or abnormally high IgE. A negative correlation ($r = -0.682$; $P < 0.0001$) was observed between VD and IgE levels. TF levels of IL-1 β , IL-6, TNF α , and sICAM1 were significantly higher in eyes with severe forms of conjunctivitis compared to those with nonsevere forms and controls. These factors showed a positive correlation ($P < 0.05$) with IgE levels and a negative correlation ($P < 0.05$) with VD levels. **Conclusion:** Patients with severe forms of EKC exhibited VD deficiency and higher levels of IgE. Increased TF inflammatory factors demonstrated a disease causal relationship with VD and IgE. Hence, restoring the altered levels of VD and IgE to normal range would be pivotal in the prevention and management of severe conjunctivitis.

Key words: Conjunctivitis, cytokines, interleukins, IgE, tear fluid, vitamin D

Infectious conjunctivitis is one of the most common ocular emergencies affecting a diverse group of population.^[1] Viral conjunctivitis is caused by a variety of viruses, such as adenovirus, enterovirus, coxsackie, and herpetic are the most common cause of infectious conjunctivitis.^[2] Adenovirus constitutes approximately 60% of the viral conjunctivitis cases and is known to be highly contagious. Viral conjunctivitis notably presents with redness, foreign body sensation, and serous discharge, while some patients may present with subconjunctival hemorrhage, pseudomembrane, or blurring of vision due to punctate keratopathy.^[3] Diagnosis of epidemic keratoconjunctivitis (EKC) caused by adenovirus is most commonly based on clinical features while novel adenoviral detection kits using tears or conjunctival discharge have been used for rapid diagnosis in outpatient departments.^[4] Polymerase chain reaction (PCR)-based assay to detect DNA from virus can be done; however, the procedure is time-consuming and not cost-effective in the cases of outbreaks.^[5] Though EKC is known to be self-limiting, it can cause severe distress to the patient due to severe ocular surface inflammation, blurring of vision due to corneal involvement, conjunctival scarring, or dry eye due to the formation of pseudomembranes.^[6] Treatment is mainly symptomatic with the use of topical steroids, povidone-iodine, lubricants, and

topical antibiotics (when associated with bacterial infection) along with hygienic measures.^[6,7]

There has been no clear consensus as to the use of topical medications, especially regarding the use of topical steroids in EKC. There is also limited information regarding the molecular factors that can influence the severity of the disease. In our study, we analyzed systemic factors, such as vitamin D, IgE levels, and used the tears of EKC patients to look for inflammatory markers and correlate the severity of the disease with these markers.

Methods

Study design and cohort

The cross-sectional study was approved by the institutional ethics committee and study subjects were recruited after obtaining their informed written consent to participate in the study. Study recruitment and sample collection procedures were conducted as per institutional guidelines and the tenets of the Declaration of Helsinki. 210 eyes of 105 patients who were clinically diagnosed to have viral conjunctivitis during the recent outbreak of infective viral conjunctivitis between

This is an open access journal, and articles are distributed under the terms of the Creative Commons Attribution-NonCommercial-ShareAlike 4.0 License, which allows others to remix, tweak, and build upon the work non-commercially, as long as appropriate credit is given and the new creations are licensed under the identical terms.

For reprints contact: WKHLRPMedknow_reprints@wolterskluwer.com

Cite this article as: Kundu G, Shetty R, Modak D, Koul A, Balaraj S, Nagaraja H, et al. Vitamin D and tear fluid cytokines in predicting outcomes in viral conjunctivitis - A new outlook. Indian J Ophthalmol 0;0:0.

Access this article online

Website:
<https://journals.lww.com/ijo>

DOI:
10.4103/IJO.IJO_2345_23

Quick Response Code:



Department of Cornea and Refractive Surgery, Narayana Nethralaya, Bangalore, Karnataka, ¹GROW Research Laboratory, Narayana Nethralaya Foundation, Bangalore, Karnataka, India

Correspondence to: Dr. Gairik Kundu, Narayana Nethralaya, #121/C, Chord Road, 1st 'R'Block, Rajajinagar, Bangalore - 560 010, Karnataka, India. E-mail: k.gairik@gmail.com

Received: 26-Aug-2023

Revision: 06-Jan-2024

Accepted: 11-Jan-2024

Published: 16-Apr-2024

June and July 2023 were included. We classified conjunctivitis into nonsevere (mild or moderate) and severe based on the symptoms and clinical features. Patients with pain score of 1–3 on Wong–Baker pain scale, conjunctival congestion limited to fornices with few follicles (<5) were classified without corneal involvement as mild conjunctivitis; patients with pain score of 4–6, serous discharge, diffuse bulbar, and forniceal congestion with follicles involving the entire palpebral conjunctiva with or without the corneal involvement were classified as moderate conjunctivitis; while those with pain score >7, copious discharge, and matting of lashes, bulbar congestion with chemosis or subconjunctival hemorrhage, petechial hemorrhage, or pseudomembrane and large follicles with/without corneal involvement were classified as severe conjunctivitis.

Inclusion criteria- All 210 eyes, which were clinically diagnosed as viral conjunctivitis, based on the above criteria were included.

Exclusion criteria- Patients diagnosed as having bacterial conjunctivitis based on proven growth on culture, clinically diagnosed allergic conjunctivitis, a known case of glaucoma, a known case of dry eye on topical medications/immunomodulators, any previous eye surgery, and allergy to any topical medications, known case of type 2 diabetes mellitus, any diagnosed immunocompromised state, on any systemic medications were excluded from the study.

Tear fluid (TF) for cytokine were measured in a subset of patients (84 eyes) of clinically diagnosed viral conjunctivitis. Tear fluid was also obtained from age and sex matched healthy volunteers (n = 48 eyes) who did not have any ocular conditions and are not on any active medication or therapy. Ocular surface health index that was determined in these healthy controls indicate that the Schirmer's test 1 (ST1) values were >10 mm/5 mins, Tear break up time (TBUT) was >10 seconds, and the ocular surface disease index (OSDI) values were less than 13 for all the control subjects.

Vitamin D and IgE level measurements

The levels of vitamin D and IgE were measured in the serum of study subjects by ELISA by strictly adhering to the manufacturer's instructions. Based on the levels of vitamin D the patients were sub-categorized into those with severe deficiency (<10 ng/mL), moderate deficiency (10–20 ng/mL), insufficiency (20–30 ng/mL), and sufficiency (\geq 30 ng/mL).^[8] Further, the study subjects were also grouped based on IgE levels as those with normal levels (<100 IU/mL), mildly high (100–300 IU/mL), moderately high (300–1000 IU/mL), and very high (>1000 IU/mL) levels of IgE.

Tear fluid secreted factors or cytokine measurements

The levels of TF IL-1 β , IL-6, IL-10, IL-17A, TNF α , MMP9, sICAM1, and VEGF-A were measured using a microfluidic cartridge-based multiplex ELISA kit (Bio-M Pathfinder, NovoMol-Dx, India, a customized version of the Ella™ Automated ELISA system, Bio-Techne® Corporation, Minnesota, USA). Briefly, TF was collected using a sterile Schirmer's strip as previously described and stored at -80°C until further processing. TF was extracted by agitating the Schirmer's strip in 300 μ L of extraction buffer for 5 minutes at room temperature. Following which 50 μ L of the elute was added to the microfluidic cartridge as per the manufacturer's

instruction. The absolute concentration for each analytes was determined based on the standard curve. The final concentration for every analyte for each sample of the study subjects was determined by factoring in the wetting length of the Schirmer's strip during TF collection and the dilution factor based on the tear extraction buffer volume used.

Statistical analysis

Shapiro–Wilk test was performed to determine the distribution of the data. Differences in the various parameters between the groups were tested for statistical significance by Mann–Whitney test, Kruskal–Wallis test with Dunn's multiple comparisons test, and Wilcoxon matched-pairs signed rank test using GraphPad Prism 10 (GraphPad Software, Inc., La Jolla, CA, USA). Correlation among the various study parameters was determined by Spearman Rank correlation tests using MedCalc® Version 12.5 (MedCalc Software, Ostend, Belgium). $P < 0.05$ was considered to be statistically significant.

Results

The median age and range of patients presenting with conjunctivitis was 33 and 18–49 years, respectively [Table 1]. Patients presenting with conjunctivitis exhibited either mild to moderate, or severe forms of the condition at the time of presentation. 23% of the patients presented with bilateral mild or moderate forms (NSB), 36% of the patients presented with asymmetry in the severity, with one eye presenting with severe form and the contralateral eye with milder form conjunctivitis (SU), and 41% of the patients had bilateral presentation of severe forms of the disease. These forms of clinical presentation were not associated to specific age ranges among the study subjects [Table 1].

Vitamin D and IgE have been very important modifiable factors in the pathogenesis of diseases with immuno-inflammatory reactions, including conjunctivitis. Hence, the levels of serum vitamin D and IgE were measured in these patients. 96% of the patients in the study cohort had lower than normal levels of vitamin D (<30 ng/mL) and 71% of the patients had abnormally higher levels of IgE (>100 IU/mL). A significant difference was observed in the levels of serum vitamin D and serum IgE in patients with different severity forms of conjunctivitis [Table 1]. Significantly lower levels of vitamin D were observed in patients with severe forms of the disease compared to non-severe forms [Table 1]. The levels of IgE were observed to be significantly higher in patients with severe forms of the disease with reference to non-severe forms of the disease [Table 1]. The higher percentage of subjects with non-severe forms of the disease exhibited vitamin D (\geq 20 ng/mL) and normal levels of IgE (<100 IU/mL) as shown in Fig. 1a and b. Most patients with severe forms of conjunctivitis were observed to have lower levels of vitamin D (<20 ng/mL) and IgE levels higher than 100 IU/mL [Fig. 1a and b]. In addition, a significant negative correlation ($r = -0.682$; $P < 0.0001$) was observed between serum vitamin D and serum IgE levels in these patients [Fig. 1c] emphasizing the clinical relevance of these parameters in conjunctivitis.

In addition, to the clinical stratification of severity, the magnitude of ocular surface inflammation was assessed by measuring the levels of inflammatory factors in the TF of these patients. It was observed significantly higher levels of IL-1 β , IL-6, IL-10, IL-17A, TNF α , MMP9, and sICAM1 in the eyes

Table 1: Cohort characteristics

	All		Non-severe, Bilateral (NSB)		Severe, Unilateral (SU)		Severe, Bilateral (SB)		P			
	Median	Range	Median	Range	Median	Range	Median	Range	Kruskal-Wallis test [†]	NSB vs SU	NSB vs SB	SU vs SB
Age (yrs)	33	(18-49)	33	(19-44)	31.5	(18-49)	32	(18-46)	ns	ns	ns	ns
Sex (M/F)	60/45		14/10		20/18		26/17		na	na	na	na
Serum vitamin D (ng/ml)	15	(16-33)	23	(8-25)	16	(6-30)	10	(6-33)	<0.0001	<0.0001	<0.0001	<0.0001
Serum IgE (IU/ml)	178	(8-1800)	44.5	(8-223)	153	(14-1800)	457	(45-1800)	<0.0001	<0.0001	<0.0001	<0.0001

[†]Statistical analysis was performed between NSB, SU and SB groups; ns - not significant; na - not applicable; P<0.05 is statistically significant; Kruskal Wallis test with Dunn's multiple comparison test

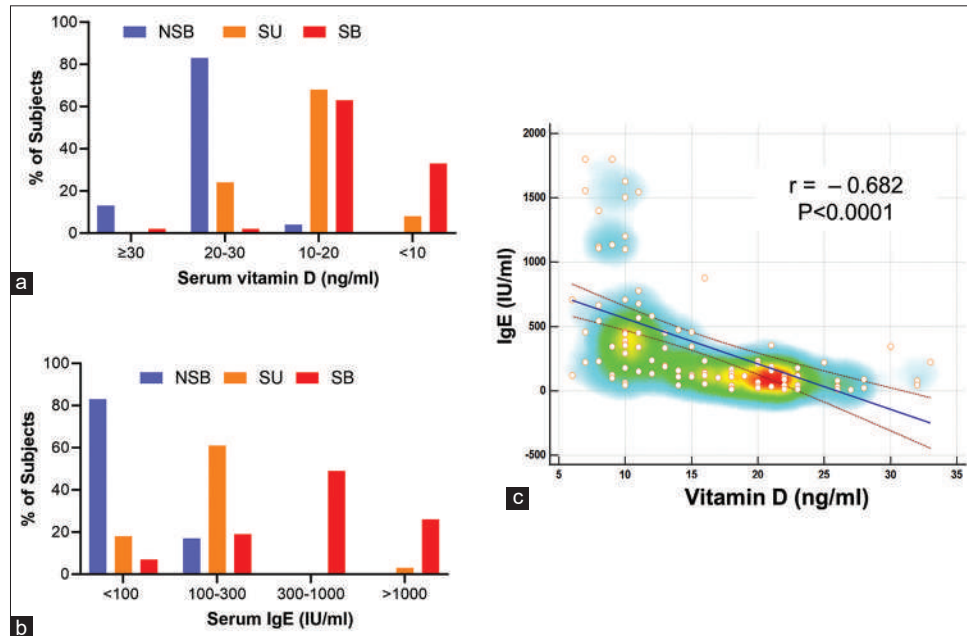


Figure 1: Relationship of conjunctivitis severity with vitamin D and IgE. (a) The panel shows the percentage of the patients with either (i) bilateral and mild or moderate forms (NSB) of the disease, (ii) asymmetry in the severity, with one eye presenting with severe forms and the contralateral eye with milder form conjunctivitis (SU), or (iii) bilateral presentation of severe form of the disease (SB) and under four categories based on their serum vitamin D levels. It includes sufficiency (≥ 30 ng/mL), insufficiency (20–30 ng/mL), moderate deficiency (10–20 ng/mL), and severe deficiency (<10 ng/mL). (b) The panel shows the percentage of the patients with either (i) bilateral and mild or moderate forms (NSB) of the disease, (ii) asymmetry in the severity, with one eye presenting with severe forms and the contralateral eye with milder form conjunctivitis (SU), or (iii) bilateral presentation of severe form of the disease (SB) and under four categories based on their serum IgE levels. It includes normal levels (<100 IU/mL), mildly high (100–300 IU/mL), moderately high (300–1000 IU/mL), and very high (>1000 IU/mL). (c) The correlation plot reveals a negative correlation between serum vitamin D and serum IgE levels in the study cohort. $r =$ Spearman rank correlation coefficient. $P < 0.05$ is statistically significant

of patients with conjunctivitis compared to controls [Fig. 2]. The levels of VEGF-A in the TF remained similar between controls and patients with conjunctivitis [Fig. 2]. The levels of IL-6, IL-10, IL-17A, TNF α , and MMP9 were significantly higher in the TF of patients with mild or moderate forms of conjunctivitis compared to controls [Fig. 3a-h]. Similarly, the levels of IL-1 β , IL-6, IL-10, IL-17A, TNF α , MMP9, and sICAM1 were significantly higher in the TF of patients with severe forms of conjunctivitis compared to controls [Fig. 3a-h]. It was observed that TF IL-1 β , IL-6, TNF α , and sICAM1 levels were significantly higher eyes with severe forms of the disease compared to non-severe forms of the disease [Fig. 3a-h]. Paired analysis in patients with asymmetric presentation of severity reveals that the levels of IL-1 β , IL-6, IL-10, TNF α , and sICAM1

were significantly higher in the eyes with severe forms of the disease compared to contralateral eyes with mild or moderate forms of the disease [Fig. 3i-p]. Importantly, serum IgE levels were observed to be positively correlated with TF IL-1 β , IL-6, IL-10, TNF α , MMP9, and sICAM1 levels [Table 2] and serum vitamin D levels were observed to be negatively correlated with TF IL-1 β , IL-6, TNF α , and sICAM1 levels [Table 2] in these patients.

Discussion

Viral conjunctivitis, although self-limiting in nature can have long-term consequences and repercussions on the cornea and ocular surface. There are lacunae in our current understanding with reference to the factors that may influence the severity

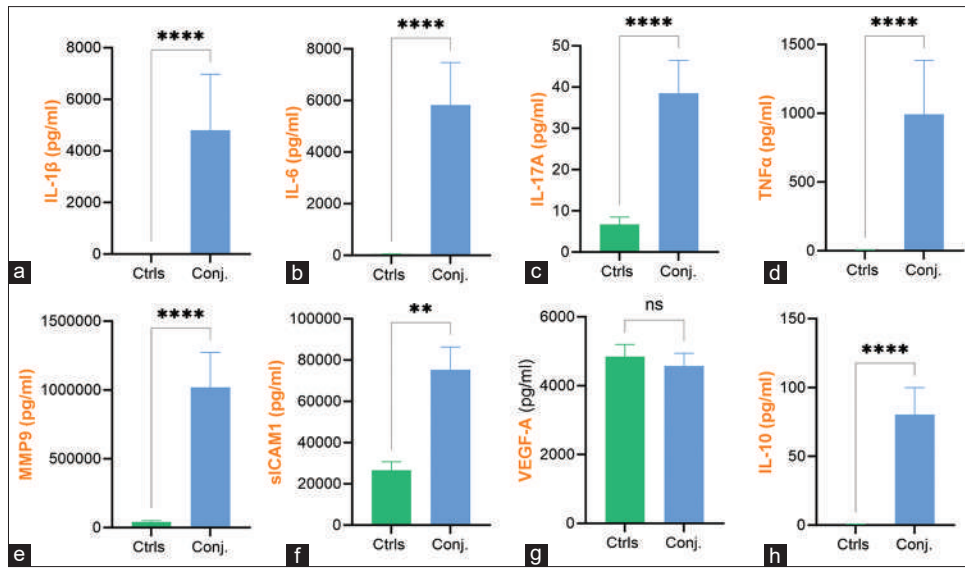


Figure 2: Tear fluid secreted factors levels in patients with conjunctivitis and healthy controls. The bar graph panels represent mean ± SEM of tear fluid levels of (a) IL-1β, (b) IL-6, (c) IL-17A, (d) TNFα, (e) MMP9, (f) sICAM1, (g) VEGF-A, and (h) IL-10 in healthy controls and patients with conjunctivitis. Controls (Ctrls, n = 48 eyes); Conjunctivitis (Conj., n = 84 eyes); ***P* < 0.01, *****P* < 0.0001; Mann–Whitney test

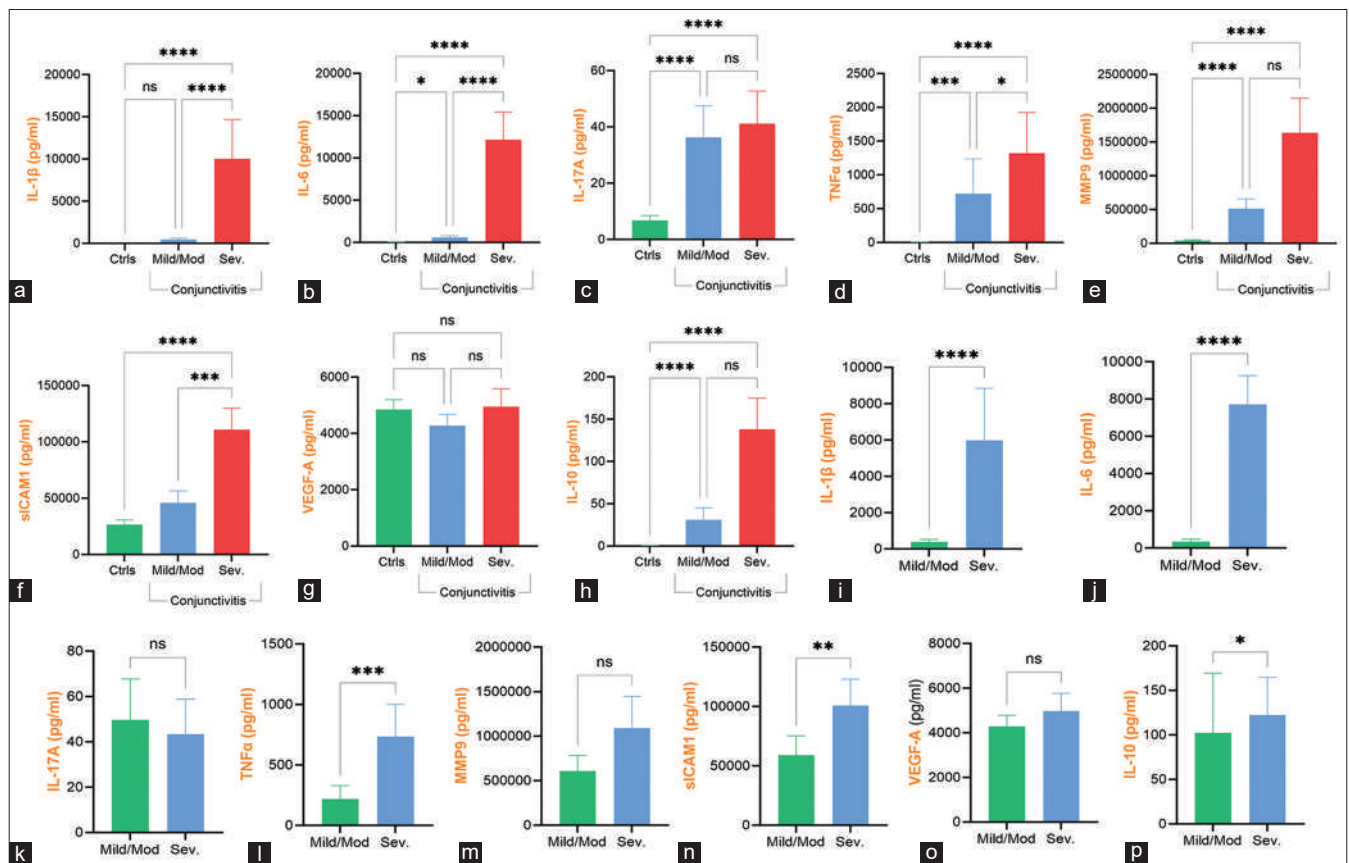


Figure 3: Tear fluid secreted factors levels in patients with severe and non-severe forms of conjunctivitis. The bar graph panels represent mean ± SEM of tear fluid levels of (a) IL-1β, (b) IL-6, (c) IL-17A, (d) TNFα, (e) MMP9, (f) sICAM1, (g) VEGF-A, and (h) IL-10 in healthy controls and patients with non-severe forms conjunctivitis (Mild/Mod) and severe form of conjunctivitis (Sev.). Controls (Ctrls, n = 48 eyes); Non-severe forms of conjunctivitis (Mild/Mod, n = 37 eyes); Severe conjunctivitis (Sev., n = 47 eyes); **P* < 0.05, ****P* < 0.001; *****P* < 0.0001; Kruskal–Wallis test with Dunn’s multiple comparisons test; ns, indicates comparison not statistically significant. Panels “i” to “p” show the tear fluid secreted factors levels in patients with asymmetry in the presentation of severity of conjunctivitis. The bar graph panels (i to p) represent mean ± SEM of matched tear fluid levels of (i) IL-1β, (j) IL-6, (k) IL-17A, (l) TNFα, (m) MMP9, (n) sICAM1, (o) VEGF-A, and (p) IL-10 from the eyes of 21 patients with non-severe forms conjunctivitis (Mild/Mod) in one eye and severe form of conjunctivitis (Sev.) in the contralateral eye. Mild/Moderate Conjunctivitis (Mild/Mod) and Severe Conjunctivitis (Sev.); **P* < 0.05; ***P* < 0.01; ****P* < 0.001; *****P* < 0.0001; Wilcoxon matched-pairs signed rank test

Downloaded from http://journals.lww.com/ijfo by ALL-fakxU1J4KrsjyBwV/wzserPcd4Uai3QaFaimTKmBcNTPrZV Qg43KtE+1uOWLF0dzdGGQOUIB50gSC6SUIKaboHlELB0+nX6917zkmux7TEDDJlVZ4na6nmp on 04/20/2024

Table 2: Association between tear fluid inflammatory factors and serum IgE or serum vitamin D in patients with conjunctivitis

Tear secreted factors (pg/ml)	Serum IgE (IU/ml)		Serum Vitamin D (ng/ml)	
	<i>r</i>	<i>P</i>	<i>r</i>	<i>P</i>
IL-1 β	0.574	<0.0001	-0.509	<0.0001
IL-6	0.548	<0.0001	-0.504	<0.0001
IL-17A	0.092	0.4683	-0.048	0.7056
TNF α	0.454	0.0002	-0.395	0.0013
MMP9	0.257	0.0405	-0.193	0.1272
sICAM1	0.29	0.0203	-0.265	0.034
VEGF-A	0.09	0.4784	-0.156	0.2172
IL-10	0.289	0.0204	-0.226	0.072

r – Spearman rank correlation coefficient; *P*<0.05 is considered statistically significant

and outcomes. Inappropriate treatment may worsen the clinical scenarios of EKC, acute hemorrhagic conjunctivitis, and pharyngoconjunctival fever that may affect visual acuity.^[9] Although viral conjunctivitis accounts for 80% of infectious conjunctivitis cases, misdiagnosing viral conjunctivitis as bacterial conjunctivitis, and over-the-counter use of antibiotics may worsen the burden of antimicrobial resistance.^[10] There is no definitive treatment for adenoviral conjunctivitis and it is a self-limiting disease that usually resolves in 3–5 weeks. It is commonly managed conservatively with lubricants and antibiotics to prevent secondary bacterial infections during the course of the disease. A large population study^[11] in India showed that over two-thirds (78.5%) of the patients were prescribed lubricants, over half (58.7%) of them were prescribed prophylactic antibiotic eye drops, and about one-third (31.6%) of the cases required the use of steroid eye-drops to control the inflammation and also treat the flare-ups.^[11] The treatment choices are usually based on the severity of the disease at the time of presentation. Hence, determining patient-specific factors that may predispose to severe manifestations would be beneficial for patients' stratification, prophylaxis, and management. This would facilitate provision of better care and preparedness in the event of outbreaks to reduce the severity and complications associated with viral conjunctivitis. Since, immuno-inflammatory reactions underlie the clinical presentation in conjunctivitis, the efforts in the current study were directed to determine the status of vitamin D (endogenous immuno-inflammatory dampening factor) and IgE (a key contributor in mucosal immune reactions) in patients with different grades of severity of clinically diagnosed viral conjunctivitis.

Vitamin D, a fat-soluble hormone and nutrient in our diet, regulates a variety of physiological functions including bone metabolism, calcium and phosphorus homeostasis, and immunomodulation, and facilitates protection against infectious diseases. Despite the well-documented roles of vitamin D in ocular physiology and inflammation, its relevance in eye diseases of infectious etiology is rather sparse. More recently, it has been reported to be protective against COVID-19-associated conjunctivitis.^[12] Large body of evidence points to the protective role of vitamin D in allergic conjunctivitis with decreased levels

of vitamin D in these patients compared to controls.^[13,14] A study reported the beneficial correlation between the levels of vitamin D and severity of vernal keratoconjunctivitis in children.^[15] Observations from the current study clearly indicates that the severity of the manifestations in EKC patients was associated with more severe forms of vitamin D deficiency. Further, the levels of vitamin D were observed to be negatively correlated with serum IgE and TF inflammatory factors in the current patient cohort, suggesting the direct relationship between vitamin D and clinical manifestations and their underlying contributing factors. Since, vitamin D is a potent, natural, endogenous immuno-inflammatory dampener, its deficiency can be attributed to clinical severity along with increased systemic IgE and ocular surface inflammatory factors observed in these patients. In addition, patients with vitamin D deficiency can be increasingly susceptible to infections, as vitamin D is also known to regulate mechanisms that facilitate antibacterial and antiviral actions.^[16,17] Vitamin D-based complementary therapy has been proven to be effective in the prevention of clinical exacerbations of allergic rhino conjunctivitis.^[18] Hence, it would be clinically beneficial to include vitamin D supplementation^[8] as a part of the prophylaxis and treatment of inflammatory conditions of the eye, including the management of infectious conjunctivitis sequelae. High levels of IgE serve as one of the major indicators of allergy and have been well-correlated with the best-characterized allergic disorders, such as vernal keratoconjunctivitis, perennial conjunctivitis, and seasonal allergic conjunctivitis, which are largely driven via IgE-dependent mechanisms. Many of the viruses which cause upper respiratory tract infections have also been isolated in viral conjunctivitis outbreaks have been known to enhance Th2-mediated airway inflammation in asthma.^[19,20] Mechanisms that underlie virus-induced IgE antibodies in allergic disease or heightened inflammation due to viral infections in an already allergic patient are yet to be elucidated. Hence, investigations directed toward these aspects will prove informative and could aid the development of novel preventative and targeted therapies for various conditions.

The increased local inflammatory milieu is one of the classical features of conjunctivitis, irrespective of allergic and/or infectious etiology.^[21] Despite the fact that the viral conjunctivitis is a self-limiting condition, the increase in the ocular inflammatory milieu during a severe presentation would result in other ocular complications. An increase in ocular surface inflammatory factors including IL-6 and TNF α during conjunctivitis have been reported to induce retinal inflammation and subsequently promote the progression of myopia.^[22] During the process of ocular surface inflammation associated with infection, immune cell activation associated production of proinflammatory cytokines, such as TNF α , interleukins (ILs; IL-1 and IL-6), and matrix metalloproteinase-9 (MMP-9) is well known. Tear cytokines analysis has been studied in allergic conjunctivitis.^[21,23] Damage to the conjunctiva in chronic allergic conjunctivitis appears to be mediated by the activation of immune cells by environmental allergens.^[24,25] Patients with chronic allergy often present with higher levels of IL-4 and IL-5, favoring a microenvironment related to Th2 over a Th1 response.^[26] In addition, there has been an increase in other cytokines, such as IL-1 β , IL-5, IL-6, IL-8, IL-10, TNF α , and IFN γ as well in different forms of conjunctivitis.^[21,27,28] It is important to note that the pattern of elevated levels of these cytokines was

observed to be different among seasonal allergic conjunctivitis, giant papillary conjunctivitis, vernal keratoconjunctivitis, and atopic keratoconjunctivitis. Hence, the observations from the current study would add valuable information with reference to ocular surface inflammatory factors in EKC or presumed viral conjunctivitis patients. In our study, tear cytokine levels of IL-1 β , IL-6, and sICAM1 were significantly higher in eyes with severe forms of conjunctivitis compared to those with nonsevere forms and controls. It has been documented that interleukin-8 may play a role in the development of subepithelial infiltrates in adenovirus keratitis along with IL-6.^[29] On the other hand, IL-1 β , IL-6, and IL-8 were significantly elevated in tears from eye with bacterial infection.^[30] IL-17A, which was observed to be elevated in both nonsevere and severe forms of conjunctivitis has been reported to be associated in the pathogenesis of allergic conjunctivitis as well.^[31] Interestingly, sICAM1, which was observed to be significantly increased in patients with severe forms of the disease in the current study, was reported to be increased in allergic conjunctivitis as well^[32] and as a therapeutic target for the resolution of conjunctivitis.^[33] Altogether, in different types of conjunctivitis (i.e. viral, bacterial, or allergic) diverse pathogenic factors can induce the secretion of several specific immune factors, which are generally uniform, and mostly are responsible for similar symptoms in affected eyes. Thus, tear cytokine profile in course of viral infections may present numerous similarities with cytokine profiles in other inflammation-based conjunctival disorders. It is noteworthy that therapeutic agents including monoclonal antibodies and small molecules are already available in the clinics that can specifically target these altered inflammatory cytokines such as IL-1 β , IL-6, TNF α , IL-17A, and ICAM1. Future studies would enable treatment planning based on selective targeting of these inflammatory factors to facilitate early disease resolution.

Limitations in our study included the lack of data on the isolation of specific viruses, which were causing conjunctivitis, and was predominantly a clinical diagnosis, although bacterial etiology was ruled out. We also did not specifically look at confounding factors, such as the duration of sunlight exposure on individuals, the effect of food preferences. Although known cases of type 2 diabetes mellitus, immunocompromised patients were excluded, no separate detailed analysis, or blood investigations for immune status were done. The current study was unable to ascertain the cause or consequential association of increased serum IgE levels in the current cohort to the viral infection. Further, assessment of TF IgE levels in the current cohort would have added relevance by providing regional IgE status and the possibility to study the correlation between systemic and ocular surface IgE levels in this cohort.

Conclusion

Thus, it is quite evident that patients with severe forms of conjunctivitis exhibited a lower vitamin D and a higher level of IgE. Increased tear inflammatory factors also demonstrated a correlation with vitamin D and IgE levels. Hence, restoring the levels of vitamin D and IgE to normal would be important in the management of viral conjunctivitis and in predicting which patients might be more predisposed to develop more severe forms of conjunctivitis.

Financial support and sponsorship: Nil.

Conflicts of interest: There are no conflicts of interest.

References

- Muto T, Imaizumi S, Kamoi K. Viral Conjunctivitis. *Viruses*. 2023;15:676.
- Jonas RA, Ung L, Rajaiya J, Chodosh J. Mystery eye: Human adenovirus and the enigma of epidemic keratoconjunctivitis. *Prog Retin Eye Res* 2020;76:100826.
- Chintakuntlawar AV, Chodosh J. Cellular and tissue architecture of conjunctival membranes in epidemic keratoconjunctivitis. *Ocul Immunol Inflamm* 2010;18:341-5.
- Migita H, Ueno T, Tsukahara-Kawamura T, Saeki Y, Hanaoka N, Fujimoto T, *et al.* Evaluation of adenovirus amplified detection of immunochromatographic test using tears including conjunctival exudate in patients with adenoviral keratoconjunctivitis. *Graefes Arch Clin Exp Ophthalmol*. 2019;257:815-20. doi: 10.1007/s00417-019-04281-7. Epub 2019 Mar 2. PMID: 30826875.
- O'Brien TP, Jeng BH, McDonald M, Raizman MB. Acute conjunctivitis: Truth and misconceptions. *Curr Med Res Opin* 2009;25:1953-61.
- Ghanem RC, Vargas JF, Ghanem VC. Tacrolimus for the treatment of subepithelial infiltrates resistant to topical steroids after adenoviral keratoconjunctivitis. *Cornea* 2014;33:1210-3.
- Gonzalez G, Yawata N, Aoki K, Kitaichi N. Challenges in management of epidemic keratoconjunctivitis with emerging recombinant human adenoviruses. *J Clin Virol* 2019;112:1-9.
- Gorimanipalli B, Shetty R, Sethu S, Khamar P. Vitamin D and eye: Current evidence and practice guidelines. *Indian J Ophthalmol* 2023;71:1127-34.
- Mohanasundaram AS, Gurnani B, Kaur K, Manikkam R. Madras eye outbreak in India: Why should we foster a better understanding of acute conjunctivitis? *Indian J Ophthalmol* 2023;71:2298-9.
- Visscher KL, Hutnik CM, Thomas M. Evidence-based treatment of acute infective conjunctivitis: Breaking the cycle of antibiotic prescribing. *Can Fam Physician* 2009;55:1071-5.
- Das AV, Basu S. Epidemic keratoconjunctivitis in India: Electronic medical records-driven big data analytics report IV. *Br J Ophthalmol* 2022;106:331-5.
- Xu Y, Baylink DJ, Chen CS, Reeves ME, Xiao J, Lacy C, *et al.* The importance of vitamin d metabolism as a potential prophylactic, immunoregulatory and neuroprotective treatment for COVID-19. *J Transl Med* 2020;18:322.
- Dadaci Z, Borazan M, Kiyici A, Oncel Acir N. Plasma vitamin D and serum total immunoglobulin E levels in patients with seasonal allergic conjunctivitis. *Acta Ophthalmol* 2014;92:e443-6.
- Bozkurt B, Artac H, Ozdemir H, Unlu A, Bozkurt MK, Ircek M. Serum Vitamin D levels in children with vernal keratoconjunctivitis. *Ocul Immunol Inflamm* 2018;26:435-9.
- Zicari AM, Cafarotti A, Occasi F, Lollobrigida V, Nebbioso M, Pecorella I, *et al.* Vitamin D levels in children affected by vernal keratoconjunctivitis. *Curr Med Res Opin* 2017;33:269-74.
- Hewison M. Antibacterial effects of vitamin D. *Nat Rev Endocrinol* 2011;7:337-45.
- Teymoori-Rad M, Shokri F, Salimi V, Marashi SM. The interplay between vitamin D and viral infections. *Rev Med Virol* 2019;29:e2032. doi: 10.1002/rmv. 2032.
- Marseglia G, Licari A, Ciprandi G. Complementary treatment of allergic rhinoconjunctivitis: The role of the nutraceutical Lertal (R). *Acta Biomed* 2020;91:97-106.
- Corne JM, Marshall C, Smith S, Schreiber J, Sanderson G, Holgate ST, *et al.* Frequency, severity, and duration of rhinovirus infections in asthmatic and non-asthmatic individuals: A longitudinal cohort study. *Lancet* 2002;359:831-4.
- Message SD, Laza-Stanca V, Mallia P, Parker HL, Zhu J, Kebadze T, *et al.* Rhinovirus-induced lower respiratory illness is increased in asthma and related to virus load and Th1/2 cytokine and IL-10 production. *Proc Natl Acad Sci U S A* 2008;105:13562-7.
- Cook EB. Tear cytokines in acute and chronic ocular allergic inflammation. *Curr Opin Allergy Clin Immunol* 2004;4:441-5.
- Wei CC, Kung YJ, Chen CS, Chang CY, Lin CJ, Tien PT, *et al.* Allergic conjunctivitis-induced retinal inflammation promotes myopia progression. *EBioMedicine* 2018;28:274-86.
- Salazar A, Casanova-Mendez I, Pacheco-Quito M, Velazquez-Soto H, Ayala-Balboa J, Graue-Hernandez EO, *et al.* Low Expression of IL-10 in

- circulating bregs and inverted IL-10/TNF-alpha ratio in tears of patients with perennial allergic conjunctivitis: A Preliminary study. *Int J Mol Sci* 2019;20:1035.
24. Rosario N, Bielory L. Epidemiology of allergic conjunctivitis. *Curr Opin Allergy Clin Immunol* 2011;11:471-6.
 25. Shaker M, Salcone E. An update on ocular allergy. *Curr Opin Allergy Clin Immunol* 2016;16:505-10.
 26. Magana D, Aguilar G, Linares M, Ayala-Balboa J, Santacruz C, Chavez R, *et al.* Intracellular IL-4, IL-5, and IFN-gamma as the main characteristic of CD4+CD30+T cells after allergen stimulation in patients with vernal keratoconjunctivitis. *Mol Vis* 2015;21:443-50.
 27. Anderson AE, Mackerness KJ, Aizen M, Carr VA, Nguyen D, Du Pre F, *et al.* Seasonal changes in suppressive capacity of CD4+CD25+T cells from patients with hayfever are allergen-specific and may result in part from expansion of effector T cells among the CD25+population. *Clin Exp Allergy* 2009;39:1693-9.
 28. Niedzwiedz A, Kawa M, Pius-Sadowska E, Kuligowska A, Ziontkowska A, Wrzalek D, *et al.* Increased proinflammatory cytokines in tears correspond with conjunctival SARS-CoV-2 positivity in symptomatic COVID-19 patients. *Sci Rep* 2022;12:7225.
 29. Chodosh J, Astley RA, Butler MG, Kennedy RC. Adenovirus keratitis: A role for interleukin-8. *Invest Ophthalmol Vis Sci* 2000;41:783-9.
 30. Yamaguchi T, Calvacanti BM, Cruzat A, Qazi Y, Ishikawa S, Osuka A, *et al.* Correlation between human tear cytokine levels and cellular corneal changes in patients with bacterial keratitis by *in vivo* confocal microscopy. *Invest Ophthalmol Vis Sci* 2014;55:7457-66.
 31. Meng XT, Shi YY, Zhang H, Zhou HY. The Role of Th17 Cells and IL-17 in Th2 immune responses of allergic conjunctivitis. *J Ophthalmol* 2020;2020:6917185.
 32. Oh JW, Shin JC, Jang SJ, Lee HB. Expression of ICAM-1 on conjunctival epithelium and ECP in tears and serum from children with allergic conjunctivitis. *Ann Allergy Asthma Immunol* 1999;82:579-85.
 33. Whitcup SM, Chan CC, Kozhich AT, Magone MT. Blocking ICAM-1 (CD54) and LFA-1 (CD11a) inhibits experimental allergic conjunctivitis. *Clin Immunol* 1999;93:107-13.