

## Current Concept

Clin Shoulder Elbow [Epub ahead of print]  
<https://doi.org/10.5397/cise.2024.00220>

# The role of vitamin D in shoulder health: a comprehensive review of its impact on rotator cuff tears and surgical results

Mohammad Daher<sup>1</sup>, Oscar Covarrubias<sup>2</sup>, Ryan Lopez<sup>1</sup>, Peter Boufadel<sup>1</sup>, Maria Catherine Rita Hachem<sup>3</sup>, Ziad Zalaquett<sup>3</sup>, Mohamad Y. Fares<sup>1</sup>, Joseph A. Abboud<sup>1</sup>

<sup>1</sup>Division of Shoulder and Elbow, Rothman Orthopaedic Institute, Philadelphia, PA, USA

<sup>2</sup>Department of Orthopedics, Brown University, Providence, RI, USA

<sup>3</sup>Department of Orthopedics, Hotel Dieu de France, Beirut, Lebanon

Vitamin D deficiency is highly prevalent in the general population and is associated with various chronic health conditions. In addition to its role in bone mineralization, Vitamin D has various physiological effects that may impact the pathogenesis of shoulder pathologies. Vitamin D deficiency may also affect outcomes after shoulder surgeries, such as rotator cuff repair and total shoulder arthroplasty. Vitamin D plays a role in tissue healing, bone growth, and maintenance of homeostasis in skeletal muscle cells. Vitamin D also has anti-inflammatory effects that are important to rotator cuff health. Vitamin D deficiency is highly prevalent in patients with rotator cuff tears, suggesting its role as a potential risk factor. Vitamin D deficiency has been associated with decreased preoperative shoulder strength as well as increased re-tear rates, postoperative stiffness, and the need for revision surgery in patients who underwent rotator cuff repair. Studies have also demonstrated a potential association between vitamin D deficiency and increased risk of revision after total shoulder arthroplasty. Further research is necessary to elucidate the direct role of vitamin D in the pathogenesis of rotator cuff tears and its impact on clinical outcomes after rotator cuff surgery and total shoulder arthroplasty.

**Keywords:** Rotator cuff tears; Vitamin D

## INTRODUCTION

Vitamin D is essential for the homeostatic regulation of calcium involved in a wide range of physiological processes, such as bone mineralization, nerve transmission, blood clotting, hormone secretion, and muscle contraction [1,2]. Vitamin D deficiency has been associated with chronic health conditions and is estimated to affect one billion people worldwide. Vitamin D deficiency prevalence ranges from 8.3% to 71% in patients with rotator cuff tears (RCTs) [3-5]. Of particular concern to the orthopedic surgeon is age-related bone loss thought to occur secondary to dysregulation of vitamin D metabolism with an associated decrease

in intestinal calcium absorption and increased catabolism of the active form of vitamin D (1,25-dihydroxyvitamin D) [1]. Studies in lower extremity total joint arthroplasty patients have found associations between preoperative vitamin D deficiency and persistent postoperative pain, decreased patient-reported outcome measures, and increased risk of periprosthetic joint infections (PJIs) [6-9]. The impact of preoperative vitamin D deficiency on outcomes of upper extremity surgery has been less thoroughly characterized. The link between vitamin D and osteoporosis has led to the hypothesis that low vitamin D level (< 30 ng/L) impacts shoulder surgery outcomes.

Due to age-related tendon and cartilage degeneration, elderly

Received: March 7, 2024    Revised: May 15, 2024    Accepted: May 18, 2024

Correspondence to: Mohammad Daher

Division of Shoulder and Elbow, Rothman Orthopaedic Institute, 925 Chestnut St, Philadelphia, PA 19107, USA

Tel: +1-26-7465-8920, E-mail: mohdaher1@hotmail.com, ORCID: <https://orcid.org/0000-0002-9256-9952>

© 2024 Korean Shoulder and Elbow Society.

This is an Open Access article distributed under the terms of the Creative Commons Attribution Non-Commercial License (<https://creativecommons.org/licenses/by-nc/4.0/>) which permits unrestricted non-commercial use, distribution, and reproduction in any medium, provided the original work is properly cited.

patients often undergo rotator cuff repair (RCR) and total shoulder arthroplasty (TSA). These procedures can be complicated by age-related bone loss as such patients rely on dense cancellous bone for durable fixation of suture anchors and humeral head components [10,11]. As a result of its involvement in a broad range of homeostatic processes from muscle metabolism to immune regulation, vitamin D deficiency may affect outcomes of shoulder surgery through systemic effects other than just bone mineralization [12-14]. In fact, studies have shown that vitamin D is implicated in healing modulation and muscle homeostasis, impacting the rotator cuff muscles. Therefore, the purpose of this narrative review is to describe the impact of hypovitaminosis D on outcomes of RCR and TSA.

## DATA COLLECTION

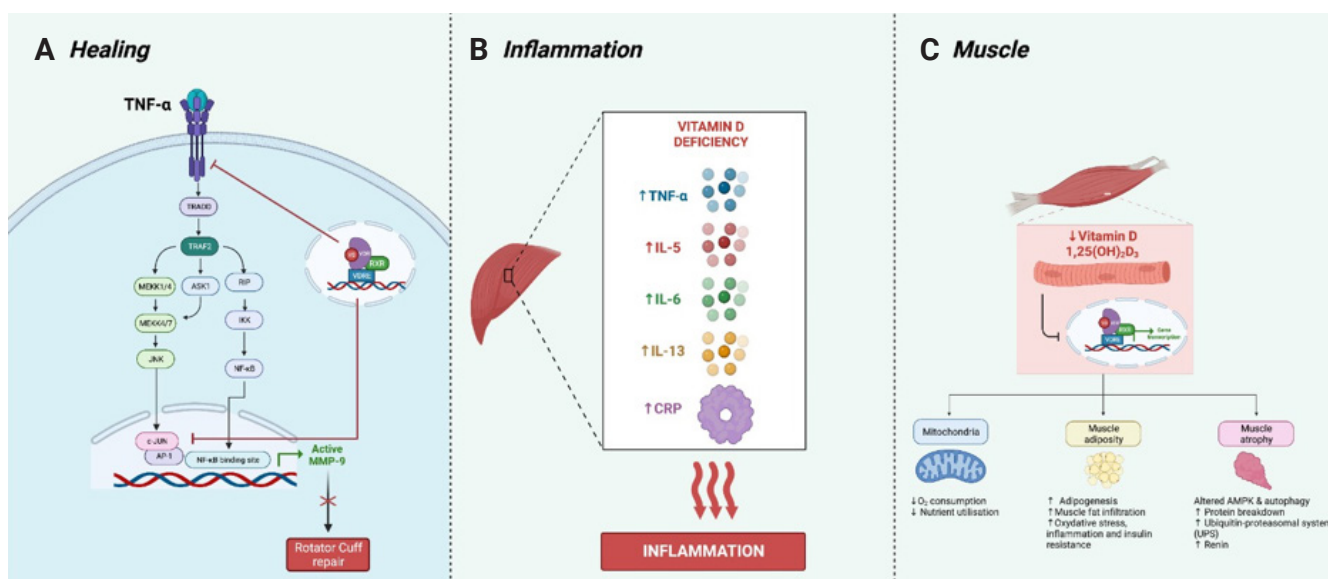
PubMed, Cochrane, and Google Scholar (page 1–20) searches were performed to December 2023 in search of qualifying papers. Using Boolean Operators, a combination of the keywords “rotator cuff” AND “vitamin” was used. Reference lists from papers and online searches were also used to find relevant literature. The data were extracted by one researcher, and the article selection was verified by a different researcher.

## PATHOPHYSIOLOGY OF HYPOVITAMINOSIS D ON THE ROTATOR CUFF (Fig. 1)

Vitamin D plays an important role in various physiological processes, particularly in bone growth, healing, and maintenance of homeostasis in skeletal muscle cells. Vitamin D is metabolized to its active form after the hepatically modified calcifediol (25-hydroxyvitamin D3) is hydroxylated in the kidney to calcitriol (1,25-dihydroxyvitamin D3). Vitamin D exerts its effects by interacting with vitamin D receptors (VDRs) to play a role in a variety of functions including, but not limited to, bone mineralization, regulation of blood calcium and phosphate levels, regulation of parathyroid hormone, and modulation of inflammatory biomarkers.

### Modulation of Tissue Healing

After RCR, tendon healing at the tendon-bone interface results in deposition of fibrovascular scar tissue that is weaker than the native tendon and is more susceptible to failure [15]. This new tissue is formed of collagen type III and is later replaced by type I collagen. The ratio of type I to type III collagen is, therefore, an indicator of healing after RCR [15,16]. This collagen architecture is mediated by remodeling by matrix metalloproteinases (MMP), specifically MMP-1, MMP-9, and MMP-13 [17-21]. Research has revealed a role for vitamin D in tissue healing. One pathway by which vitamin D modulates healing is the downregulation of cellular response to tumor necrosis factor (TNF)-α by inhibition of



**Fig. 1.** Illustration of the effects of vitamin D on healing (A), inflammation (B), and muscle (C) homeostasis. TNF: tumor necrosis factor, NF-κB: nuclear factor kappa B, MMP: matrix metalloproteinases, IL: interleukin, CRP: C-reactive protein. Made with BioRender.

c-Jun-N-terminal kinase. This blocks both nuclear factor kappa B and activator protein 1 transcription factors [22]. These actions collectively downregulate MMP-9, a factor associated with compromised healing of the rotator cuff when overexpressed [22]. MMP-9 expression is increased in the tendon-to-bone healing site in rats with vitamin D deficiency [12].

### Vitamin D as an Anti-inflammatory Agent

The anti-inflammatory effects of vitamin D have been elucidated in several studies. Insufficient vitamin D level has been linked to higher levels of inflammatory markers like TNF- $\alpha$ , interleukin (IL)-1 $\beta$ , IL-5, IL-6, IL-13, and C-reactive protein [23-27]. The association with anti-inflammation is further supported by Kim et al. [23], who found increased expression of inflammatory genes (IL-6, IL-1B) and gene products (IL-6) in the deltoid and supraspinatus tissues of RCT patients with vitamin D deficiency.

### Muscle Homeostasis

Vitamin D has been demonstrated to play a role in healthy muscle growth and metabolism. Deficiencies in vitamin D cause muscle weakness in proximal muscle groups, notably type II (fast-twitch) fibers [13]. Importantly, vitamin D supplementation has a beneficial effect on muscle volume and may reverse vitamin D deficiency-related weakness [13,28,29]. These results have been supported in animal models, in which rotator cuff muscles in vitamin D-deficient rats had inferior biomechanical properties and decreased collagen fiber organization in the enthesis [12].

Adequate *VDR* expression is crucial for vitamin D to promote myogenesis, proper calcium regulation, and maintenance of muscle homeostasis [25,30]. The expression of *VDR* is related to vitamin D level [31]. Long-term vitamin D deficiency leads to low expression of *VDR*, resulting in decreased myocyte protein content, oxidative stress, mitochondrial dysfunction, and lower muscle fiber cross-sectional area [30]. These results were mirrored in *VDR* knockdown mice [32]. In a study by Rhee et al. [4], vitamin D deficiency in RCR patients led to decreased expression of *VDR* and *myoD* and increased *atrogin* expression in the ipsilateral deltoid muscle. These gene expression changes are consistent with impaired muscle homeostasis and increased muscle atrophy. The torn rotator cuff tendons in this study did not exhibit the same gene expression changes as the deltoid, indicating that unloading of the rotator cuff may alter the muscle's response to vitamin D deficiency [23]. Increased *atrogin* expression is implicated in protein degradation via the Src-ERK1/2-Akt-FOXO pathway in myocytes, leading to muscle atrophy [33]. Notably, Kim et al. [23] did not observe an effect of vitamin D deficiency on the expression of adipogenic genes (C/EBP $\alpha$ , PPAR $\gamma$ ) in

the deltoid or supraspinatus muscle. These findings correlate with the lack of a relationship between vitamin D deficiency and fatty atrophy observed in the study by Rhee et al. [4].

Vitamin D is important for healing, anti-inflammation, and skeletal muscle homeostasis. In tendon healing after RCR, vitamin D helps regulate collagen formation and modulates tissue repair by downregulating inflammatory responses and MMPs. Deficiency in vitamin D leads to higher levels of inflammatory markers and compromised tendon-to-bone healing. Additionally, vitamin D is essential for muscle growth and metabolism; deficiencies cause muscle weakness and atrophy due to decreased *VDR* expression and impaired myocyte function. This deficiency alters muscle gene expression, notably increasing atrophy markers that can disrupt muscle homeostasis and regeneration.

## HYPOVITAMINOSIS D AND THE ROTATOR CUFF (Table 1)

### Vitamin D Status as a Risk Factor for RCT

Vitamin D is a key mediator of muscle, tendon, and bone health and has implications in the development of RCTs [23]. In a matched-cohort study of more than 330,000 patients sourced from a large insurance claims database, Albright et al. [34] showed that patients diagnosed with a full-thickness RCT were more likely to have had a vitamin D deficiency diagnosis in the prior 2 years (odds ratio [OR], 2.36). This effect was magnified in women between the ages of 70 and 89 years and diminished in men 30-49 years old [34]. In osteoporotic patients, Liu et al. [35] found that low serum vitamin D was an independent risk factor for RCT.

In RCT patients, the prevalence of insufficient (20-29 ng/mL) or deficient (< 20 ng/mL) serum vitamin D has been reported. In a retrospective study of RCR patients by Wilde et al. [36], 36% were identified as having insufficient or deficient serum vitamin D; and Lee et al. [5] reported a low serum vitamin D level in 71% of their RCT patients. In their study of 36 RCT patients undergoing RCR, Rhee et al. [4] reported that only 8.3% of patients had a sufficient vitamin D level.

### Radiographic and Histologic Features

The effect of preoperative vitamin D level on radiographic features of RCTs has been investigated in several studies, with mixed results. Rhee et al. [4] performed a study of 36 patients undergoing RCR, revealing no discernable connection between preoperative serum vitamin D level and tear size, degree of retraction, or Goutallier grade of fatty atrophy of the rotator cuff. These findings are consistent with the results of Ryu et al. [37] and Chen et

**Table 1.** Summary of the studies assessing the impact of hypovitaminosis D on the rotator cuff

| Study                       | Cohort  | Findings   |
|-----------------------------|---|--|
| Albright et al. (2023) [34] | Population: 672, 640 (336,320 vitamin D deficient) patients undergoing RCR matched patients with vitamin D deficiency<br>Source: PearlDiver Humana database | <ul style="list-style-type: none"> <li>· Vitamin D deficiency risk factor for full-thickness RCT (OR, 2.36; 95% CI, 2.17–2.56). Greatest effect in women aged 70–89 (OR, 2.93) and lowest in men between 30 and 49 (OR, 1.87)</li> <li>· Women with RCT and vitamin D deficiency more likely to undergo RCR (OR, 1.37; 95% CI, 1.09–1.74), no difference for male RCT patients with or without vitamin D deficiency</li> <li>· Stiffness requiring MUA more likely in vitamin D deficient RCR patients (OR, 1.14; 95% CI, 1.03–1.27)</li> <li>· Similar rates of revision, I&amp;D for vitamin D deficiency patients (P &gt; 0.05).</li> </ul>   |
| Kim et al. (2023) [23]      | 68 patients (12 vitamin D deficient) undergoing RCR for medium (1–3 cm) full-thickness RCT.<br>Source: single institution retrospective study               | <p>Gene expression</p> <ul style="list-style-type: none"> <li>· In vitamin D deficient RCR patients, deltoid <i>VDR</i> expression lower (0.16 vs. 0.34, P &lt; 0.05), <i>myoD</i> expression lower (1.09 vs. 2.84, P &lt; 0.05), atrogen expression higher (1.05 vs. 0.23 P &lt; 0.05).</li> <li>· No difference in muscle-atrophy or adipogenic gene expression within supraspinatus tissue samples between vitamin D deficient versus sufficient cohorts.</li> <li>· Inflammation-related genes <i>IL-1B</i>, <i>IL-6</i> expressed more in vitamin D deficient patients' deltoid and supraspinatus</li> <li>· No difference in MMP-9, COL1A1, COL3A1, p53, TNF-α gene expression</li> </ul> <p>Protein expression</p> <ul style="list-style-type: none"> <li>· In deltoids of vitamin D deficient patients, protein expression of atrogen and IL-6 increased (P &lt; 0.05). In the supraspinatus, only IL-6 expression increased with vitamin D deficiency (P &lt; 0.05).</li> <li>· Proinflammatory proteins upregulated in vitamin D deficient patients (P &lt; 0.05).</li> <li>· Vitamin D deficiency led to expression of muscle atrophy-related proteins in the deltoid (P &lt; 0.05), but not the rotator cuff (P &gt; 0.05).</li> </ul> |
| Wilde et al. (2023) [36]    | 135 Patients (34 with low vitamin D) undergoing RCR<br>Source: single institution retrospective study   | <ul style="list-style-type: none"> <li>· 36% of included RCR patients had low vitamin D.</li> </ul>  |
| Rhee et al. (2023) [4]      | 36 Patients undergoing RCR for full-thickness, small to massive RCTs<br>Source: single institution prospective study  | <ul style="list-style-type: none"> <li>· 91.7% (33/36) insufficient or deficient vitamin D</li> <li>· Lower serum and tissue vitamin D correlated with preoperative and 1-year postoperative abduction strength (P &lt; 0.05).</li> <li>· Tissue vitamin D correlate with preoperative, but not postoperative VAS pain, ASES, Constant scores (all P &lt; 0.05).</li> <li>· Vitamin D had no relationship with fatty degeneration of the rotator cuff, tear size, retraction (P &gt; 0.05).</li> <li>· Muscle fiber cross-sectional area significantly related to tissue, but not serum vitamin D levels (P &lt; 0.05).</li> </ul>   |
| Liu et al. (2022) [35]      | 104 Full-thickness RCT patients (72 with osteoporosis) undergoing RCR. Excluded obese patients.<br>Source: single institution prospective study             | <ul style="list-style-type: none"> <li>· Vitamin D3 was significantly lower in RCT-OP (16.7 ng/mL) group compared to RCT only (19.6 ng/mL) (P &lt; 0.05).</li> <li>· Vitamin D predictive of RCT in osteoporotic patients (P &lt; 0.05).</li> </ul>  |
| Lee et al. (2021) [5]       | 176 Patients (78 with low vitamin D) undergoing RCR for full-thickness RCT.<br>Source: single institution retrospective study                               | <ul style="list-style-type: none"> <li>· 71% of vitamin D insufficient or deficient</li> <li>· Prevalence of low vitamin D decreased with age (P &lt; 0.05). More likely in indoor workers (36.2 vs. 48.3%, P = 0.001)</li> <li>· No relationship between sex, smoking status, alcohol consumption and low vitamin D</li> </ul>  |

RCR: rotator cuff repair, RCT: rotator cuff tear, OR: odds ratio, CI: confidence interval, MUA: manipulation under anesthesia, I&D: irrigation and debridement; IL: interleukin; VAS: visual analog scale; ASES: American Shoulder and Elbow Surgeons; RCT-OP: RCT-osteoporosis.

al. [4,38]. These findings are, however, inconsistent with those of Oh et al. [13], who reported significant correlations between lower serum vitamin D level and greater fatty atrophy of the supraspinatus and infraspinatus but not of the subscapularis. Histologically, Rhee et al. [4] demonstrated that, although serum vitamin D level appears to have no effect, tissue vitamin D level correlates significantly with individual muscle fiber cross-sectional area.

### **Clinical Presentation: Physical Exam & Preoperative Function Scores**

Several studies have addressed the impact of vitamin D level on the clinical symptoms of RCTs. In the study conducted by Rhee et al. [4], serum vitamin D level did not correlate with preoperative functional scores; however, the vitamin D level in tissue from supraspinatus biopsies correlated directly with preoperative American Shoulder and Elbow Surgeons (ASES) and Constant scores and inversely with preoperative pain visual analog scale score.

Serum vitamin D level may influence preoperative rotator cuff strength in RCT patients. Oh et al. [13] observed that lower serum vitamin D levels were associated with significantly reduced force generation in both abduction and external rotation. These findings partially align with those of Rhee et al. [4], who also found decreased shoulder abduction strength with lower serum and tissue vitamin D levels. However, they found that tissue vitamin D level impacted internal rotation strength rather than external rotation strength [4].

Vitamin D plays a significant role in muscle, tendon, and bone health, influencing the development and severity of RCTs. Vitamin D deficiency is prevalent among patients with RCT. While preoperative serum vitamin D level does not consistently correlate with radiographic features of RCTs, these levels do affect clinical symptoms and muscle strength. Lower serum vitamin D level is linked to reduced shoulder strength and worse preoperative functional scores, and tissue vitamin D level specifically correlates with muscle fiber area and functional scores.

### **HYPOVITAMINOSIS D AND RCR (Table 2)**

The impacts of hypovitaminosis D and RCR in the clinical setting remain controversial. Angeline et al. [12] demonstrated in rat models that diet-induced vitamin D deficiency affected the early period of healing after RCR, resulting in decreased strength at 2 weeks. This deficiency resulted in reduced formation of fibrocartilage and inferior collagen organization. However, strength was normal four weeks postoperatively despite the persistence of histological abnormalities [12]. As for hypovitaminosis D in humans, Harada et al. [39] studied data from patients in

a national claims database and reported that vitamin D deficiency was associated with a higher risk of revision RCR and postoperative stiffness requiring manipulation under anesthesia. Revision surgery was explained to be the result of disrupted healing [39]. However, postoperative stiffness was due to the upregulation of inflammatory cytokines leading to myofibroblast-induced capsular hyperplasia and fibrosis, highlighting the role of vitamin D in inflammatory regulation and myofibroblast activity inhibition [43,44]. Other studies reported similar findings in regard to the increased rate of RCR revision [38,40,41]. Cancienne et al. [40] showed that the difference in the absolute rate of revision RCR was minimal between the two groups and was unlikely to be clinically impactful. In addition, Chen et al. [38] showed that vitamin D deficiency was associated with a higher pain level in the early postoperative period after RCR. Pain was negatively correlated with vitamin D level at 1 and 3 months but not at 6 and 12 months postoperatively [42]. This was explained by the impact of vitamin D on the reduction of cytokines and prostaglandins as well as on T-cell responses [45-49]. Furthermore, Chen et al. [42] showed a statistically significant difference in the Sugaya re-tear grade depending on the presence or absence of vitamin D deficiency. This conclusion was justified by the effect of vitamin D on the healing structure of the rotator cuff after RCR. Another important finding was the correlation between serum vitamin D level and tissue vitamin D level [4]. Deficiency in both reduced the strength in abduction, but only a low tissue vitamin D level affected external rotation strength [4]. Moreover, the muscle fiber cross-sectional area, which affected muscle strength, was lower in patients with low vitamin D level in the tissue but did not correlate with vitamin D level in the serum. This suggests that vitamin D level in the tissue is more reflective of the impact of vitamin D in the rotator cuff than is the serum level [4].

However, vitamin D deficiency did not affect any of the clinical outcome scores such as the University of California Los Angeles (UCLA) score, ASES score, and the Constant-Murley score [38,42]. Chen et al. [42] reported no impact of vitamin D deficiency on the re-tear rate after RCR. This was in agreement with the findings of both Ryu et al. [37] and Rhee et al. [4].

Nevertheless, in a cost-effect analysis study, Patel et al. [50] analyzed the cost-effectiveness of pre-operative vitamin D supplementation and reported that non-selective vitamin D supplementation resulted in a mean cost savings of \$11,584,742, which was higher than selective vitamin D supplementation (\$6,099,341). Therefore, vitamin D supplementation without prior screening is recommended prior to RCR regardless of deficiency.

**Table 2.** Summary of the studies assessing the impact of hypovitaminosis D on the outcomes of rotator cuff repair

| Study                        | Cohort   | Main findings  |
|------------------------------|--|--|
| Angeline et al. (2014) [12]  | Vitamin D deficiency was induced in 28 rats undergoing rotator cuff repair.  | <ul style="list-style-type: none"> <li>· Low vitamin D levels affect the early healing after rotator cuff repair, affecting the strength at 2 weeks postoperatively.</li> <li>· The strength was back to normal at 4 weeks postoperatively despite the histological abnormalities being still present.</li> </ul>  |
| Harada et al. (2019) [39]    | National Claims Database<br>229 Patients with low levels of vitamin D and 1,652 patients with normal levels undergoing rotator cuff repair   | <ul style="list-style-type: none"> <li>· A higher rate of postoperative rotator cuff repair revision (<math>P &lt; 0.001</math>) and manipulation under anesthesia for stiffness (<math>P = 0.035</math>) was seen in the vitamin D deficient cohort.</li> </ul>   |
| Cancienne et al. (2019) [40] | PearlDiver database<br>199 Patients had vitamin D deficiency, 322 had vitamin D insufficiency, and 541 did not have low levels of Vitamin D.<br>All of the patients underwent rotator cuff repair. | <ul style="list-style-type: none"> <li>· A higher rate of postoperative rotator cuff repair revision was seen when the normal and deficient group were compared (<math>P = 0.007</math>).</li> </ul>   |
| O'Donnell et al. (2020) [41] | PearlDiver database<br>41,467 Patients underwent rotator cuff repair<br>3,072 underwent revision rotator cuff repair   | <ul style="list-style-type: none"> <li>· Vitamin D deficiency (OR, 1.18; <math>P &lt; 0.001</math>; 95% CI, 1.08–1.28) was shown to increase the risk of revision rotator cuff repair significantly.</li> </ul>  |
| Chen et al. (2022) [38]      | 45 Vitamin D deficient patients and 44 patients with normal levels of vitamin D  | <ul style="list-style-type: none"> <li>· Vitamin D deficiency is not correlated with clinical function scores.</li> <li>· Vitamin D deficiency is associated with the early postoperative pain (<math>P &lt; 0.05</math>) and a higher retear rate (<math>P &lt; 0.05</math>).</li> </ul>  |
| Chen et al. (2022) [42]      | 62 Vitamin D deficient patients and 60 patients with normal levels of vitamin D  | <ul style="list-style-type: none"> <li>· Vitamin D deficiency is not correlated with clinical function scores or retear rate.</li> <li>· Vitamin D deficiency is associated with the early postoperative pain (<math>P &lt; 0.05</math>) and the quality of rotator cuff healing after surgery (<math>P = 0.007</math>).</li> </ul>  |
| Ryu et al. (2015) [37]       | 80 Vitamin D deficient patients, 8 patients with vitamin D insufficiency, and 3 patients with normal levels of vitamin D   | <ul style="list-style-type: none"> <li>· Vitamin D deficiency had no significant impact on postoperative structural integrity and functional outcomes after arthroscopic rotator cuff repair.</li> </ul>   |
| Rhee et al. (2023) [4]       | -  | <ul style="list-style-type: none"> <li>· Lower serum vitamin D levels at 1 year after surgery weakened abduction power while tissue level of vitamin D affected both external rotation and abduction power.</li> <li>· Muscle fiber cross sectional area was lower in the patients with low tissue vitamin D levels but did not correlate with serum vitamin D levels.</li> <li>· Vitamin D levels did not correlate with rotator cuff repair failure</li> </ul> |

OR: odds ratio, CI: confidence interval.

### HYPOVITAMINOSIS D AND TSA (Table 3)

High rates of vitamin D deficiency have been reported in patients undergoing TSA. In a retrospective review of 218 TSA patients, Inkrott et al. [2] found that 43% had vitamin D insufficiency ( $< 30$  ng/mL) and 11% were deficient ( $< 20$  ng/mL). Identifying and addressing vitamin D deficiency through supplementation of vitamin D and calcium could allow preoperative optimization of bone mineral density (BMD) given the association of decreased BMD with acromial stress fractures after reverse shoulder arthroplasty [51]. Currently, no studies have specifically examined the impact of vitamin D level on the incidence of stress fractures following reverse shoulder arthroplasty.

Hypovitaminosis D has been associated with increased risk of revision shoulder arthroplasty. In a retrospective cohort study

using the PearlDiver database, Smith et al. [3] compared 1,644 TSA patients diagnosed with vitamin D deficiency to 5,022 matched controls. After adjusting for anti-osteoporotic medication prescriptions and osteoporosis diagnoses, the researchers found a significantly higher rate of revision arthroplasty in the vitamin D-deficient group (2.3% vs. 0.8%; OR, 3.3;  $P < 0.001$ ). However, the group was unable to determine the reason for the increased revision rates as there were no significant differences in the rates of implant loosening, periprosthetic fracture, or periprosthetic infection [3]. One potential explanation is a higher rate of secondary rotator cuff insufficiency, which is among the three most common complications of TSA requiring revision [52]. In a retrospective study of 518 TSA patients, Young et al. [53] found that preoperative infraspinatus fatty infiltration was correlated with secondary rotator cuff insufficiency. Considering

**Table 3.** Studies reporting on vitamin D and total shoulder arthroplasty

| Study                     | Cohort   | Findings  |
|---------------------------|--|---|
| Maier et al. (2014) [54]  | Single institution in Germany: 190 patients (109 primary arthroplasty, 50 PJI, 31 aseptic loosening) <sup>a)</sup> | All patient subgroups showed low 25(OH)D levels (<20 ng/mL) PJI (13.29 ± 6.54 ng/mL) patients had lower 25(OH)D levels compared to primary arthroplasty (19.46 ± 9.49 ng/mL, P < 0.001) and aseptic loosening (20.52 ± 9.13 ng/mL, P < 0.001).  |
| Inkrott et al. (2016) [2] | Single institution in USA: 286 patients (2 HA, 52 aTSA, 164 rTSA)  | 93 (43%) 25(OH)D insufficient<br>24 (11%) 25(OH)D deficient<br>BMI > 30 kg/m <sup>2</sup> correlates with lower 25(OH)D levels (31.5 ± 12.1 vs. 36.2 ± 15.7 ng/mL, P < 0.01).<br>Absence vitamin D and calcium supplementation was most significant risk factor for hypovitaminosis D (OR, 8.234; P < 0.001). |
| Smith et al. (2021) [3]   | PearlDiver database: 6,696 TSA patients (1,674 25(OH)D deficient, 5,022 age, sex, osteoporosis matched controls)   | Higher rate of revision arthroplasty in 25(OH)D deficient compared to controls (2.3% vs. 0.8%; OR, 3.3; P < 0.0001)<br>Higher risk UTI compared to controls (OR, 1.31; P = 0.003)   |

PJI: prosthetic joint infection, 25(OH)D: 25-hydroxyvitamin D, HA: hemiarthroplasty, aTSA: anatomic total shoulder arthroplasty, rTSA: reverse total shoulder arthroplasty, BMI: body mass index, OR: odds ratio, UTI: urinary tract infection.

<sup>a)</sup>Number of total shoulder arthroplasty, total knee arthroplasty, and total hip arthroplasty patients was not specified.

that low vitamin D level has been identified as an independent predictor of fatty infiltration of rotator cuff muscles in animal studies [13], secondary rotator cuff insufficiency may be an explanation for the significantly higher revision rate in the vitamin D-deficient group. However, the underlying causes of the increased revision rate remain unclear and underscore the need for further research on the impact of vitamin D levels and TSA outcomes.

Vitamin D modulates innate and adaptive immune cell function, suggesting a role in PJI. In a retrospective study of 109 joint arthroplasty (hip, knee, shoulder) patients, Maier et al. [54] found that PJI patients had significantly lower levels of 25-hydroxyvitamin D compared to those undergoing primary arthroplasty or those presenting with aseptic loosening. The most commonly isolated bacterium in PJI of shoulder arthroplasties is the indolent low virulence *Cutibacterium acnes* [55,56]. However, there were no reported cases of *C. acnes* infection in the study by Maier et al. [54], with most TSA infections due to *Staphylococcus aureus*, which limits the generalizability of these findings. In their retrospective PearlDiver study, Smith et al. [3] found no association between PJI and vitamin D deficiency; however, these researchers did find higher rates of urinary tract infections (OR, 1.31; P = 0.003) in vitamin D-deficient patients. However, their study was based on PearlDiver, and the PJI diagnosis relied upon accurate coding within the utilized database using International Classification of Diseases, 9th Revision (ICD-9) and 10th Revision (ICD-10) codes. This decreased the reliability of their findings. In addition, the preponderance of research evaluating the relationship between vitamin D level and PJI in TSA patients has inconclusive findings. This highlights the need for further studies

with more rigorous methodologies focusing on isolated cohorts of TSA patients to better understand and clarify this association.

## MANAGEMENT OF VITAMIN D DEFICIENCY

Serum calcium and 25-hydroxyvitamin D levels should be assessed in the laboratory. PTH level assessment to rule out secondary hyperparathyroidism is also indicated [57]. With a half-life of 2 to 3 weeks, 25-hydroxyvitamin D is the recommended clinical indicator of vitamin D deficiency. Finding more underlying metabolic problems may be aided, if appropriate, by a referral to a metabolic bone specialist [57]. As for oral vitamin D supplementation in the context of hypovitaminosis D, there is no established protocol [57]. The majority of randomized and observational studies has recommended 400–1,000 IU of vitamin D daily [57]. Daily doses of supplementation are thought to be preferable to massive annual dosages, and vitamin D3 is more effective than vitamin D2 in sustaining levels over time [57]. Considering the lack of consensus regarding the ideal therapeutic dosage and the infrequency of vitamin D toxicity, a target 25-hydroxyvitamin D level of 30–40 ng/mL is often advised [57]. However, new recommendations from Osteoporosis Canada and the International Osteoporosis Foundation suggest a treatment threshold determined by PTH response to vitamin D levels less than 30 ng/mL [57].

## CONCLUSION

Hypovitaminosis D may have several implications in the patho-

physiology and treatment of shoulder pathologies. Vitamin D has various physiological effects involved in modulating tissue healing, bone growth, and maintenance of homeostasis in skeletal muscle cells. Vitamin D also has anti-inflammatory effects that are important to rotator cuff health. Vitamin D deficiency is highly prevalent in patients with RCTs, suggesting its role as a potential risk factor. In addition to impacting preoperative shoulder strength, vitamin D deficiency may increase re-tear rates, postoperative stiffness, and the need for revision surgery in patients who underwent RCR. A potential association between vitamin D deficiency and increased risk of revision TSA has been demonstrated, but the reason for this finding is unclear. Further research on optimal vitamin D deficiency management in such patients is warranted to optimize postoperative outcomes of TSA and RCR.

## NOTES

### ORCID

Mohammad Daher <https://orcid.org/0000-0002-9256-9952>  
 Ryan Lopez <https://orcid.org/0000-0002-5757-1782>  
 Mohamad Y. Fares <https://orcid.org/0000-0001-8228-3953>  
 Joseph A. Abboud <https://orcid.org/0000-0002-3845-7220>

### Author contributions

Writing – original draft: MD, OC, RL, PB, MCRH, ZZ, MYF.  
 Writing – review & editing: JAA.

### Conflict of interest

JAA would like to disclose royalties from DJO Global, Zimmer-Biomet, Smith and Nephew, Stryker, Globus Medical, Inc.; research support as a PI from: Lima Corporation - Italy, Orthofix, Arthrex, OREF; royalties, financial or material support from Wolters Kluwer; and board member/committee appointments for American Shoulder and Elbow Society, Pacira.

### Funding

None.

### Data availability

Contact the corresponding author for data availability.

### Acknowledgments

None.

## REFERENCES

1. Veldurthy V, Wei R, Oz L, Dhawan P, Jeon YH, Christakos S. Vitamin D, calcium homeostasis and aging. *Bone Res* 2016; 4:16041.
2. Inkrott BP, Koberling JL, Noel CR. Hypovitaminosis D in patients undergoing shoulder arthroplasty: a single-center analysis. *Orthopedics* 2016;39:e651–6.
3. Smith JM, Cancienne JM, Brockmeier SF, Werner BC. Vitamin D deficiency and total shoulder arthroplasty complications. *Shoulder Elbow* 2021;13:99–105.
4. Rhee SM, Park JH, Jeong HJ, Kim YK, Lee K, Oh JH. Serum vitamin D level correlations with tissue vitamin D level and muscle performance before and after rotator cuff repair. *Am J Sports Med* 2023;51:723–32.
5. Lee JH, Kim JY, Kim JY, Mun JW, Yeo JH. Prevalence of and risk factors for hypovitaminosis D in patients with rotator cuff tears. *Clin Orthop Surg* 2021;13:237–42.
6. Hegde V, Arshi A, Wang C, et al. Preoperative vitamin D deficiency is associated with higher postoperative complication rates in total knee arthroplasty. *Orthopedics* 2018;41:e489–95.
7. Lee A, Chan SK, Samy W, Chiu CH, Gin T. Effect of hypovitaminosis D on postoperative pain outcomes and short-term health-related quality of life after knee arthroplasty: a cohort study. *Medicine (Baltimore)* 2015;94:e1812.
8. Lavernia CJ, Villa JM, Iacobelli DA, Rossi MD. Vitamin D insufficiency in patients with THA: prevalence and effects on outcome. *Clin Orthop Relat Res* 2014;472:681–6.
9. Traven SA, Chiaramonti AM, Barfield WR, et al. Fewer complications following revision hip and knee arthroplasty in patients with normal vitamin D levels. *J Arthroplasty* 2017;32:S193–6.
10. Daher M, Zalaquett Z, Fares MY, Boufadel P, Khanna A, Abboud JA. Osteoporosis in the setting of rotator cuff repair: a narrative review. *Shoulder Elb* 2023 Oct 17 [Epub]. Available from: <https://journals.sagepub.com/doi/10.1177/17585732231207338>
11. Daher M, Fares MY, Boufadel P, Khanna A, Zalaquett Z, Abboud JA. Osteoporosis in the setting of shoulder arthroplasty: a narrative review. *Geriatr Orthop Surg Rehabil* 2023;14:21514593 231182527.
12. Angeline ME, Ma R, Pascual-Garrido C, et al. Effect of diet-induced vitamin D deficiency on rotator cuff healing in a rat model. *Am J Sports Med* 2014;42:27–34.
13. Oh JH, Kim SH, Kim JH, Shin YH, Yoon JP, Oh CH. The level of vitamin D in the serum correlates with fatty degeneration of the muscles of the rotator cuff. *J Bone Joint Surg Br* 2009;91:1587–93.



14. Bouillon R, Manousaki D, Rosen C, Trajanoska K, Rivadeneira F, Richards JB. The health effects of vitamin D supplementation: evidence from human studies. *Nat Rev Endocrinol* 2022;18:96–110.
15. Galatz LM, Sandell LJ, Rothermich SY, et al. Characteristics of the rat supraspinatus tendon during tendon-to-bone healing after acute injury. *J Orthop Res* 2006;24:541–50.
16. Wei AS, Callaci JJ, Juknelis D, et al. The effect of corticosteroid on collagen expression in injured rotator cuff tendon. *J Bone Joint Surg Am* 2006;88:1331–8.
17. Yoshihara Y, Hamada K, Nakajima T, Fujikawa K, Fukuda H. Biochemical markers in the synovial fluid of glenohumeral joints from patients with rotator cuff tear. *J Orthop Res* 2001;19:573–9.
18. Gotoh M, Hamada K, Yamakawa H, Tomonaga A, Inoue A, Fukuda H. Significance of granulation tissue in torn supraspinatus insertions: an immunohistochemical study with antibodies against interleukin-1 beta, cathepsin D, and matrix metalloproteinase-1. *J Orthop Res* 1997;15:33–9.
19. Lo IK, Marchuk LL, Hollinshead R, Hart DA, Frank CB. Matrix metalloproteinase and tissue inhibitor of matrix metalloproteinase mRNA levels are specifically altered in torn rotator cuff tendons. *Am J Sports Med* 2004;32:1223–9.
20. Robertson CM, Chen CT, Shindle MK, Cordasco FA, Rodeo SA, Warren RF. Failed healing of rotator cuff repair correlates with altered collagenase and gelatinase in supraspinatus and subscapularis tendons. *Am J Sports Med* 2012;40:1993–2001.
21. Edwards SL, Lynch TS, Saltzman MD, Terry MA, Nuber GW. Biologic and pharmacologic augmentation of rotator cuff repairs. *J Am Acad Orthop Surg* 2011;19:583–9.
22. Bahar-Shany K, Ravid A, Koren R. Upregulation of MMP-9 production by TNFalpha in keratinocytes and its attenuation by vitamin D. *J Cell Physiol* 2010;222:729–37.
23. Kim HT, Lee SH, Lee JK, Chung SW. Influence of vitamin D deficiency on the expression of genes and proteins in patients with medium rotator cuff tears. *Am J Sports Med* 2023;51:2650–8.
24. Laird E, McNulty H, Ward M, et al. Vitamin D deficiency is associated with inflammation in older Irish adults. *J Clin Endocrinol Metab* 2014;99:1807–15.
25. Dzik KP, Skrobot W, Kaczor KB, et al. Vitamin D deficiency is associated with muscle atrophy and reduced mitochondrial function in patients with chronic low back pain. *Oxid Med Cell Longev* 2019;2019:6835341.
26. Sirbe C, Rednic S, Grama A, Pop TL. An update on the effects of vitamin D on the immune system and autoimmune diseases. *Int J Mol Sci* 2022;23:9784.
27. Ao T, Kikuta J, Ishii M. The effects of vitamin D on immune system and inflammatory diseases. *Biomolecules* 2021;11:1624.
28. Hedström M, Sjöberg K, Brosjö E, Aström K, Sjöberg H, Dalén N. Positive effects of anabolic steroids, vitamin D and calcium on muscle mass, bone mineral density and clinical function after a hip fracture. a randomised study of 63 women. *J Bone Joint Surg Br* 2002;84:497–503.
29. Zhu K, Austin N, Devine A, Bruce D, Prince RL. A randomized controlled trial of the effects of vitamin D on muscle strength and mobility in older women with vitamin D insufficiency. *J Am Geriatr Soc* 2010;58:2063–8.
30. Bollen SE, Atherton PJ. Myogenic, genomic and non-genomic influences of the vitamin D axis in skeletal muscle. *Cell Biochem Funct* 2021;39:48–59.
31. Bang WS, Lee DH, Kim KT, et al. Relationships between vitamin D and paraspinal muscle: human data and experimental rat model analysis. *Spine J* 2018;18:1053–61.
32. Bass JJ, Kazi AA, Deane CS, et al. The mechanisms of skeletal muscle atrophy in response to transient knockdown of the vitamin D receptor in vivo. *J Physiol* 2021;599:963–79.
33. Dzik KP, Kaczor JJ. Mechanisms of vitamin D on skeletal muscle function: oxidative stress, energy metabolism and anabolic state. *Eur J Appl Physiol* 2019;119:825–39.
34. Albright JA, Testa EJ, Byrne RA, Portnoff B, Daniels AH, Owens BD. Significant association between a diagnosis of hypovitaminosis d and rotator cuff tear, independent of age and sex: a retrospective database study. *Med Sci Sports Exerc* 2024;56:446–53.
35. Liu G, Li W, Zhang L, Zhou C, Cong R. The role of vitamin D on rotator cuff tear with osteoporosis. *Front Endocrinol (Lausanne)* 2022;13:1017835.
36. Wilde B, Hotaling JM, Ishikawa H, Joyce C, Tashjian R, Chalmers PN. Abnormal laboratory values for metabolic and hormonal syndromes are prevalent among patients undergoing rotator cuff repair. *Arthrosc Sports Med Rehabil* 2023;5:e695–701.
37. Ryu KJ, Kim BH, Lee Y, Dan J, Kim JH. Low serum vitamin D is not correlated with the severity of a rotator cuff tear or retear after arthroscopic repair. *Am J Sports Med* 2015;43:1743–50.
38. Chen J, Lou J, Wang W, Xu G. Association of preoperative vitamin D deficiency with retear rate and early pain after arthroscopic rotator cuff repair: a retrospective cohort study. *Orthop J Sports Med* 2022;10:23259671221130315.
39. Harada GK, Arshi A, Fretes N, et al. Preoperative vitamin D deficiency is associated with higher postoperative complications in arthroscopic rotator cuff repair. *J Am Acad Orthop Surg Glob Res Rev* 2019;3:e075.

40. Cancienne JM, Brockmeier SF, Kew ME, Werner BC. Perioperative serum 25-hydroxyvitamin D levels affect revision surgery rates after arthroscopic rotator cuff repair. *Arthroscopy* 2019; 35:763–9.
41. O'Donnell EA, Fu MC, White AE, et al. The effect of patient characteristics and comorbidities on the rate of revision rotator cuff repair. *Arthroscopy* 2020;36:2380–8.
42. Chen J, Lou YX, Xu GH, Wang WK. Study on correlation between serum vitamin D level and the curative effect after repair of rotator cuff tears. *Zhongguo Gu Shang* 2022;35:225–32.
43. Zerr P, Vollath S, Palumbo-Zerr K, et al. Vitamin D receptor regulates TGF- $\beta$  signalling in systemic sclerosis. *Ann Rheum Dis* 2015;74:e20.
44. Lee SA, Yang HW, Um JY, Shin JM, Park IH, Lee HM. Vitamin D attenuates myofibroblast differentiation and extracellular matrix accumulation in nasal polyp-derived fibroblasts through smad2/3 signaling pathway. *Sci Rep* 2017;7:7299.
45. Gendelman O, Itzhaki D, Makarov S, Bennun M, Amital H. A randomized double-blind placebo-controlled study adding high dose vitamin D to analgesic regimens in patients with musculoskeletal pain. *Lupus* 2015;24:483–9.
46. Grösch S, Niederberger E, Geisslinger G. Investigational drugs targeting the prostaglandin E2 signaling pathway for the treatment of inflammatory pain. *Expert Opin Investig Drugs* 2017; 26:51–61.
47. Habib AM, Nagi K, Thillaiappan NB, Sukumaran V, Akhtar S. Vitamin D and its potential interplay with pain signaling pathways. *Front Immunol* 2020;11:820.
48. Liu X, Nelson A, Wang X, et al. Vitamin D modulates prostaglandin E2 synthesis and degradation in human lung fibroblasts. *Am J Respir Cell Mol Biol* 2014;50:40–50.
49. Looker AC, Johnson CL, Lacher DA, Pfeiffer CM, Schleicher RL, Sempos CT. Vitamin D status: United States, 2001–2006. *NCHS Data Brief* 2011;59:1–8.
50. Patel D, Roy G, Endres N, Ziino C. Preoperative vitamin D supplementation is a cost-effective intervention in arthroscopic rotator cuff repair. *J Shoulder Elbow Surg* 2023;32:2473–82.
51. Lucasti CJ, Namdari S. Acromial stress fractures: a systematic review. *Arch Bone Jt Surg* 2019;7:397–401.
52. Ardebol J, Pak T, Kiliç Aİ, Hwang S, Menendez ME, Denard PJ. Secondary rotator cuff insufficiency after anatomic total shoulder arthroplasty. *JBJS Rev* 2023;11.
53. Young AA, Walch G, Pape G, Gohlke F, Favard L. Secondary rotator cuff dysfunction following total shoulder arthroplasty for primary glenohumeral osteoarthritis: results of a multicenter study with more than five years of follow-up. *J Bone Joint Surg Am* 2012;94:685–93.
54. Maier GS, Horas K, Seeger JB, Roth KE, Kurth AA, Maus U. Is there an association between periprosthetic joint infection and low vitamin D levels? *Int Orthop* 2014;38:1499–504.
55. Paxton ES, Green A, Krueger VS. Periprosthetic infections of the shoulder: diagnosis and management. *J Am Acad Orthop Surg* 2019;27:e935–44.
56. Contreras ES, Frantz TL, Bishop JY, Cvetanovich GL. Periprosthetic infection after reverse shoulder arthroplasty: a review. *Curr Rev Musculoskelet Med* 2020;13:757–68.
57. Patton CM, Powell AP, Patel AA. Vitamin D in orthopaedics. *J Am Acad Orthop Surg* 2012;20:123–9.