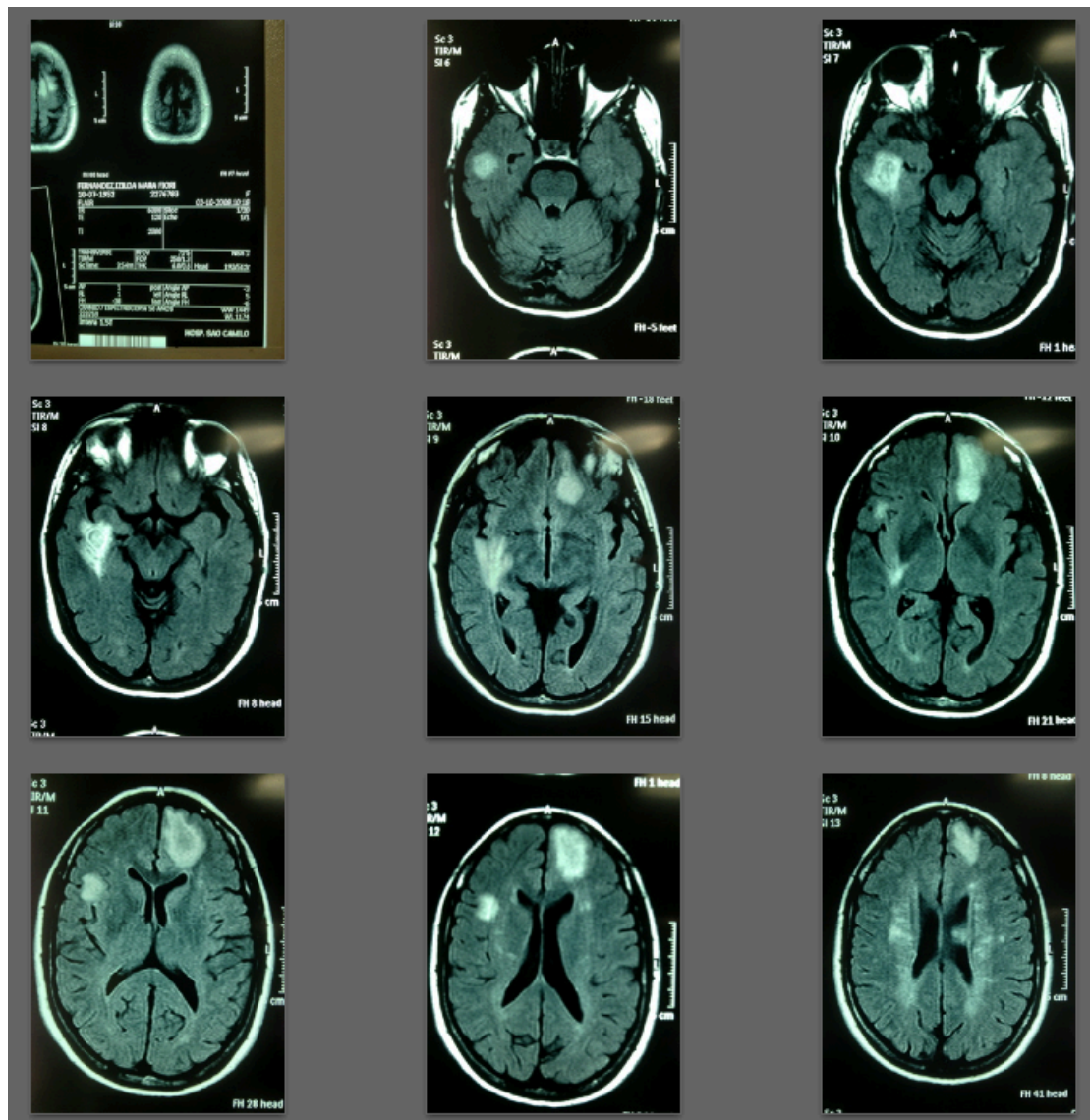


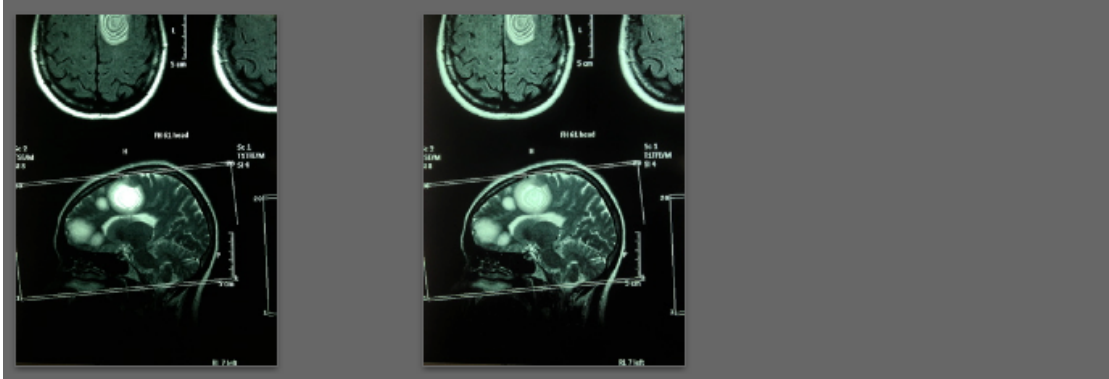
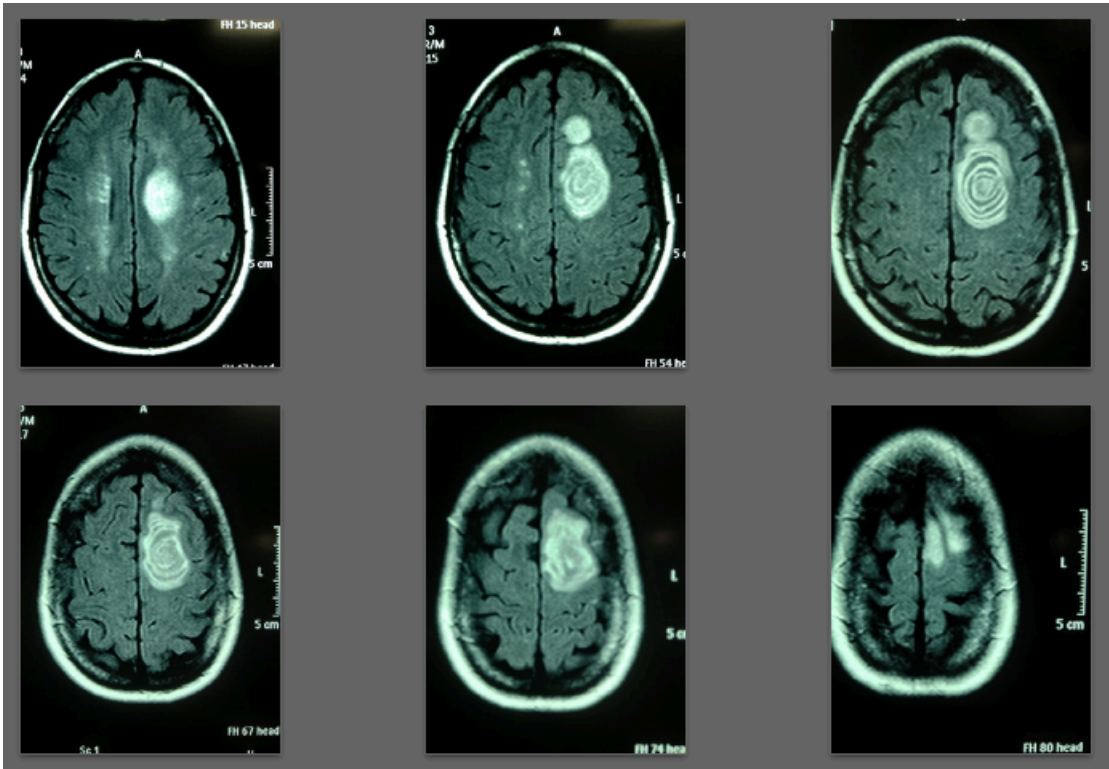
Patient: IMFF; female, DOB July 10, 1952; weigh 58 kg (128 lb), height 1.60 m (5.25 ft); engineer.

First symptoms (November, 2008): Convulsive seizures in August 20, 2008. Developed right hemiparesis, cognitive impairment, dysphasia and right-sided hemiparesis. Diagnosis: Balo's concentric hemiparesis.

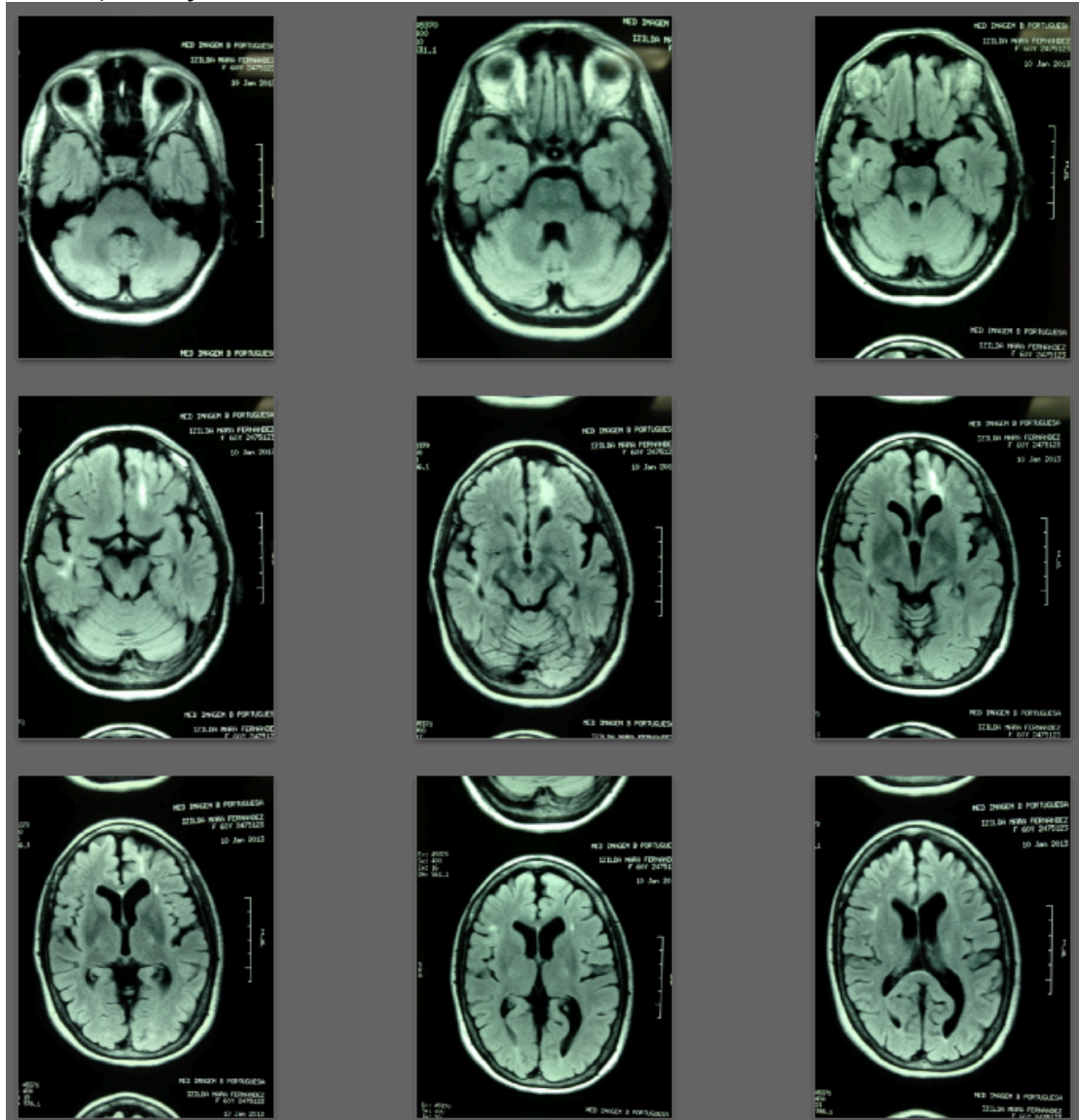
First appointment for therapy with high-dose vitamin D on December 12, 2008. Starting daily dose 25,000 IU; increased to 35,000 IU on October 22, 2009; increased to 40,000 IU in April, 2010; final increased to 80,000 IU on October 28, 2010. Asymptomatic since 2010.

MRI of October 2, 2008:





MRI of January 10, 2013





MRI of January 10, 2013

