

A Critical Review of the Classic Metaphyseal Lesion: Traumatic or Metabolic?

David M. Ayoub¹
 Charles Hyman²
 Marta Cohen³
 Marvin Miller⁴

OBJECTIVE. The purpose of this study was to review the hypothesis that classic metaphyseal lesions represent traumatic changes in abused infants and compare these lesions with healing rickets.

MATERIALS AND METHODS. Using a PubMed search, a multidisciplinary team reviewed studies that reported the histopathologic correlation of classic metaphyseal lesions. Selective studies of growth plate injury and rickets were cross-referenced.

RESULTS. Nine identified classic metaphyseal lesion studies were performed by the same principal investigator. Control subjects were inadequate. Details of abuse determination and metabolic bone disease exclusion were lacking. The presence of only a single radiology reviewer prevented establishment of interobserver variability. Microscopy was performed by two researchers who were not pathologists. Classic metaphyseal lesions have not been experimentally reproduced and are unrecognized in the accidental trauma literature. The proposed primary spongiosa location is inconsistent with the variable radiographic appearances. Classic metaphyseal lesions were not differentiated from tissue processing artifacts. Bleeding and callus were uncommon in spite of the vascular nature of the metaphysis. The conclusion that excessive hypertrophic chondrocytes secondary to vascular disruption were indicative of fracture healing contradicts the paucity of bleeding, callus, and periosteal reaction. Several similarities exist between classic metaphyseal lesions and healing rickets, including excessive hypertrophic chondrocytes. “Bucket-handle” and “corner fracture” classic metaphyseal lesions resemble healing rickets within the growth plate and the perichondrial ring, respectively. The age of presentation was more typical of bone fragility disorders, including rickets, than reported in prior child abuse series.

CONCLUSION. The hypothesis that classic metaphyseal lesions are secondary to child abuse is poorly supported. Their histologic and radiographic features are similar to healing infantile rickets. Until classic metaphyseal lesions are experimentally replicated and independently validated, their traumatic origin remains unsubstantiated.

Keywords: battered child syndrome, child abuse, classic metaphyseal lesion, hypertrophic chondrocytes, rickets

DOI:10.2214/AJR.13.10540

Received December 21, 2012; accepted after revision May 7, 2013.

¹Clinical Radiologists, SC, 1120 Williams Blvd, Springfield, IL 62704. Address correspondence to D. M. Ayoub (raypoke@me.com).

²Pediatrician, Redlands, CA.

³Histopathology Department, Sheffield Children’s Hospital NHS Foundation Trust, Western Bank, Sheffield, UK.

⁴Departments of Pediatrics, Obstetrics and Gynecology, and Biomedical Engineering, Wright State University Boonshoft School of Medicine, Dayton, OH.

AJR 2014; 202:185–196

0361–803X/14/2021–185

© American Roentgen Ray Society

The “classic metaphyseal lesion” is a term first used in 1986 by pediatric radiologist Paul Kleinman and colleagues [1] who hypothesized that they represented unique metaphyseal fractures in four young infants allegedly subjected to physical abuse. Kleinman et al. attributed their original description to John Caffey [2] who presented a small case series of infants with subdural hematomas and long bone fractures in 1946. In 1995, Kleinman et al. [3] further reported classic metaphyseal lesions among 31 deceased infants alleged to be victims of child abuse. In these 31 infants, the classic metaphyseal lesion accounted for 89% of all long bone fractures, and its recognition was the major determinant of skeletal

trauma. These metaphyseal abnormalities were identified from postmortem radiography and correlated with microscopy. The authors concluded the metaphyseal alterations represented partial or complete planar microfractures that transected the primary spongiosa adjacent to the growth plate. These microfractures usually resembled a “bucket-handle” or a “corner fracture,” depending on the angulation of the x-ray beam relative to the true long axis of the extremity. These injuries are in distinction to the well-recognized Salter-Harris type II injuries that are also commonly referred to as “corner” fractures.

Recent case series have reported the presence of infantile rickets in young infants being evaluated for unexplained fractures mim-

icking physical abuse [4, 5], a possibility acknowledged by Kleinman [6]. We have recently evaluated 63 infants with unexplained fractures in which child abuse was alleged and 67% exhibited classic metaphyseal lesion–like lesions (Miller ME et al., presented at the 2011 annual meeting of the Pediatric Academic Society). However, from clinical and radiographic findings, it was concluded that most of these lesions were not traumatic in origin but likely related to underlying metabolic bone disease, chiefly healing infantile rickets. This experience contradicted the assertion that classic metaphyseal lesions are highly specific for child abuse and prompted us to critically review the original classic metaphyseal lesion literature, particularly those seminal studies correlating histopathology with radiographic findings. We assess the strength of the hypothesis that classic metaphyseal lesions are traumatic in origin and emphasize potential similarities with rachitic growth plate changes.

Materials and Methods

We searched the National Library of Medicine through September 30, 2012. The terms and medical subject headings included were “classic metaphyseal lesion,” “battered child syndrome,” “metaphyseal fractures,” and “growth plate injury.” The citations within these articles were also examined for additional relevant references. We carefully selected studies that correlated radiology with histopathology to serve as the core basis for our analysis in addition to any clinical reports of classic metaphyseal lesions occurring from nonabusive injuries. Review articles were excluded from analysis.

We performed additional National Library of Medicine searches reviewing experimental and clinical studies that described the histopathology of growth plate trauma and the radiology and histopathology of rickets to compare these well-known conditions with the findings of the classic metaphyseal lesion.

Results

We found only nine studies in the peer-reviewed literature that had correlated histopathology with radiologically defined classic metaphyseal lesions in infants [1, 3, 7–13]. Studies that met our primary search criteria were published between 1986 and 1998 by the same principal investigator, pediatric radiologist Paul Kleinman at the University of Massachusetts, Worcester, in collaboration with the office of the chief medical examiner for the Commonwealth of Massachusetts and later at Boston Children’s Medical Center.

The largest classic metaphyseal lesion series evaluated 31 infants [3], and it appeared that subsets of this population served as the basis for additional articles evaluating regional classic metaphyseal lesions. Therefore, for purposes of analysis, all nine publications collectively served as the core classic metaphyseal lesion studies for critical review.

Study Design Limitations

The investigators did not appear to use an adequate control group, and therefore the prevalence of metaphyseal lesions in nonabused infants was not reported. Histologic assessment of radiographically defined metaphyseal abnormalities were compared with control subjects (nonabused infants) in only two of the nine studies but descriptions of the findings were either lacking or exceedingly limited in scope [1, 9]. The manner in which metabolic bone disease was excluded was not detailed. The infant selection criteria were vague. Medical history, clinical evidence, social service agency findings, and details of intracranial pathology were all unspecified. The evidence necessary to confirm child abuse was therefore not provided. Radiographic interpretation was performed by a single radiologist. Inter- and intraobserver variability were not reported. The evaluations of the microscopic materials were performed by a radiologist and a dentist with a PhD in biology [3]. It was not apparent that a credentialed pathologist had participated in any of the histologic analyses of classic metaphyseal lesions.

Lack of Replication and Confirmation Studies

To date, Kleinman and colleagues [1, 3, 7–13] are the only researchers who have performed histologic interpretation of radiologic classic metaphyseal lesions, but their findings have yet to be independently replicated in the peer-reviewed literature. They cited a solitary study by Ogden et al. [14] in which histologic validation of experimental classic metaphyseal lesions had allegedly been reported. Ogden and colleagues studied growth plate histology in stillborn cadavers and, according to Kleinman et al. [1], reported that “the plane of fracture extended through the primary spongiosa” and was “in contrast to the Salter-Harris pattern” of physeal injury.” This, however, appears to be a misrepresentation of the original work of Ogden et al. When those authors applied compression or traction forces to six human stillborn cadavers, “type I growth mechanism” injuries were

present in all subjects, the predominant plane of disruption occurring between hypertrophic chondrocytes and the primary spongiosa. Two cadavers also showed microscopic type IV fractures. These incursions, however, did not resemble the pattern of the transmetaphyseal planar injury of classic metaphyseal lesions. Others have similarly failed to experimentally produce complete transmetaphyseal injuries. Lee et al. [15] observed Salter-Harris type I through type IV injuries in 24 rabbit femurs subject to various directional shear stresses, but the fractures only occasionally extended into the trabeculae. Rudicel et al. [16] applied shear forces to 40 proximal femurs of rabbits but produced only one pure metaphyseal injury, the others being Salter-Harris types I; II; and, rarely, IV. When the metaphysis was involved, its portion was always quite small but increased in size with animal maturation, corresponding to increasing physis strength. Salter and Harris [17] also produced growth plate injuries by hyperextending the forepaws of rabbits, reporting remarkable constancy in the plane of cleavage through hypertrophic chondrocytes that only occasionally deviated into the corner metaphysis as a Salter-Harris type II injury.

Limited observations of acute trauma in human infants have failed to histologically confirm the existence of classic metaphyseal lesions. Ogden et al. [18] reviewed 57 cases of growth plate injuries in children (7 months to 13 years) but failed to observe any planar transmetaphyseal fractures. When injuries were predominately within the physis, extension into the metaphyseal trabeculae was variable and often microscopic. According to Rodriguez et al. [19], even in severe bone fragility disorders related to fetal neuromuscular disease, growth plate fractures among 11 neonates were of the Salter-Harris type I or type II variety, none conforming to planar fractures through the primary spongiosa.

Only three other case studies have reported radiologic classic metaphyseal lesion–like lesions among nonabused infants. Four infants suffered injuries shortly after cesarean delivery that reportedly resembled classic metaphyseal lesions [20, 21]. The radiographs depicted in these reports, however, did not resemble classic metaphyseal lesions but rather appeared to represent either epiphysiolysis, with or without prominent perichondrial rings (Fig. 1), or typical growth plate injuries. A third study by Grayev, et al. [22], described eight cases of abuse-like injuries after club-foot corrective maneuvers in infants ranging from 1 to

Imaging of Classic Metaphyseal Lesion

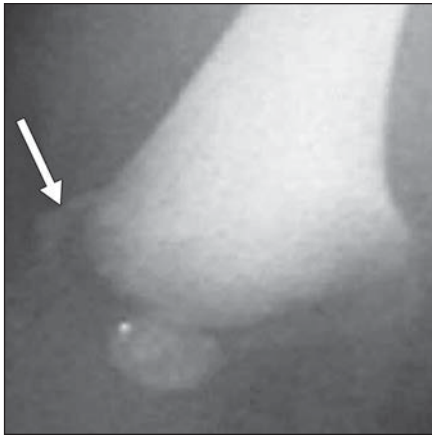
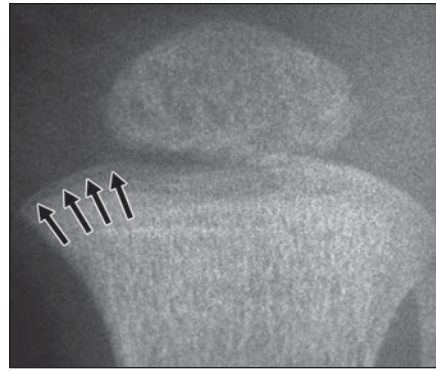


Fig. 1—Left leg was swollen at birth in 6-day-old girl born healthy and at term but radiograph on day 2 was normal. Misclassified classic metaphyseal lesion from birth trauma literature. Arrow was reported to highlight neonatal “bucket-handle” fracture of distal femur after cesarean delivery; however, ringlike structure is inconsistent with planar nature of classic metaphyseal lesion and more likely represents displaced perichondrial ring secondary to epiphyseal slippage. (Reprinted with permission from [21])

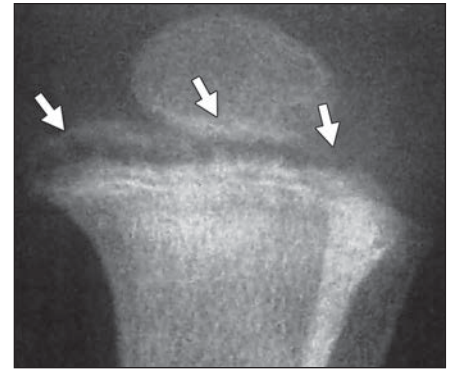
3.5 months old but only two mimicked classic metaphyseal lesions. However, these classic metaphyseal lesions were identified incidentally on serial radiographs and were clinically unrecognized at the time of the presumed causative orthopedic manipulation. A workup for bone fragility was not described. Although the authors confirmed that classic metaphyseal lesion–like lesions are rarely observed in a nonabuse setting, the study was not designed to prove traumatic origin nor was a relationship to bone fragility considered. Indeed, three of eight infants, including both infants with classic metaphyseal lesions, had neuromuscular impairment, a known risk factor for increased bone fragility.

Biomechanical Discrepancies

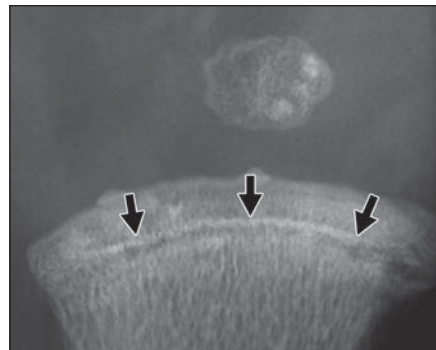
Because the proposed fracture plane of the classic metaphyseal lesion is parallel to the chondroosseous junction, the applied forces are likely in the same direction as the displacement. This implies that a distraction force from the epiphyseal side of the growth plate had been applied to the end of the long bone. The bucket handle classic metaphyseal lesion appears, however, to be inconsistent with the presupposed mechanism of “violent shaking as the infant is held by the trunk or extremities” [1] in which predominant shear and rotational stresses would be anticipated. It is also difficult to explain how the expected variable forces implied by a “shaking” mech-



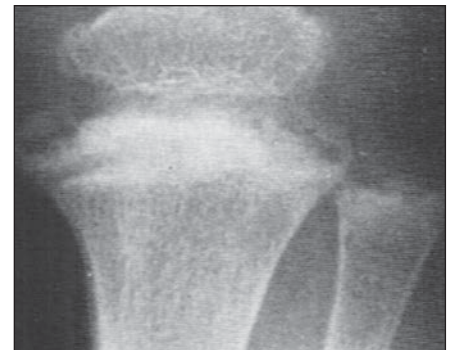A



B



C



D

Fig. 2—Variable appearance of fracture planes in classic metaphyseal lesions compared with healing rickets growth plate.

A–C, Highly variable appearance and depth of classic metaphyseal lesion fracture plane within proximal tibial metaphysis (arrows) of three different infants. (Reprinted with permission from [1] and [11])

D, Growth plate in healing rickets is remarkably similar to that of classic metaphyseal lesion shown in **B**. (Reprinted with permission from [40])

anism could produce a fracture that remained so consistently and strictly parallel to the chondroosseous junction without deviation into the epiphysis or metaphysis as typically occurs in other growth plate injuries.

Even though the thickness of the primary spongiosa varies in a relatively narrow range (1.95–2.35 mm) [23], the depth of the fracture plane as depicted radiographically in the classic metaphyseal lesion literature is highly variable and sometimes appears to extend considerably deeper into the metaphysis (Figs. 2A–2C). In addition, there is no known anatomic barrier that would inhibit propagation of the fracture beyond this narrow band of bone. This raises concern about the accuracy of the conclusion that classic metaphyseal lesions reside predominately within the primary spongiosa.

Histopathology Inconsistent With Trauma

The sequential histologic stages of fracture healing are well established and highly predictable but do not appear to have been systematically reported in the classic metaphyseal

lesion articles. The use of terms or depiction of micrographs describing hemorrhage or the inflammatory, reparative, and remodeling stages of fracture healing are scant to absent.

The consistent lack of bleeding within the bone and subperiosteum along with the absence of subsequent callus sharply contradicts the traumatic origin of classic metaphyseal lesions. A transmetaphyseal planar fracture would be expected to produce considerable hemorrhage, particularly when considering the extremely vascular nature of the subphyseal metaphysis [24] (Fig. 3).

Approximately 81% of dateable classic metaphyseal lesions were classified as healing [3], yet there was no detailed description of the nature or prevalence of callus (subperiosteal or intramedullary). Aside from the relatively novel hypothesis that excessive hypertrophic chondrocytes within the growth plate represent histologic evidence of classic metaphyseal lesion healing, it is unclear how healing was otherwise histologically determined [7–13]. The pattern of excessive hypertrophic chondrocytes was

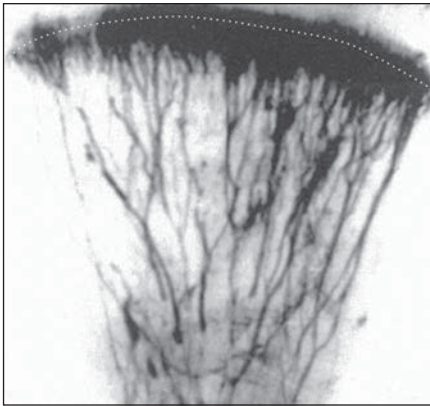


Fig. 3—Microangiogram shows metaphysis in human fetal femur. Marked vascular nature of metaphyseal blood supply is seen even though only arterial components are shown. Rich vascularity appears to contradict bloodless nature of classic metaphyseal lesion microfractures within primary spongiosa as estimated by dotted line. (Reprinted with permission from [24])

reported to be more often focal than diffuse. It was hypothesized that hypertrophic chondrocyte proliferation resulted from traumatic disruption of the metaphyseal blood supply, inhibiting vascular penetration and subsequent resorption of terminal chondrocytes. In support of this hypothesis, the authors cited experimental work of Trueta and Amato [25] who in 1960 reported similar lesions in rabbits. However, Trueta and Amato aggressively disrupted the metaphyseal blood supply in a manner considerably different from typical fracture models. This entailed drilling a hole into the

rabbit metaphysis, sweeping the region with a spatula, and packing the bone defect with polythene film. In spite of the aggressiveness of this technique, the appearance of excessive hypertrophic chondrocytes was transient and commonly appeared more pronounced and persistent in the central growth plate. Because this portion of the growth plate was the last to revascularize, it was suggested to be the last site for hypertrophic chondrocytes to resorb, thus accounting for their persistence. However, the central pattern of excessive hypertrophic chondrocytes described by Trueta and Amato appears to be significantly different from the peripheral pattern observed in classic metaphyseal lesions (Figs. 4A and 4B).

Several examples of “fracture planes” or “planes of separation” have been highlighted in classic metaphyseal lesion histologic specimens [1, 3, 8–13], but their appearances were also similar to tissue processing artifacts [26–28] (Fig. 5). Artifacts that potentially mimic trauma can occur during any of the many stages of processing (tissue handling, fixation, decalcification, sectioning, and staining) and could have accounted for the perplexing lack of bleeding in many classic metaphyseal lesion specimens. The absence of hemorrhage or signs of fracture repair can differentiate artifacts from acute and chronic injuries, respectively.

Similarities of the Classic Metaphyseal Lesion With Healing Rickets

The age distribution of the 31 infants in the largest classic metaphyseal lesion series

[3] was between 3 weeks and 10.5 months (mean, 3 months), a substantially younger and narrower range of ages than reported in any of the prior published series (> 20 cases) of child abuse cases we reviewed. The maximum ages of abused children in these studies ranged from 5 to 18 years. However, the remarkably narrow age range of infants with classic metaphyseal lesions was strikingly similar to that reported for various bone fragility states, including infantile rickets [4–5, 29–32] (Fig. 6).

There are many similarities between the nonspecific histopathologic observations described in classic metaphyseal lesions and those reported in rickets. The diffuse and focal patterns of excessive hypertrophic chondrocytes reported in healing classic metaphyseal lesions are also one of the most established pathologic findings described in rickets [33]. A diffuse pattern is seen in active stages of rickets because of the inability of vascular invasion and subsequent resorption of terminal chondrocytes in the absence of mineralized matrix. Ironically, the peripheral pattern of excessive hypertrophic chondrocytes observed in classic metaphyseal lesions is similar to the pattern reported in an experimental model of rickets [34]. Trueta and Buhr [34] observed that the proliferation of hypertrophic chondrocytes in rachitic rodents was most excessive in the peripheral growth plate (Fig. 4C), corresponding to the region of greatest compressive forces. Healing initially began in the central growth plate, likely related to its proximity to the epiphyseal

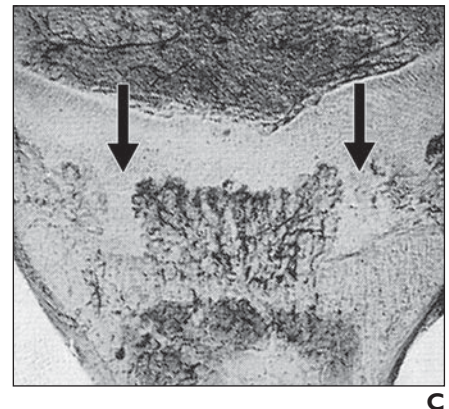
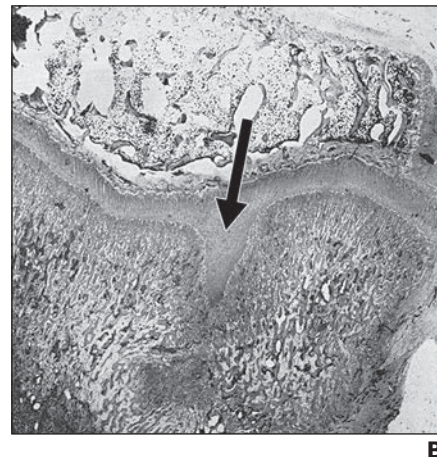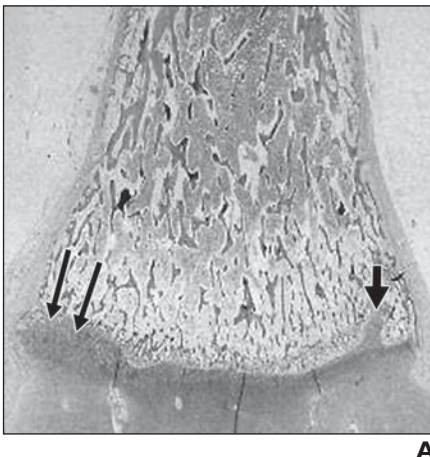
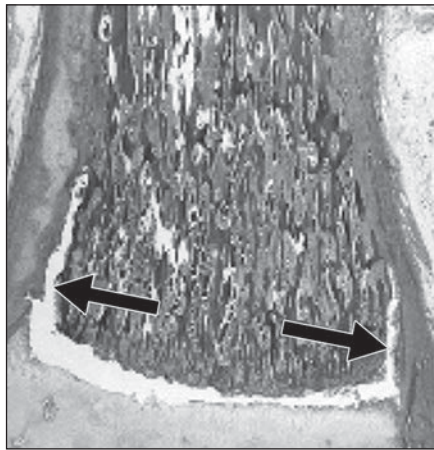
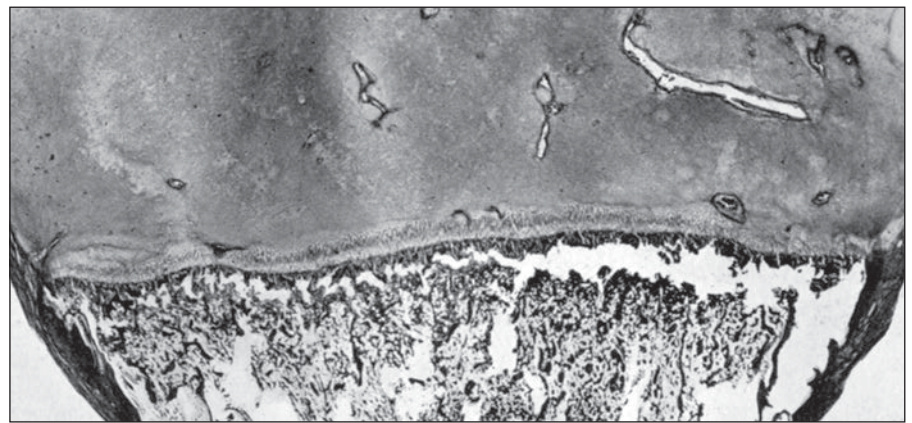


Fig. 4—Differing pattern of excessive hypertrophic chondrocytes in classic metaphyseal lesions and rickets. **A**, Excessive hypertrophic chondrocytes (arrows) in periphery of physis are proclaimed to be sign of classic metaphyseal lesion healing. (Reprinted with permission from [7]) **B**, Peripheral classic metaphyseal lesion pattern in **A** differs from more central pattern (arrow) reported by Trueta and Amato [25] in experimental trauma. (Reprinted with permission from [25]) **C**, Peripheral pattern of excessive hypertrophic chondrocytes (arrows) in classic metaphyseal lesions was also reported in experimental healing rickets. (Reprinted with permission from [34])

Imaging of Classic Metaphyseal Lesion



A



B

Fig. 5—Tissue processing artifacts versus fractures.

A, Microscopy image of classic metaphyseal lesion in 3-month-old girl depicts fracture plane (arrows). Note lack of hemorrhage or cellular changes. (Reprinted with permission from [10])

B, Longitudinal histologic section of distal tibia in infant shows tissue processing artifact is similar to some fracture planes attributed to classic metaphyseal lesions, extending through primary spongiosa and undercutting perichondrial ring. (Reprinted with permission from [28])

blood supply. Thus, the net effect would have resulted in a greater number of excessive hypertrophic chondrocytes in the peripheral growth plate. This would have resulted in a peripheral mineralization defect during incomplete rachitic healing. Figure 4 contrasts the patterns of excessive hypertrophic chondrocytes in traumatic and rachitic models of Trueta and Buhr with those observed in the classic metaphyseal lesion. Even in clinical reports, the radiographic findings attributed to peripheral excessive hypertrophic chondrocytes in classic metaphyseal lesions bear a striking resemblance to published cases of human rickets [35] (Fig. 7).

Various trabecular abnormalities have been reported in the classic metaphyseal lesion articles [1, 3, 9–12]. Trabecular deformations were microscopic and usually without hemorrhage. Trabecular bending and microfractures, however, are also seen in conditions of increased bone remodeling, a known state of fragility. This phenomenon has been thoroughly described by Park [33], who observed compression at the chondroosseous junction in rickets accompanied by bending of the spicules of the matrix and trabecular framework. Decreased trabecular numbers are observed in classic metaphyseal lesions and attributed to remodeling, resorption, or disruption in relation to various stages of fracture healing. However, diminished trabeculae are also characteristic of the rachitic intermediate zone. The trabeculae in rickets may be surrounded by hypocellular marrow and fibrosis [33], features also reported in classic metaphyseal lesions [1,

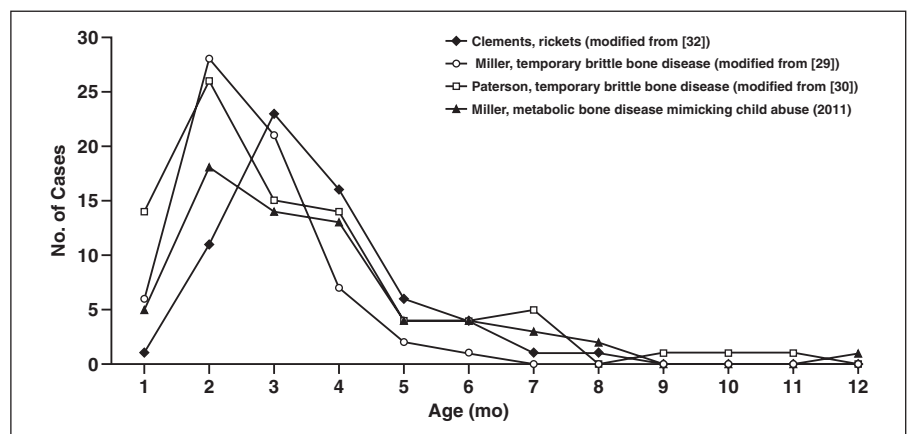


Fig. 6—Graph shows age of presentation of fragile bone conditions is similar to that of classic metaphyseal lesions. Peak age of presentation of various metabolic bone diseases of infancy reported in representative publications is approximately 2–3 months, similar to mean age of 3 months (range, 3 weeks to 10.5 months) reported in 31 infants with classic metaphyseal lesions [3].

13]. Trabecular disorganization is also reported in both rickets [36] and classic metaphyseal lesions [10]. Increased osteoclastic activity with trabecular scalloping is another feature of healing rickets [37] and is also noted in classic metaphyseal lesions [1, 9, 12, 13].

Chondroosseous junction irregularities are frequently noted in radiologic classic metaphyseal lesions [1, 9, 11] and, if traumatic in origin, would be expected to correlate with disruption of mineralized matrix and spongiosa. This, however, was not reported in the published classic metaphyseal lesion histologic specimens. In the classic metaphyseal lesions shown in Figure 8 for example, irregularity of the metaphyseal margins on radiography ap-

pears to correspond histologically to nonuniform mineralization of matrix among excessive hypertrophic chondrocytes residing above the trabecular bone framework, a hallmark sign of rickets. Park [33] detailed the variable manner in which the rachitic intermediate zone remineralized during disease reversal. Irregularities along the chondroosseous junction during healing are the result of random penetrations of vascular tufts into the cartilage cells and matrix and subsequent mineralization. This can result in extensions of focal mineralization into the physis. Indeed, Kleinman et al. [9] reported flame-shaped mineralized extensions from the metaphysis extending into the radiolucent growth plate. The descrip-

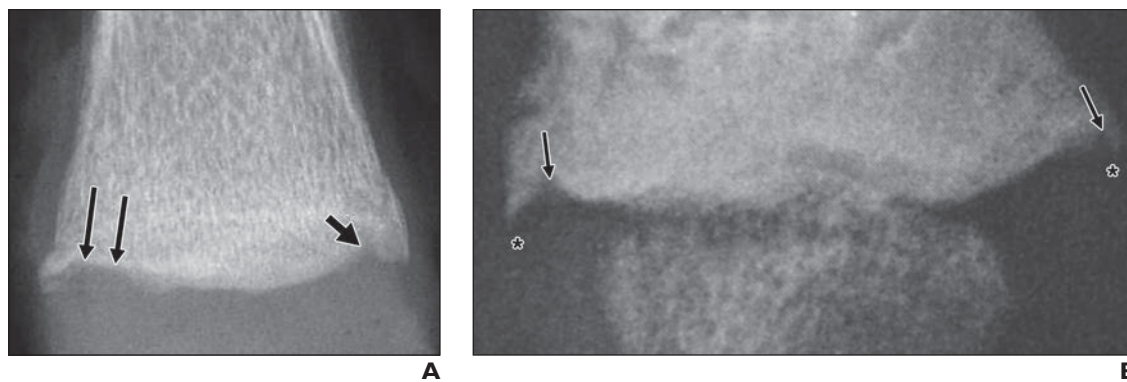


Fig. 7—Similarity of peripheral growth plate in classic metaphyseal lesions and rickets.

A, Radiograph of distal femur from 3.5 month-old child with classic metaphyseal lesions shows peripheral invaginations (*short arrow*) corresponding with excessive hypertrophic chondrocytes (*long arrows*) seen at microscopy adjacent to alleged corner-type classic metaphyseal lesion. (Reprinted with permission from [7])

B, A similar pattern is observed in healing rickets. Peripheral metaphyseal invaginations (*arrows*) adjacent to spurlike thickened perichondrial ring (*asterisks*) project along extreme periphery of chondroosseous junction. (Reprinted with permission from [35])

tion of these changes is remarkably similar to that described in rickets by Eliot and Park [38] in 1948: “The masses of proliferative cartilage cells, which appear as peninsula or thin strands extending from the main body of cartilage toward the shaft, or as islands...” [38]. Therefore, we believe that some of the histologic correlates of metaphyseal irregularities shown in classic metaphyseal lesion studies were inconsistent with trauma but were more likely rachitic in origin.

There are also numerous radiographic similarities between classic metaphyseal lesions and healing rickets. The classic metaphyseal lesion bucket-handle has a striking resemblance to the unique appearance of rachitic reversal within the physis. In early-healing rickets, the appearance of a “displaced” line of mineral-

ization actually represents the newly formed zone of provisional calcification located on the epiphyseal side of the thickened growth plate [38]. The lucent band immediately beneath the new zone of provisional calcification represents the rachitic intermediate zone. This pattern is so characteristic of healing rickets that it once served as the basis for the “line test,” a test used to quantitate antirachitic activity in various therapeutic products (e.g., cod liver oil) when administered to rachitic laboratory rats [39]. Depending on the stage of healing, the appearance of the rachitic intermediate zone varies considerably. Figures 2B and 2D illustrate the similarity between the classic metaphyseal lesion bucket handle and a published example of early healing rickets [1, 40]. As rachitic growth plate healing progresses,

diffuse matrix mineralization may appear as a homogenous nontrabecular “cap” of varying radiodensity abutting but readily differentiated from the underlying original zone of provisional calcification and primary spongiosa. Figure 9 illustrates the similarity of advanced rachitic growth plate healing and some classic metaphyseal lesions [3, 41].

Radiographically, the corner-type classic metaphyseal lesion resembles the thickened perichondrial ring (spur) depicted in healing rickets [42] (Figs. 7, 10A, and 10B). Hess [43] explained that the perichondrial ring, which mineralizes via intramembranous bone formation and develops excess osteoid during active phase rickets, likely accounts for the clinical sign of joint swelling. With the onset of healing, the thick perichondrial ring becomes ra-

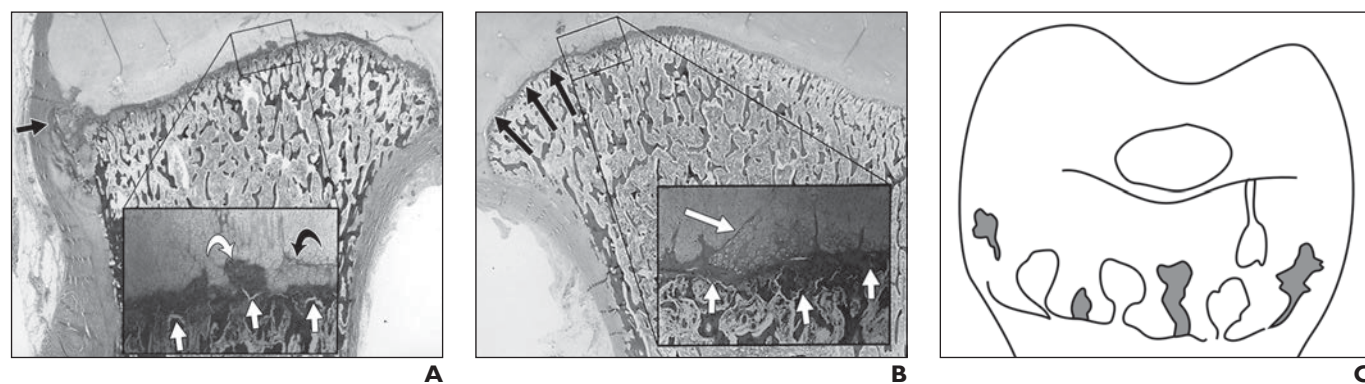


Fig. 8—Chondroosseous junction irregularity in classic metaphyseal lesions versus rickets.

A and B, Photomicrographs of proximal humeri from two different 5-month-old infants with classic metaphyseal lesions. Radiographic irregularity at chondroosseous junction was reported to be result of “peninsula of bone and calcified cartilage” surrounding excessive hypertrophic chondrocytes in **A** and excessive hypertrophic chondrocytes alone in **B**. Insets show that normal regular orientation of mineralized matrix columns is absent. Sporadic columns of matrix mineralization extend into region of excessive hypertrophic chondrocytes, varying in length, orientation, and thickness. Even though both of classic metaphyseal lesions were described as healing-stage lesions, acute-appearing planes of disruption were identified (*short white arrows*) without evidence of hemorrhage, suggesting that these are tissue-processing artifacts. Curved white arrow in **A** indicates peninsula of bone and calcified cartilage and curved black arrow indicates chondrocyte zone. Long white arrow in **B** indicates hypertrophic area. (Reprinted with permission from [9])

C, Drawing shows revascularization patterns observed during rachitic healing in which irregular mineralization is result of variable metaphyseal neovascularization. (Modified and reprinted with permission from [33])

Imaging of Classic Metaphyseal Lesion

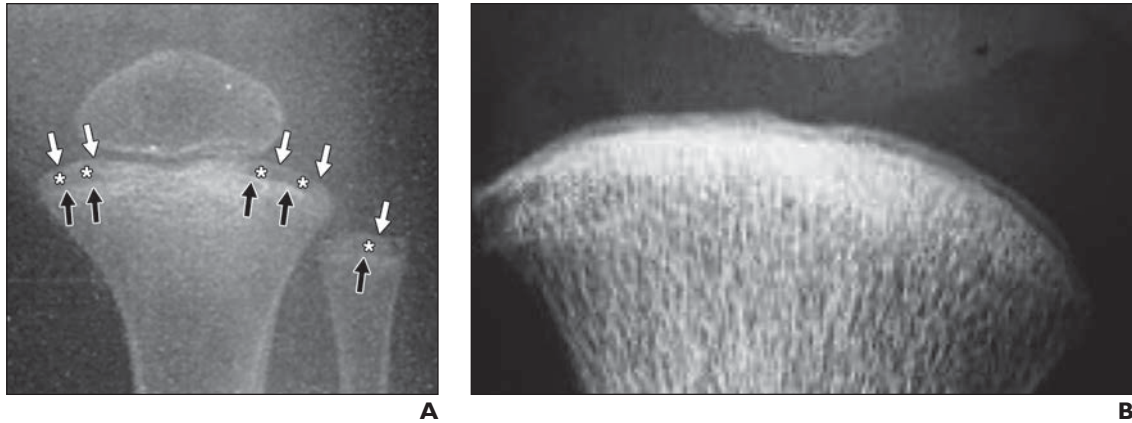


Fig. 9—Radiolucent bands in classic metaphyseal lesions and advanced-stage healing rickets.

A, Radiograph in healing rickets shows original (*black arrows*) and newly formed (*white arrows*) zones of provisional calcifications are often simultaneously observed. Space between new and original zones of provisional calcifications (*asterisks*) corresponds with rachitic intermediate zones and varies in thickness with disease duration. (Reprinted with permission from [41])

B, Similar changes are seen in radiograph of classic metaphyseal lesion of proximal tibia. Note that new and old zone of provisional calcifications appear separated by uniformly thin radiolucent band. (Reprinted with permission from [3])

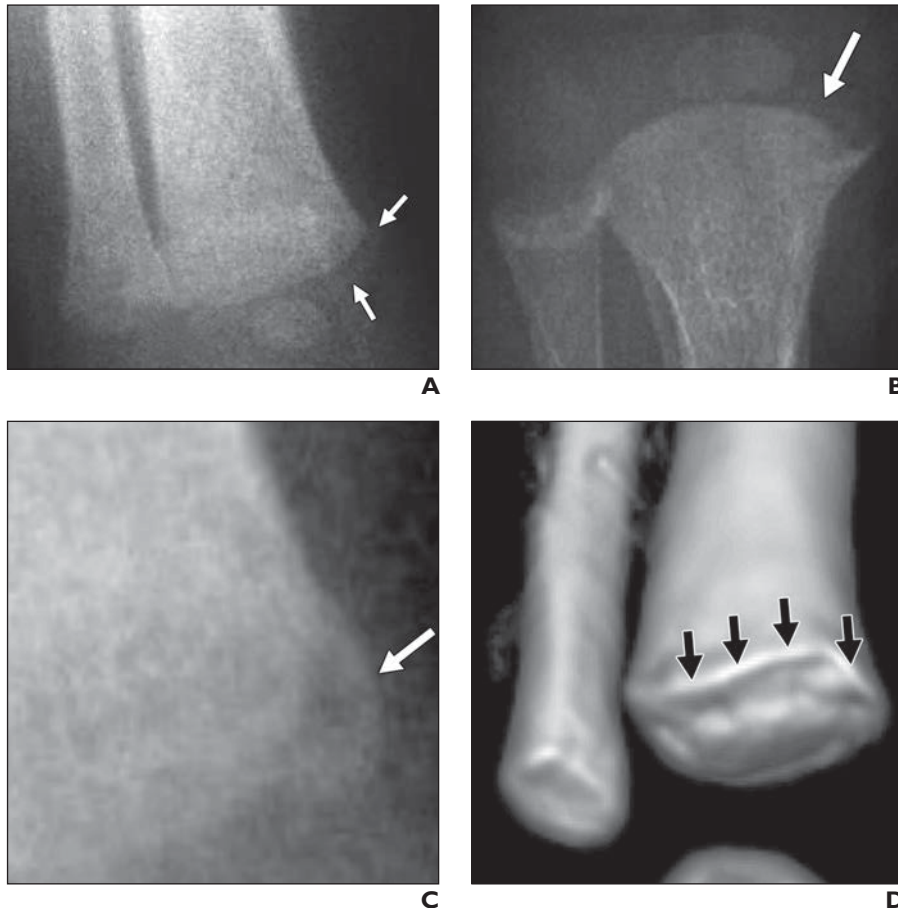


Fig. 10—Bucket-handle fractures versus prominent perichondrial ring.

A, Radiograph shows partial bucket-handle classic metaphyseal lesion in distal tibia of 3-month-old infant appears as curvilinear density (*white arrows*) contiguous with peripheral cortical margin, fading as it extends centrally, but remaining parallel to chondroosseous junction. (Reprinted with permission from [1])

B, Radiograph shows similar classic metaphyseal lesion-like lesion (*arrow*) is depicted in rickets. (Reprinted with permission from [42])

C, Radiograph shows asymptomatic classic metaphyseal lesion-like lesion of distal tibia in 2-month-old infant is similar to that seen in classic metaphyseal lesions (**A**) and rickets (**B**).

D, Multiplanar CT (not shown) and 3D maximum-intensity-projection image for subsequent assessment of infant depicted in **C** failed to show fracture fragment but rather confirmed thick perichondrial ring (*arrows*), consistent with healing rickets.

diographically accentuated and often projects beyond the chondroosseous junction as well as the peripheral cortical margin. A histologic example of an unreported thickened perichondrial ring in a classic metaphyseal lesion is shown

in Figure 11. To our knowledge, this is not a known feature of growth plate trauma. The correct identification of a thickened perichondrial ring is even further hindered by its lack of structural continuity with the subjacent me-

taphyseal cortex and periosteum [44] and thus could sometimes mimic a true corner fracture. The perichondrial ring, like cortical bone, is a circumferential structure and is only visualized when the x-ray beam transgresses a substantial thickness or at the peripheral margins (in profile). When the x-ray beam transgresses the ring en face it is radiographically unapparent. When the x-ray beam passes in a slightly nontangential path, a greater length of the ring may appear and resembles a peripheral bucket-handle classic metaphyseal lesion. Figures 10C and 10D illustrate an example of a corner-type classic metaphyseal lesion that we identified in an infant being evaluated for possible abuse, but the lesion was correctly classified as a thick perichondrial ring on subsequent CT.

Discussion

John Caffey [2] is often credited for originating the hypothesis of unique growth plate injuries in abused children; however, he did not initially appear to be convinced that these lesions were abusive in origin. Osteoporosis was described in one third of his cases, and the fractures of one infant occurred while the infant was hospitalized, suggesting a bone fragility disorder. Caffey reported that only one infant was living within a socially challenging environment (“unwanted”). At least two authors have criticized the conclusion that the infants in the study by Caffey were physically abused but rather believed they may have suffered from undiagnosed medical conditions [45, 46]. Kleinman and colleagues [1], like Caffey, similarly relied on intracranial bleeding to support a diagnosis of child abuse; however, researchers have recently challenged the specificity of intracranial hemorrhage for abuse in infants [47].

Several classic metaphyseal lesion design flaws have been highlighted in our article. Other authors have noted the lack of an adequate control group in all classic metaphyseal lesion studies. In a comprehensive systematic review of the specificity of fracture patterns in abused children, a Welsh multidisciplinary group also excluded the classic metaphyseal lesion articles from their analysis because of the lack of adequate control subjects [48]. In a recent study by radiologists at Boston Children Medical Center, including some of the same coauthors of the classic metaphyseal lesion articles, poor interrater correlation co-

efficients were reported for scoring osteopenia (0.42) and rickets (0.69) in radiographs of older infants and toddlers with vitamin D deficiency [49]. This highlights the need for blinded research design and use of multiple observers because radiographic interpretation is subjective in nature, particularly in the proposal of a novel hypothesis.

The failure to incorporate a trained pathologist in the study design is a significant oversight in classic metaphyseal lesion research and is likely the reason that some tissue processing artifacts were misinterpreted as fracture planes, fractures in the absence of hemorrhage were readily accepted as traumatic, and numerous features of rachitic histopathology were unrecognized.

Novel radiographic findings cannot be relied on as specific signs of a disease process without histologic validation. In addition, validation of the findings should be independently confirmed by others. It is surprising that in the more than 25 years since the first description of classic metaphyseal lesions independent researchers have not published replicated findings. Despite the lack of validation, the classic metaphyseal lesion has gained wide endorsement, including that of the American Academy of Pediatrics [50].

To date, no researchers have experimentally reproduced the transmetaphyseal planar fracture of the classic metaphyseal lesion. In contrast, trauma models consistently report a Salter-Harris type physeal injury pattern, predominately or exclusively involving the growth plate cartilage with variable exten-

sion into small portions of the metaphysis or epiphysis. Therefore, the citation by Kleinman et al. [1] of the experimental work of Ogden et al. [14] in support of the plausibility of classic metaphyseal lesions is inappropriate. In addition, the proclamation of experimental confirmation of classic metaphyseal lesions in swine from their own laboratory in 1986 has yet to be published [1].

Reports of classic metaphyseal lesions resulting from accidental trauma are rare. This fact alone should raise concern that such lesions cannot be easily achieved from the physical forces of inflicted trauma. Classic metaphyseal lesion-like lesions secondary to birth trauma have only been reported after cesarean deliveries. Because the high prevalence of vitamin D deficiency among mothers undergoing cesarean deliveries is now well established [51], classic metaphyseal lesion-like birth lesions after these deliveries must be differentiated from growth plate changes associated with rickets, including epiphyseal slippages.

The concept of a bloodless fracture within the most richly vascular segment of bone in a small infant as a result of a vigorous assault by an adult is novel. Bleeding plays a central role in the initiation of a healing response [52]. The hematoma provides a temporary scaffold for the immobilization of the fracture while it begins to form a callus and heal. Hemorrhage is critical in the development of subperiosteal and endosteal callus. Therefore, it is surprising that neither bleeding nor callus were frequently observed in the classic metaphyseal lesion studies. The subjects

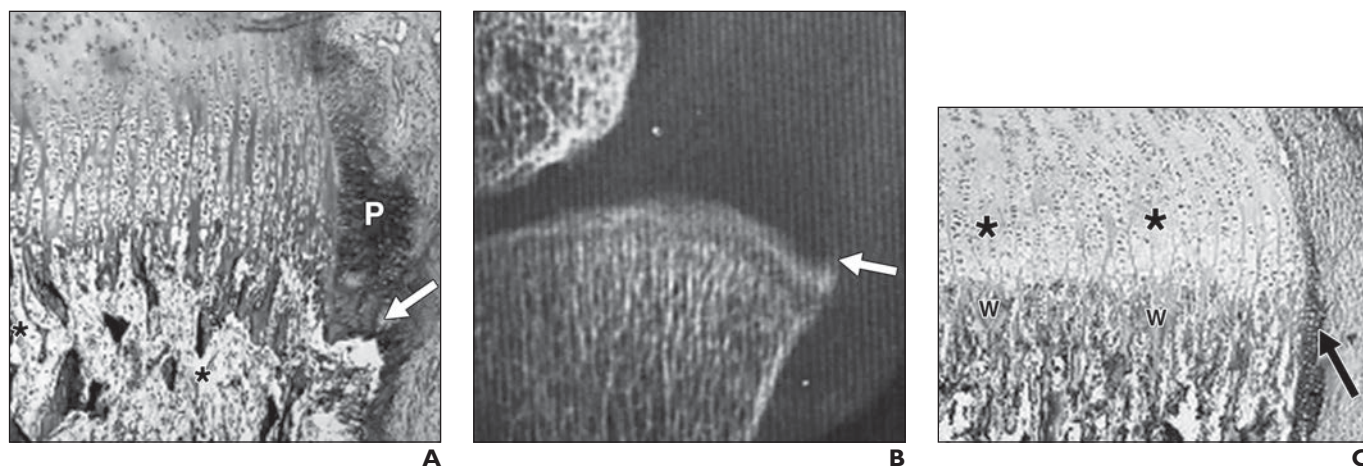


Fig. 11—Thickened perichondrial rings in classic metaphyseal lesions. (Reprinted with permission from [1])
A, Microscopy image shows example of prominently thickened perichondrial ring (P) in infant with classic metaphyseal lesion, which was not acknowledged in original publication.
B, Corresponding radiograph from patient in **A** shows perichondrial spur (arrow) and adjacent band of hypomineralization, consistent with rachitic intermediate zone.
C, Perichondrial ring in healthy infant measures about same width as one chondrocyte column (arrow). Asterisks indicate chondrocytes. W = zone of provisional calcification.

Imaging of Classic Metaphyseal Lesion

TABLE I: Prevalence of Hypovitaminosis D and Rickets

Study Measure	Year	Reference No.	Locale	No. of Patients	Prevalence	Basis for Diagnosis
Maternal vitamin D deficiency Bodnar et al.	2007	65	Pittsburgh, PA	200	Whites: 5% deficient (< 15 ng/mL), 41% insufficient (15–32 ng/mL)	
Lee et al.	2007	64	Boston, MA	40	Blacks: 29% deficient (< 15 ng/mL), 54% insufficient (15–32 ng/mL) 50% deficient (< 12 ng/mL)	Venous blood, routine pregnancy Venous blood, routine pregnancy
Neonatal vitamin D deficiency Bodnar et al.	2007	65	Pittsburgh, PA	200	Whites: 10% deficient (< 15 ng/mL), 56% insufficient (15–32 ng/mL) Blacks: 46% deficient (< 15 ng/mL), 47% insufficient (15–32 ng/mL)	Cord blood, healthy newborns
Lee et al.	2007	64	Boston, MA	40	65% deficient (< 12 ng/mL)	Venous blood, healthy newborns
Neonatal rickets—living Clements	1942	32	Canberra, Australia	134	17% (3 mo), 47% (1–8 mo)	Subclinical rickets, healthy infants, wrist radiography
Owada	1956	59	Sendai, Japan	255	23% (newborn)	Subclinical rickets, healthy infants, wrist radiography
Ramavat	1999	58	Ahmadi, Kuwait	75	6.5% (newborn)	Subclinical rickets, healthy infant wrist radiography, rachitic rosary, laboratory
Yorifuji et al.	2008	57	Kyoto, Japan	1120	22% (1 wk), 5.6% (1 mo)	Subclinical rickets, healthy infants, craniotables, laboratory
Neonatal rickets—autopsy Ranstrom and Von Sydow	1949	60	Gothenburg, Sweden	181	56.9% overall, 35% (0–1 d), 83% (2 d and older)	Consecutive autopsy (0–90 d) rib
Follis et al.	1952	61	Baltimore, MD	450	< 1% (0–15 d), 61% (16–30 d)	Consecutive autopsy (0 d–2 y old), rib
Griffel and Winter	1958	62	Haifa, Israel	98	16% overall, 34.5% (0–3 mo), 11% (full term), 75% (prematuro)	Consecutive autopsy (2 d–2 y old), rib
Liu	1991	63	Beijing, China	124	25.4% (fetus), 35.5% (neonate)	Rib, ulna, and radius

of the core classic metaphyseal lesion studies reviewed in this article were deceased, and thus serial imaging results were not reported. Although this might explain lack of callus in acute and fatal injuries, most classic metaphyseal lesions were classified as healing. Therefore, it is surprising that some instances of callus were not described. Others have also confirmed the notable lack of callus and periosteal reaction in classic metaphyseal lesions, rendering it impossible to date them by conventional methods [53, 54].

The nontraumatic nature of classic metaphyseal lesions is also strongly supported by a recent report of low detection rates by MRI compared with radiography (29% vs 97%), yielding a disappointing 31% sensitivity [55]. In general, MRI has proven to be much more sensitive than radiography in identifying bone trauma in pediatric patients. For example, Naranja et al. [56] reported positive MRI findings in 25 children with radiographically occult fractures predominately around the growth plate.

The traumatic nature of classic metaphyseal lesions was not clinically confirmed because all subjects were deceased at discovery and no description of the premorbid state was offered. However, others have described the predominant asymptomatic nature of classic metaphyseal lesions [53], raising yet more skepticism of their traumatic origin. Even in radiographically occult pediatric fractures secondary to accidental injuries, the vast majority of patients present with clinical symptoms (e.g., decreased use or weightbearing) and signs (e.g., swelling, effusion) of injury [54]. Therefore, the totality of observations that characterize the typical classic metaphyseal lesion (i.e., lack of hemorrhage, callus, periosteal reaction, and clinically silent nature) raise a strong suspicion that classic metaphyseal lesion origins are unrelated to trauma.

It is evident that two major histologic characteristics of classic metaphyseal lesions are hypothesized to be the result of diametrically opposed mechanisms. Excessive hypertrophic chondrocytes were reported to be a sign of bone healing that resulted from disruption of the metaphyseal blood supply, yet there appears to be little evidence of a significant vascular injury given the lack of either microscopic or frank hemorrhage. It is improbable that blood vessels could be consistently injured in such a precise manner to only produce ischemia yet leave no trace of hemorrhage, particularly considering the rich vascular supply of the metaphysis.

Although many other conditions can potentially mimic abuse, healing infantile rickets appears to most closely resemble the reported imaging and histologic features of classic metaphyseal lesions. Incidental rickets was not reported in any classic metaphyseal lesion study nor was it methodically excluded. On the basis of studies reporting rickets in a significant percentage (6.5–22.0%) of screened healthy newborns [57–59] and, of greater relevance, deceased fetuses and infants (1–83%) [60–63], one would have expected some incidental cases of rickets in young infants with classic metaphyseal lesions, potentially confounding a diagnosis of trauma. High rates of rickets are not surprising considering the rising number of reports of subnormal vitamin D levels among pregnant women (54–73%) and their newborns (66–93%) [64–65], data that were not available at the time of the classic metaphyseal lesion publications. Table 1 summarizes some of the relevant prevalence data for vitamin D deficiency and rickets.

That rickets in early infancy should present in a state of healing is also not surprising in light of the high rates of vitamin D deficiency in newborns and the natural history of rapidly rising postnatal serum 25 hydroxy-vitamin D levels [66, 67]. This also supports the observation by Clements [32] in 1943 that, even with the disappearance of epidemic forms, there was an alarming rate of incidental rickets in radiographically screened healthy neonates, peaking in the first few month of life and spontaneously resolving by 8 months. This illustrated the transient but otherwise subclinical nature of rickets in early infancy. The aforementioned autopsy studies also firmly established the predominate subclinical and radiographically occult nature of early infantile rickets [60–63].

Limitations of our assessment include lack of access to classic metaphyseal lesion histopathology, entire skeletal surveys, and complete clinical data on each infant. Future classic metaphyseal lesion studies should include comprehensive evaluation for clinical and subclinical forms of metabolic bone diseases, chiefly rickets. Such a comparative study should make full use of the wealth of histologic and radiographic data from the historic rickets literature. The inability to reproduce classic metaphyseal lesions experimentally, particularly in cadaveric specimens, would cast considerable doubt on the hypothesized traumatic origin of these novel lesions.

The purpose of our article was to outline potential flaws in the classic metaphyseal lesion

studies and limitations of the conclusion that classic metaphyseal lesions are highly specific for child abuse. On the basis of the totality of our findings, summarized in Appendix 1, we conclude that classic metaphyseal lesions are not true fractures but rather a combination of tissue processing artifacts and misinterpreted findings of healing rickets. The observation of rachitic features in classic metaphyseal lesions has potential major implications for the diagnostic approach to the allegedly abused infant with unexplained fractures and metaphyseal abnormalities. Although abuse and rickets may coexist, the presence of classic metaphyseal lesions and non-growth-plate fractures, including rib fractures, might indicate a bone fragility disorder rather than inflicted trauma.

References

1. Kleinman PK, Marks SC Jr, Blackburne BD. The metaphyseal lesion in abused infants: a radiologic-histopathologic study. *AJR* 1986; 146:895–905
2. Caffey J. Multiple fractures in the long bones of infants suffering from chronic subdural hematoma. *Am J Roentgenol Radium Ther* 1946; 56:163–173
3. Kleinman PK, Marks SC Jr, Richmond JM, Blackburne BD. Inflicted skeletal injury: a post-mortem radiologic-histopathologic study in 31 infants. *AJR* 1995; 165:647–650
4. Keller KA, Barnes PD. Rickets vs. abuse: a national and international epidemic. *Pediatr Radiol* 2008; 38:1210–1216
5. Paterson CR. Vitamin D deficiency rickets and allegations of non-accidental injury. *Acta Paediatr* 2009; 98:2008–2012
6. Kleinman PK. Problems in the diagnosis of metaphyseal fractures. *Pediatr Radiol* 2008; 38(suppl 3):S388–S394
7. Kleinman PK, Marks SC Jr, Spevak MR, Belanger PL, Richmond JM. Extension of growth-plate cartilage into the metaphysis: a sign of healing fracture in abused infants. *AJR* 1991; 156: 775–779
8. Kleinman PK, Marks SC Jr. Relationship of the subperiosteal bone collar to metaphyseal lesions in abused infants. *J Bone Joint Surg Am* 1995; 77:1471–1476
9. Kleinman PK, Marks SC Jr. A regional approach to the classic metaphyseal lesion in abused infants: the proximal humerus. *AJR* 1996; 167: 1399–1403
10. Kleinman PK, Marks SC Jr. A regional approach to classic metaphyseal lesions in abused infants: the distal tibia. *AJR* 1996; 166:1207–1212
11. Kleinman PK, Marks SC Jr. A regional approach to the classic metaphyseal lesion in abused infants: the proximal tibia. *AJR* 1996; 166:421–426
12. Kleinman PK, Marks SC Jr. A regional approach to the classic metaphyseal lesion in abused infants: the distal femur. *AJR* 1998; 170:43–47

Imaging of Classic Metaphyseal Lesion

13. Osier LK, Marks SC Jr, Kleinman PK. Metaphyseal extensions of hypertrophied chondrocytes in abused infants indicate healing fractures. *J Pediatr Orthop* 1993; 13:249–254
14. Ogden JA, Lee KE, Rudicel SA, Pelker RR. Proximal femoral epiphysiolysis in the neonate. *J Pediatr Orthop* 1984; 4:285–292
15. Lee KE, Pelker RR, Rudicel SA, Ogden JA, Panjabi MM. Histologic patterns of capital femoral growth plate fracture in the rabbit: the effect of shear direction. *J Pediatr Orthop* 1985; 5:32–39
16. Rudicel S, Pelker RR, Lee KE, Ogden JA, Panjabi MM. Shear fractures through the capital femoral physis of the skeletally immature rabbit. *J Pediatr Orthop* 1985; 5:27–31
17. Salter RB, Harris RW. Injuries involving the epiphyseal plate. *J Bone Joint Surg Am* 1963; 45:587–622
18. Ogden JA, Ganey T, Light TR, Southwick WO. The pathology of acute chondro-osseous injury in the child. *Yale J Biol Med* 1993; 66:219–233
19. Rodríguez JI, García-Alix A, Palacios J, Paniagua R. Changes in the long bones due to fetal immobility caused by neuromuscular disease: a radiographic and histological study. *J Bone Joint Surg Am* 1988; 70:1052–1060
20. Lysack JT, Soboleski D. Classic metaphyseal lesion following external cephalic version and cesarean section. *Pediatr Radiol* 2003; 33:422–424
21. O’Connell A, Donoghue VB. Can classic metaphyseal lesions follow uncomplicated caesarean section? *Pediatr Radiol* 2007; 37:488–491
22. Grayev AM, Boal DK, Wallach DM, Segal LS. Metaphyseal fractures mimicking abuse during treatment for clubfoot. *Pediatr Radiol* 2001; 31:559–563
23. Byers S, Moore AJ, Byard RW, Fazzalari NL. Quantitative histomorphometric analysis of the human growth plate from birth to adolescence. *Bone* 2000; 27:495–501
24. Brookes M. The vascularization of long bones in the human foetus. *J Anat* 1958; 92:261–267
25. Trueta J, Amato VP. The vascular contribution to osteogenesis. III. Changes in the growth cartilage caused by experimentally induced ischaemia. *J Bone Joint Surg Br* 1960; 42-B:571–587
26. Thompson SW, Luna LG. *An atlas of artifacts encountered in the preparation of microscopic tissue sections*. Springfield, MA: Charles C Thomas, 1978
27. McInnes E. Artefacts in histopathology. *Comp Clin Pathol* 2005; 13:100–108
28. Harris HA. *Bone growth in health and disease*. London, UK: Oxford University Press, 1955:161
29. Miller ME. Hypothesis: fetal movement influences fetal and infant bone strength. *Med Hypotheses* 2005; 65:880–886
30. Paterson CR. Bone disease and fractures in early childhood. In: Turner RA, Rogers HO, eds. *Child abuse*. Hauppauge, NY: Nova Science Publishers, 2012:27–52
31. Paterson CR, Monk EA. Long-term follow-up of children thought to have temporary brittle bone disease. *Pediatr Health. Med Ther* 2011; 2:55–58
32. Clements FW. Rickets in infants aged under one year: incidence in Australian community and consideration of aetiological factors. *Med J Aust* 1942; 1:336–346
33. Park EA. Observations on the pathology of rickets with particular reference to the changes at the cartilage-shaft junctions of the growing bones: Harvey lecture, February 16, 1939. *Bull N Y Acad Med* 1939; 15:495–543
34. Trueta J, Buhr AJ. The vasculature contribution to osteogenesis. V. The vasculature supplying the epiphyseal cartilage in rachitic rats. *J Bone Joint Surg Br* 1963; 45:572–581
35. Kottamasu SR. Metabolic bone diseases. In: Kuhn JP, Slovis TL, Haller JO, eds. *Caffey’s pediatric x-ray diagnosis: an integrated imaging approach*, 10th ed. Philadelphia, PA: Mosby, 2003:2247
36. Oppenheimer SJ, Snodgrass GJ. Neonatal rickets: histopathology and quantitative bone changes. *Arch Dis Child* 1980; 55:945–949
37. Dunham EC. Rickets in an infant of thirty-four days. *Arch Ped Adol Med* 1923; 26:155–163
38. Eliot M, Park E. Rickets. In: McQuarrie I, ed. *Brenner’s practice of pediatrics*. Hagerstown, MD: W. F. Prior, 1948:33
39. Norman AW, Henry HL. Vitamin D. In: Zemleni J, Rucker RB, McCormick DB, Suttie JW, eds. *Handbook of vitamins*, 4th ed. Boca Raton, FL: CRC Press, 2007:71–72
40. Fraser D, Kooh SW, Bell L, Duthie D. Human rickets due to combined deficiency of calcium and vitamin D. In: DeLuca HF, Anast CS, eds. *Pediatric diseases related to calcium*. New York, NY: Elsevier, 1980:262–263
41. Chisolm JJ, Harrison HC, Eberlein WR, Harrison HE. Amino-aciduria, hypophosphatemia, and rickets in lead poisoning: study of a case. *AMA Am J Dis Child* 1955; 89:159–168
42. Roepke CL, Luck RP, Del Vecchio M. Rickets in an infant. *J Emerg Med* 2013; 44:e103–e105
43. Hess A. *Rickets, including osteomalacia and tetany*. Philadelphia, PA: Lea and Febiger, 1929:182–186
44. Shapiro F, Holtrop ME, Glimcher MJ. Organization and cellular biology of the perichondrial ossification groove of Ranvier: a morphological study in rabbits. *J Bone Joint Surg Am* 1977; 59:703–723
45. Hiller HG. Battered or not: a reappraisal of metaphyseal fragility. *Am J Roentgenol Radium Ther Nucl Med* 1972; 114:241–246
46. Clemetson CA. Caffey revisited: a commentary on the origin of the “shaken baby syndrome.” *J Am Phys Surg* 2006; 11:20–21
47. Barnes PD. Imaging of nonaccidental injury and the mimics: issues and controversies in the era of evidence-based medicine. *Radiol Clin North Am* 2011; 49:205–229
48. Kemp AM, Dunstan F, Harrison S, et al. Patterns of skeletal fractures in child abuse: systematic review. *BMJ* 2008; 337:a1518
49. Gordon CM, Feldman HA, Sinclair L, et al. Prevalence of vitamin D deficiency among healthy infants and toddlers. *Arch Pediatr Adolesc Med* 2008; 162:505–512
50. Jenny C. Committee on child abuse and neglect: evaluating infants and young children with multiple fractures. *Pediatrics* 2006; 118:1299–1303
51. Merewood A, Mehta SD, Chen TC, Bauchner H, Holick MF. Association between vitamin D deficiency and primary cesarean section. *J Clin Endocrinol Metab* 2009; 94:940–945
52. Claes L, Recknagel S, Ignatius A. Fracture healing under healthy and inflammatory conditions. *Nat Rev Rheumatol* 2012; 8:133–143
53. Hattingh L. Non-accidental injury. *Curr Orthop* 2007; 21:301–309
54. Offiah AC, Hall CM, Fairhurst J. *Radiological Atlas of Child Abuse*. London, UK: Radcliffe Publishing, 2009: 106–117
55. Perez-Rossello JM, Connolly SA, Newton AW, Zou KH, Kleinman PK. Whole-body MRI in suspected infant abuse. *AJR* 2010; 195:744–750
56. Naranja RJ Jr, Gregg JR, Dormans JP, Drummond DS, Davidson RS, Hahn M. Pediatric fracture without radiographic abnormality: description and significance. *Clin Orthop Relat Res* 1997; 342:141–146
57. Yorifuji J, Yorifuji T, Tachibana K, et al. Cranio-tabs in normal newborns: the earliest sign of sub-clinical vitamin D deficiency. *J Clin Endocrinol Metab* 2008; 93:1784–1788
58. Ramavat LG. Vitamin D deficiency rickets at birth in Kuwait. *Indian J Pediatr* 1999; 66:37–43
59. Owada C. Are there new-born rickets? *Tohoku J Exp Med* 1956; 64(suppl P):37–43
60. Ranstrom S, Von Sydow G. Rickets in newborn infants: clinical and histologic study. *Pediatrics* 1949; 4:406–411
61. Follis RH Jr, Park EA, Jackson D. The prevalence of rickets at autopsy during the first two years of age. *Bull Johns Hopkins Hosp* 1952; 91:480–497
62. Griffel B, Winter ST. The prevalence of rickets at autopsy in a subtropical climate: a pilot study in Israel. *J Trop Pediatr* 1958; 4:13–16
63. Liu D. Pathological and x-ray study on bony specimens of rickets from 124 fetal and infantile autopsies [in Chinese]. *Zhonghua Yi Xue Za Zhi* 1991; 71:385–387
64. Lee JM, Smith JR, Philipp BL, Chen TC, Mathieu J, Holick MF. Vitamin D deficiency in a healthy group of mothers and newborn infants. *Clin Pediatr (Phila)* 2007; 46:42–44

65. Bodnar LM, Simhan HN, Powers RW, Frank MP, Cooperstein E, Roberts JM. High prevalence of vitamin D insufficiency in black and white pregnant women residing in the northern United States and their neonates. *J Nutr* 2007; 137:447–452
66. Ziegler EE, Hollis BW, Nelson SE, Jeter JM. Vitamin D deficiency in breastfed infants in Iowa. *Pediatrics* 2006; 118:603–610
67. Narchi H, Kochiyil J, Zayed R, Abdulrazzak W, Agarwal M. Longitudinal study of vitamin D status in the 1st 6 months of life. *Ann Trop Paediatr* 2011; 31:225–230

APPENDIX I: Summary of the Limitations of the Classic Metaphyseal Lesion Hypothesis

Study design limitations

1. Inadequate control group
2. Inter- and intraobserver variability unreported (single radiologist reviewer)
3. Metabolic bone disease assessment not described
4. Nonpathologists interpreted histopathology

Unsupported association with abuse

5. Atypical age group from prior abuse series but ages similar to bone fragility disorders
6. Establishment of abuse was poorly detailed

Lack of replication and validation

7. Radiologic-histologic studies not independently replicated
8. Classic metaphyseal lesions never reproduced experimentally
9. Classic metaphyseal lesions not observed in accidental injuries

Observations uncharacteristic for trauma

10. Paucity of bleeding
11. Lack of description of classic stages of bone healing (callus, periosteal reaction)
12. Unlikelihood that fracture fragment was consistently parallel to point of origin
13. Highly variable fracture plane would refute the primary spongiosa location

Similarities with healing infantile rickets

14. Excessive hypertrophic chondrocytes, especially peripheral pattern
15. Bucket-handle classic metaphyseal lesion similar to new zone of provisional calcification
16. Corner fracture classic metaphyseal lesion similar to rachitic spur (thick perichondrial ring)
17. Miscellaneous: bending, disruption, and paucity of trabeculae; hypocellular marrow with fibrosis or granulation; excess osteoclasts

FOR YOUR INFORMATION

The reader's attention is directed to the commentary on this article, which appears on the following pages.

Commentary on “A Critical Review of the Classic Metaphyseal Lesion: Traumatic or Metabolic?”

Beverly P. Wood¹

In this issue, David Ayoub et al. [1], in their article, “A Critical Review of the Classic Metaphyseal Lesion: Traumatic or Metabolic?”

review the hypothesis that classic metaphyseal lesions represent traumatic changes in abused infants, and they compare these lesions with those resulting from healing rickets. The authors note that the term “classic metaphyseal lesion” was first used in 1986 by pediatric radiologist Paul Kleinman and colleagues [2], who hypothesized that the lesions represented unique metaphyseal fractures in four young infants allegedly subjected to physical abuse. Ayoub et al. conclude by stating, “The hypothesis that classic metaphyseal lesions are secondary to child abuse is poorly supported. Their histologic and radiographic features are similar to healing infantile rickets.”

This point of view is not without controversy. Paul Kleinman maintains that the “classic metaphyseal lesion is, on investigation and correlation, a characteristic metaphyseal lesion related specifically to and correlated with the mechanisms and location of physical abuse of an infant or child” (Kleinman PK, oral communication, 2013). He bases this statement on investigations he has made in collaboration with two histopathologists, Sandy C. Marks and Brian D. Blackburn [2, 3]. Kleinman (Kleinman PK, oral communication, 2013) also indicates that Ayoub et al. [1], in their literature review, have omitted certain relevant published articles in which the metaphyseal lesion histology and its location and cause are discussed, including correlation of the classic metaphyseal lesion with visualized skeletal manifestations of physical abuse in deceased children. Kleinman has provided additional references and comments related to this topic [4–22].

Kleinman (Kleinman PK, oral communication, 2013) asserts that, “the conclusion by

Ayoub et al. [1] that classic metaphyseal lesions are not traumatic lesions contradicts published investigations and is made in contrast to the classic discussions of child abuse in publications such as that of John Caffey [5].” Caffey noted these lesions as early as the 3rd (1956) edition of his text, *Pediatric X-Ray Diagnosis* [5], in which metaphyseal “chip” fractures occurred in the entity he termed “traumatic infantile hyperostosis.” In a 1957 article [6] and the 4th (1961) edition of his text, *Pediatric X-Ray Diagnosis* [7], Caffey presented a diagram depicting “corner” and “bucket-handle” patterns of metaphyseal injury. In the 6th and subsequent editions of his book, Caffey stated that these injuries were the consequence of the battered child syndrome. Kleinman (Kleinman PK, oral communication, 2013) noted that Frederick Silverman [8] wrote about Caffey’s assertion that these lesions represented inflicted injuries. In 1953, Silverman [9] used the term “metaphyseal lesions,” and stated that these injuries were due to child maltreatment. He continued to do so in the textbook, *The Battered Child* [10], which led to multiple texts and scientific articles that mentioned similar characteristic inflicted injuries.

In 2011, to provide further evidence of the association of classic metaphyseal lesions and abuse, Kleinman et al. [11] identified the absence of metaphyseal abnormalities in 42 low-risk infants versus nine classic metaphyseal lesions in 18 infants who were at high risk for physical abuse, and they found a statistically significant difference ($p < 0.0001$) between the two groups. According to Dr. Kleinman (Kleinman PK, oral communication, 2013), Ayoub and his coauthors [1] do not justify their stated conclusion that, “Classic metaphyseal lesions are not true fractures but rather a combination of tissue-processing artifacts and misinterpreted findings of healing rickets.” Kleinman and his coinves-

Keywords: child abuse, classic metaphyseal lesion, rickets

DOI:10.2214/AJR.13.11931

Received September 18, 2013; accepted without revision September 18, 2013.

¹Department Pediatrics, AJR Section Editor for Pediatric Imaging, Keck School of Medicine, University of Southern California, 1975 Zonal Ave, Los Angeles, CA 90089. Address correspondence to B. P. Wood (bwood@usc.edu).

AJR 2014; 202:197–198

0361–803X/14/2021–197

© American Roentgen Ray Society

tigators [12, 13] have emphasized the importance of processing technique to avoid artifacts that may be confused with metaphyseal or physal injury. In a histologic image (Fig. 5A in Ayoub et al.), the authors do not indicate that the legend published in the original article (Fig. 1A in Kleinman et al. [13]) states that “artifactual widening of plane of fracture is evident.” The authors also do not note that the micrograph corresponds with a classic metaphyseal lesion evident on the corresponding (preautopsy) skeletal survey image published as part of the figure.

Ayoub et al. [1] indicate that rickets is a known systemic process, and typical histologic alterations are therefore evident at all active sites of endochondral bone formation [15]. In the 31 infants included in the original study as well as infant fatalities examined with Rosenberg, investigators found no histopathologic evidence of rickets [11]. In discussing infantile rickets, says Kleinman (Kleinman PK, oral communication, 2013), Ayoub et al. also invoke temporary brittle bone disease, including data from other sources [17] (Fig. 6) as well as including citations on the subject. The concept of temporary brittle bone disease has been rejected by national and international societies of pediatric radiologists [16]. Metaphyseal fragmentation lesions should merit consideration in the differential diagnosis in young children [18–21].

The radiologic-histopathologic studies by Marks, Rosenberg, Blackbourne, and Kleinman [2, 3, 13, 18] have provided insights into this distinct traumatic injury, and these studies promote differentiation of classic metaphyseal lesions from potential mimics. In their article, Ayoub et al. [1] omit a presentation of existing investigative science, although their article includes a discussion of published material, including investigated case material. Their article does not contain a validated discussion of the fact that classic metaphyseal lesions, described and histologically investigated and correlated with radiologically visible metaphyseal lesions, are characteristically encountered in

association with other life-threatening inflicted injuries, a reality that has been discussed in the literature. Kleinman (Kleinman PK, oral communication, 2013) believes that to assert otherwise may impede progress in understanding the mechanisms and appearances of injuries and may make it difficult to convey the importance of these findings to other physicians, care providers, investigators, and legal counsel. Failure to recognize and respond accordingly to cases of possible physical abuse places infants and children at risk of serious and potentially fatal injuries [22]. Statements to the contrary, such as those by Ayoub et al., have the potential to negatively affect the welfare of a group of vulnerable children and infants, whose interests pediatricians and caregivers are committed to defend.

References

1. Ayoub D, Hyman C, Cohen M, Miller M. A critical review of the classic metaphyseal lesion: traumatic or metabolic? *AJR* 2014; 202:185–196
2. Kleinman PK, Marks SC Jr, Blackbourne BD. The metaphyseal lesion in abused infants: a radiologic-histopathologic study. *AJR* 1986; 146:895–905
3. Kleinman PK, Blackbourne BD, Marks SC, Karelis A, Belanger PL. Radiologic contributions to the investigation and prosecution of cases of fatal infant abuse. *New Engl J Med* 1989; 320:507–511
4. Perez-Rossello JM, McDonald AG, Rosenberg AE, Ivey SL, Richmond JM, Kleinman PK. Prevalence of rachitic changes in deceased infants: a radiologic and pathologic study. *Pediatr Radiol* 2011; 41:S293
5. Caffey J. Traumatic lesions of bones. In: *Pediatric x-ray diagnosis*, 3rd ed. Chicago, IL: Yearbook Medical Publishers, 1956:832–837
6. Caffey J. Some traumatic lesions in growing bones other than fractures and dislocations: clinical and radiological features. *Br J Radiol* 1957; 30:225–238
7. Caffey J. Traumatic lesions of bones. In: *Pediatric x-ray diagnosis*, 5th ed. Chicago, IL: Yearbook Medical Publishers, 1968
8. Silverman F. Letter to the editor. *Pediatr Radiol* 1994; 24:541–542
9. Silverman F. The roentgen manifestations of unrecognized skeletal trauma in infants. *AJR* 1953; 69:413–427
10. Silverman F. Radiologic aspects of the battered child syndrome. In: Helfer R, Kempe C, eds. *The battered child*. Chicago, IL: University of Chicago Press, 1968:59–76
11. Kleinman PK, Perez-Rossello JM, Newton AW, Feldman HA, Kleinman PL. Prevalence of the classic metaphyseal lesion in infants at low versus high risk for abuse. *AJR* 2011; 197:1005–1008
12. Kleinman PK. *Diagnostic imaging of child abuse*. Baltimore, MD: Williams & Wilkins, 1987
13. Kleinman PK, Marks SC Jr. A regional approach to classic metaphyseal lesions in abused infants: the distal tibia. *AJR* 1996; 166:1207–1212
14. Tsai A, McDonald AG, Rosenberg AE, Gupta R, Kleinman PK. High-resolution CT with histopathologic correlates of the classic metaphyseal lesion of infant abuse. *Pediatr Radiol* 2014 (in press)
15. Shore RM, Chesney RW. Rickets. Part 1. *Pediatr Radiol* 2013; 43:140–151
16. Mendelson KL. Critical review of “temporary brittle bone disease.” *Pediatr Radiol* 2005; 35:1036–1040
17. Kleinman PK, Marks SC Jr, Richmond JM, Blackbourne BD. Inflicted skeletal injury: a post-mortem radiologic-histopathologic study in 31 infants. *AJR* 1995; 165:647–650
18. Kleinman PK. Schmid-like metaphyseal chondrodysplasia simulating child abuse. *AJR* 1991; 156:576–578
19. Kleinman PK, Sarwar ZU, Newton AW, Perez-Rossello JM, Rebello G, Herliczek TW. Metaphyseal fragmentation with physiologic bowing: a finding not to be confused with the classic metaphyseal lesion. *AJR* 2009; 192:1266–1268
20. Kleinman PK, Belanger PL, Karelis A, Spevak MR. Normal metaphyseal radiologic variants not to be confused with findings of infant abuse. *AJR* 1991; 156:781–783
21. Kleinman PK. *Diagnostic imaging of child abuse*, 2nd ed. St. Louis, MO: Mosby Year Book, 1998
22. Deans KJ, Thackeray J, Askegard-Giesmann JR, Earley E, Groner JJ, Minneci PC. Mortality increases with recurrent episodes of nonaccidental trauma in children. *J Trauma Acute Care Surg* 2013; 75:161–165

FOR YOUR INFORMATION

The reader's attention is directed to the article pertaining to this commentary, which appears on the preceding pages.

Letters

Classic Metaphyseal Lesions

I am writing to comment on the article by Ayoub et al. [1], “A Critical Review of the Classic Metaphyseal Lesion: Traumatic or Metabolic?” I would like to add a few important points and clarifications.

The authors criticize our histopathologic descriptions of CMLs in selected publications, alleging the absence of a “credentialed pathologist” in the histologic interpretations. Sandy Marks (deceased) was a professor of anatomy and acknowledged world expert in normal osseous histology and bone repair. Brian Blackbourne (deceased) and Joanne Richmond, both former Massachusetts Chief Medical Examiners, contributed their valued expertise as forensic pathologists to our articles. Not mentioned were our *New England Journal of Medicine* article, which was written with Brian Blackbourne and our *AJR* Caffey Award article [2] regarding the radiologic-histopathologic correlates of metaphyseal injury in infant abuse. Since Sandy Marks’ death, our consultations with the medical examiner’s office and our research continue with noted bone pathologist, Andrew Rosenberg [3].

Credentials are important. The training and clinical experience of authors should be examined, as well as the extent of their original scholarly contributions to the literature. The case materials in our publications, both cited

and excluded by Ayoub et al. [1], were drawn from our customary work with the medical examiner’s office to establish the cause and manner of death in addition to the cases seen in our daily pediatric radiology practice. In contrast, in a poster presentation, Ayoub et al. [4] make reference to their unpublished studies, indicating that their case evaluations were “part of medical-legal proceedings in which the disposition of the infant was to be decided or in which criminal charges were brought against a caregiver, usually one of the parents.” In an interview available online, Ayoub [5] indicates that the case material is not drawn from his general radiology practice but rather from the “three to five cases a week” about which he is contacted by defense attorneys and that notably, “almost 100% of cases I look at have rickets.”

The exploration of the nature of these classic metaphyseal injuries did not begin, nor will it end, with the research I previously conducted with my esteemed colleagues. I encourage other investigators to study classic metaphyseal lesions with sufficient rigor and scholarship to further clarify the morphology and the biomechanics of these distinctive inflicted fractures.

Paul K. Kleinman

*Boston Children’s Hospital,
Harvard Medical School,
Boston, MA*

DOI:10.2214/AJR.14.12532

WEB—This is a web exclusive article.

References

1. Ayoub D, Hyman C, Cohen M, Miller M. A critical review of the classic metaphyseal lesion: traumatic or metabolic? *AJR* 2014; 202:185–196
2. Kleinman PK, Blackbourne BD, Marks SC, Karel- las A, Belanger PL. Radiologic contributions to the investigation and prosecution of cases of fatal infant abuse. *N Engl J Med* 1989; 320:507–511
3. Tsai A, McDonald AG, Rosenberg AE, Gupta R, Kleinman PK. High-Resolution CT with histopathologic correlates of the classic metaphyseal lesion of infant abuse. *Pediatr Radiol* 2014; 44:124–140
4. Ayoub D, Hyman C, Miller M. Metabolic bone disease in young infants with multiple unexplained fractures: multifactorial in etiology and often confused for child abuse. Presented as a poster at Gordon Research Conference on Biomineralization. August 15–20, 2010, Colby-Sawyer College, New London, NH
5. Ayoub D. Natural News Network website. Linderman unleashed: interview with Dr. David Ayoub. radio.naturalnews.com/download.asp?fileid=1195. Published May 21, 2012. Accessed February 7, 2014

Reply

We would like to address Dr. Kleinman's concerns, expressed initially through his communications with Dr. Wood [1], noting that he has contested only two of 17 specific issues we have raised [2].

Kleinman alluded to a new study of classic metaphyseal lesions [3] that was unavailable to us at the time of writing our article, but it was also equally unclear that any pathologist had performed the classic metaphyseal lesion microscopy. The pathologist appeared to only measure the thickness of the zone of provisional calcification in bones without classic metaphyseal lesions. We remain doubtful that there exists a single published description of a classic metaphyseal lesion in which a pathologist interpreted the histopathology.

In the commentary by Dr. Wood [1], Kleinman offered reference 11 that reportedly found no histologic evidence of rickets in deceased infants with classic metaphyseal lesions, including the 31 originally reported by Kleinman nearly 20 years ago. However, in reading that reference, which was to Kleinman's own research [4], we found no mention whatsoever of that analysis. We assume this was either erroneously cited or remains unpublished. We have established that several histologic features of classic metaphyseal lesions are also found in the rickets pathology literature, particularly excessive hypertrophic chondrocytes. We are hopeful that Kleinman will make the original specimens available for review by histopathologists.

Kleinman correctly identified our bypass of one classic metaphyseal lesion publication [5]. This article was not retrievable in PubMed using our search terms, and the concept of the classic metaphyseal lesion was in its early stages. This article failed to assign specific observations to a particular study group (abused vs unabused).

Dr. Ayoub has openly acknowledged the high prevalence of radiographic rickets in reviewed cases of contested child abuse, an opinion shared by Dr. Hyman, a former child-abuse pediatrician, and Dr. Miller, a clinical geneticist/pediatrician specializing in bone disorders, both of whom have reviewed contested child abuse cases. There is undoubtedly a difference in patient populations from contested abuse proceedings versus death evaluations by medical examiners. One of our coauthors, Dr. Marta Cohen, a pediatric histopathologist at Sheffield Children's NHS Foundation Trust, Sheffield, UK, and colleagues [6] recently reported histologic

evidence of rickets in 87% of deceased infants under 1 year old and in all eight infants under 5 months old. Furthermore, rickets was rarely correctly identified by pediatric radiologists. It is concerning that Kleinman [7] reported not one case of rickets among 31 deceased infants even though he has indicated that "...on occasion, discrete osseous fragments resembling corner fractures may be identified in the absence of more dramatic signs of rickets. The diagnosis [of a classic metaphyseal lesion] may be particularly difficult if the metabolic disturbance is partially treated because demineralization may be modest and the density of the zone of provisional calcification may be relatively normal."

We note that Kleinman contested our interpretation of one histologic specimen (Fig. 5 from our article [2]), believing that the lesion was a classic metaphyseal lesion artificially widened by sectioning artifact, whereas we contend that the lesion was entirely artifactual, clearly describing the reasons in the article.

Kleinman thought we ignored numerous prior relevant studies that he alleged had established the classic metaphyseal lesion as a sign of abuse. However, none of these limited observational studies had correlative histologic evaluation. In our opinion, this association resulted from selection and confirmation bias.

Kleinman was critical that we drew material from legal referrals; however, our knowledge of rickets comes from examining an extensive body of scientific literature that has firmly established the basic foundational understanding of the rachitic process. Such work has been widely replicated worldwide and over decades, entailing well-designed clinical and experimental work.

In spite of Kleinman's plea for an open investigation, no other group has systematically analyzed classic metaphyseal lesions. It remains to be seen whether Kleinman's collaboration with Rosenberg will produce an etiologic understanding of the classic metaphyseal lesion process or provide answers to our 15 other concerns. However, we strongly disagree that our critique "may impede progress in understanding the mechanisms" by which classic metaphyseal lesions are produced. Possibly, Kleinman's failure to publish experimental evidence of classic metaphyseal lesions is a greater impediment to establishing the existence of these specific bloodless fractures. As he stated in 1986, "We have produced a similar lesion experimentally in an infant pig model, and a formal report of these findings will be forthcoming" [8].

Future independent research must overcome the inherent "classic metaphyseal lesion bias." Relying on pattern recognition, pathologists and radiologists may apply circular reasoning when diagnosing a classic metaphyseal lesion by "matching" the findings described by Kleinman and assuming what was originally described is valid. Experimental confirmation should include human cadaver models, and the classic metaphyseal lesion should be easily reproduced by mechanisms achievable in the real world. Investigation of postmortem materials must bear in mind the histologic features of recovering rickets, a subject not readily taught today or described in most modern textbooks.

David Ayoub
Clinical Radiologists, SC,
Springfield, IL
Charles Hyman
Pediatrician,
Redlands, CA
Marvin Miller
Wright State University,
Boonshoft School of Medicine,
Dayton, OH

DOI:10.2214/AJR.14.12721

WEB—This is a web exclusive article.

References

1. Wood BP. Commentary on "a critical review of the classic metaphyseal lesion: traumatic or metabolic?" *AJR* 2014; 202:197–198
2. Ayoub D, Hyman C, Cohen M, Miller M. A critical review of the classic metaphyseal lesion: traumatic or metabolic? *AJR* 2014; 202:185–196
3. Tsai A, McDonald AG, Rosenberg AE, Gupta R, Kleinman PK. High-resolution CT with histopathological correlates of the classic metaphyseal lesion of infant abuse. *Pediatr Radiol* 2014; 44:124–140
4. Kleinman PK, Perez-Rossello JM, Newton AW, Feldman HA, Kleinman PL. Prevalence of the classic metaphyseal lesion in infants at low versus high risk for abuse. *AJR* 2011; 197:1005–1008
5. Kleinman PK, Blackbourne BD, Marks SC, Karellas A, Belanger PL. Radiologic contributions to the investigation and prosecution of cases of fatal infant abuse. *N Engl J Med* 1989; 320:507–511
6. Cohen MC, Offiah A, Sprigg A, Al-Adnani M. Vitamin D deficiency and sudden unexpected death in infancy and childhood: a cohort study. *Pediatr Dev Pathol* 2013; 16:292–300
7. Kleinman PK. Problems in the diagnosis of metaphyseal fractures. *Pediatr Radiol* 2008; 38(suppl 3):S388–S394
8. Kleinman PK, Marks SC Jr, Blackbourne BD. The metaphyseal lesion in abused infants: a radiologic-histopathologic study. *AJR* 1986; 146:895–905

SPR Child Abuse Committee Response Regarding Classic Metaphyseal Lesion

The article by Ayoub et al. [1] in the January 2014 issue of the *American Journal of Roentgenology* presents daunting challenges to those caring for potentially abused children. Establishing this diagnosis is an important responsibility. An accurate assessment may save a child's life or avoid further injury. An incorrect assessment may lead to improper care and a child's removal from his or her own home. Either may wreak havoc on children and families and their relationships. The potential consequences weigh heavily on every radiologist. In our opinion, Ayoub et al. exacerbate these challenges by questioning the legitimacy of the classic metaphyseal lesion (CML) as a well-established and highly specific radiographic indicator of child abuse.

When presented with radiographs showing CMLs or when confronted by those who reference the article by Ayoub et al. [1], how should radiologists respond? We should be aware of several omissions in the article. For example, Ayoub et al. question the credentials of Sandy Marks, a major investigator in seminal CML research, identifying him as "a dentist with a PhD in biology" and adding later "the failure to incorporate a trained pathologist in the study design is a significant oversight in classic metaphyseal lesion research." Sandy C. Marks, DDS, PhD, was an internationally preeminent bone biologist and anatomist with excellent credentials. Another major mischaracterization is that Dr. John Caffey doubted the association between inflicted trauma and the metaphyseal abnormalities later called CMLs. In a key publication that Ayoub et al. omit, Dr. Caffey's opinion [2] was unequivocal and he stated: "These terminal (metaphyseal) fragments are early pathognomonic signs of trauma from which a conclusive diagnosis can be made because they are found in no

other disease." We believe other omissions in the article by Ayoub et al. are too numerous to address in this letter.

We assert that time and experience have proven Dr. Caffey correct. Exclusive of child abuse, CMLs are rare. Few radiologists ever encounter this feature outside of nonaccidental trauma. CMLs are not seen in conditions that predispose children to other types of fractures, including severe malnutrition, metaphyseal demineralization, or skeletal deformities. Such conditions include prematurity; restricted intrauterine growth or movement; cardiac, renal, or liver disease; skeletal dysplasias; spina bifida; chromosomal disorders; and cerebral palsy. CMLs do not occur with prenatal maternal endocrine, metabolic, cardiac, or renal disorders; hypertension; drug addiction disorders; or malnutrition. Vitamin D deficiency is not associated with fractures in young children [3]. CMLs are neither reported to occur associated with vitamin D deficiency nor found in children who have florid rickets with concomitant non-CML extremity fractures [4, 5]. Radiographic metaphyseal irregularities in severe metabolic bone diseases, such as rickets, scurvy, and Menkes syndrome, are rarely if ever isolated. Rather, the metaphyseal abnormalities are diffusely distributed and symmetric, even when healing. Furthermore, metaphyseal abnormalities from rickets will be accompanied by other radiographic manifestations of rickets. The editors of *Pediatric Radiology* have rejected contentions linking the high-specificity imaging findings of child abuse with rickets [6]. We reaffirm this position. CMLs are therefore highly specific for child abuse. To deny this fact is to disregard the extensive experience and research of generations of pediatric radiologists.

Scholarly critique of existing evidence is essential, but exclusion of key literature does not constitute healthy scholarship. Given the stakes involved, we think that the

approach of Ayoub et al. [1] is less "critical" than dangerous and that children and families deserve better.

Stephen D. Brown
Boston Children's Hospital,
Harvard Medical School,
Boston, MA

Sabah Serveas
Children's Hospital of Philadelphia,
Philadelphia, PA

Laura L. Hayes
Children's Healthcare of Atlanta,
Atlanta, GA
for the Society for Pediatric Radiology
Child Abuse Committee

DOI:10.2214/AJR.14.12670

WEB—This is a web exclusive article.

References

1. Ayoub DM, Hyman C, Cohen M, Miller M. A critical review of the classic metaphyseal lesion: traumatic or metabolic? *AJR* 2014; 202:185–196
2. Caffey J. Some traumatic lesions in growing bones other than fractures and dislocations: clinical and radiological features: the Mackenzie Davidson Memorial Lecture. *Br J Radiol* 1957; 30:225–238
3. Schilling S, Wood JN, Levine MA, Langdon D, Christian CW. Vitamin D status in abused and nonabused children younger than 2 years old with fractures. *Pediatrics* 2011; 127:835–841
4. Chapman T, Sugar N, Done S, Marasigan J, Wambold N, Feldman K. Fractures in infants and toddlers with rickets. *Pediatr Radiol* 2010; 40:1184–1189
5. Perez-Rossello JM, Feldman HA, Kleinman PK, et al. Rachitic changes, demineralization, and fracture risk in healthy infants and toddlers with vitamin D deficiency. *Radiology* 2012; 262:234–241
6. Slovis TL, Strouse PJ, Coley BD, Rigsby CK. The creation of non-disease: an assault on the diagnosis of child abuse. *Pediatr Radiol* 2012; 42:903–905

Letters

Reply: SPR Child Abuse Committee Response Regarding Classic Metaphyseal Lesion

In response to Brown et al. [1], who wrote on behalf of the Child Abuse Committee of the Society of Pediatric Radiology, we agree that the radiologic diagnosis of abuse should be based on reliable evidence. Our article [2] made two points: first, that the evidence for classic metaphyseal lesions (CMLs) as traumatic lesions is weak and second, that CMLs closely resemble the abnormalities seen in rickets, particularly the healing stages. We are not the first to point out that the evidence that CMLs are indicators of abuse is weak [3]; nor are we the first to suggest that CMLs can resemble healing rickets, which was pointed out in 2008 [4].

Nearly 28 years after Kleinman et al. [5] first proposed that CMLs were specific for abuse, biomechanical and experimental evidence is still lacking, as are witnessed events. The hypothesized microplanar nature and orientation-dependent appearance of the lesions as “bucket-handle” or “corner” lesions are unproven. In endorsing CMLs as “strong” evidence of abuse, Brown et al. [1] ignore the implausibility of bloodless fractures in the highly vascular primary spongiosa, lack of indications of healing, absence of clinical signs or symptoms, lack of experimental reproducibility, and close resemblance to healing rickets.

We have put forth objective criteria showing why the histopathologic interpretations in the underlying articles were misinterpreted. Rather than addressing our contentions, Brown et al. [1] claim that our misrepresentations are “too numerous” to address. Therefore, we cannot comment further; however, we welcome an expanded forum for discussion.

Brown et al. [1] rely on Caffey’s 1946 small case series [6] and his 1957 lecture [7], which actually reported many metaphyseal changes occurred in infants with conventional injuries

that resulted from accidents, birth injuries, and even minor trauma. Caffey’s cases, which were histologically unevaluated, do not provide an evidentiary basis for the hypothesis that CMLs are caused by abuse.

The assertion that CMLs are rare in a variety of bone diseases does not support an abusive cause. If traumatic in origin, CMLs would more likely be produced in fragile bones under normal stresses; however, such is not the case. Few diseases require full skeletal surveys as mandated in “abuse” work-ups, increasing the likelihood of recording incidental findings and subclinical diseases. Because rickets and other bone diseases are often excluded from the differential diagnosis, the fact that CMLs are “rarely” found in bone diseases is circular reasoning.

There are no scientific data to support the claim that the metaphyseal changes of rickets are neither isolated nor asymmetric. Asymmetry in rickets is known [8], and that CMLs were “frequently bilateral and symmetric” and often involved multiple metaphyses of the same limb [9] suggests that their distribution often resembles a systemic disorder rather than that of the random forces of trauma.

Brown et al. [1] do not address our observation that CMLs resemble healing rickets and not active florid rickets [4]. Their more general argument that vitamin D deficiency is not associated with fractures relies on two articles that collectively assessed only two children with mild rickets. The conclusions of these studies contradict extensive literature showing unequivocally that vitamin D deficiency can adversely affect bone quality and increase fracture risk.

Given the lack evidence, we recommend that those interpreting skeletal surveys exercise caution in addressing the cause of CMLs and become familiar with the radiographic signs of healing rickets. Any statement that CMLs are specific for abuse misrepresents the quality of the existing evidence and may result in serious harm to children and families.

David Ayoub
Clinical Radiologists SC,
Springfield, IL

Marvin Miller
Wright State University,
Boonshoft School of Medicine
Dayton, OH

Charles Hyman
Pediatrician,
Redlands, CA

DOI:10.2214/AJR.14.12771

WEB—This is a web exclusive article.

References

1. Brown SD, Serveas S, Hayes LL; Child Abuse Committee of the Society for Pediatric Radiology. SPR Child Abuse Committee response regarding classic metaphyseal lesion. (letter) *AJR* 2014; 203:[web]W232
2. Ayoub DM, Hyman C, Cohen M, Miller M. A critical review of the classic metaphyseal lesion: traumatic or metabolic? *AJR* 2014; 202:185–196
3. Kemp AM, Dunstan F, Harrison S, Morris S, et al. Patterns of skeletal fractures in child abuse: systematic review. *BMJ* 2008; 337:a1518
4. Kleinman PK. Problems in the diagnosis of metaphyseal fractures. *Pediatr Radiol* 2008; 38(suppl 3):S388–S394
5. Kleinman PK, Marks SC Jr, Blackburne BD. The metaphyseal lesion in abused infants: a radiologic-histopathologic study. *AJR* 1986; 146:895–905.
6. Caffey J. Multiple fractures in the long bones of infants suffering from chronic subdural hematoma. *Am J Roentgenol Radium Ther* 1946; 56:163–173
7. Caffey J. Some traumatic lesions in growing bones other than fractures and dislocations: clinical and radiological features—the Mackenzie Davidson Memorial Lecture. *Br J Radiol* 1957; 30:225–238
8. Agarwal A, Gulati D. Early adolescent nutritional rickets. *J Orthop Surg (Hong Kong)* 2009; 17:340–345
9. Kleinman PK. The lower extremity. In: Kleinman P, ed. *Diagnostic imaging of child abuse*. St. Louis, MO: Mosby-Year Book, 1998:45–47