

NCBI Bookshelf. A service of the National Library of Medicine, National Institutes of Health.

De Groot LJ, Beck-Peccoz P, Chrousos G, et al., editors. Endotext [Internet]. South Dartmouth (MA): MDText.com, Inc.; 2000-.

Disorders in Vitamin D Action

Uri A Liberman, M.D., PhD.

Last Update: January 1, 2014.

INTRODUCTION

Vitamin D derived from endogenous production in the skin or absorbed from the gut is transformed into its active form by two successive steps: hydroxylation in the liver to 25-hydroxyvitamin D [25(OH)D] followed by 1 α -hydroxylation in the renal proximal tubule to 1,25-dihydroxyvitamin D (1,25(OH)₂D-calcitriol). Some other cells exhibit 1 α -hydroxylase activity: placental decidual cells, keratinocytes, macrophages from various origins and some tumor cells. The role of the extrarenal production of 1,25(OH)₂D is unknown and under normal conditions it does not significantly contribute to the circulating levels of the hormone. Hydroxylation at carbon 24 to produce 24,25-dihydroxyvitamin D [24,25(OH)₂D] or 1,24,25-trihydroxyvitamin D, is performed in a wide range of normal tissues and is believed to be important in the removal of vitamin D metabolites. All these enzymes are mitochondrial mixed function oxidases containing cytochrome P450 with ferredoxin and heme-binding domains. Cloning of cDNA for porcine 25-hydroxylase and the mouse, rat and human 24- and 1-hydroxylase, as well as the genes for the latter two enzymes, has been reported (1-9).

25-hydroxylation of vitamin D in the liver is not tightly regulated; the principal determinant of its rate is the circulating level of vitamin D. The renal 1 α -hydroxylase enzyme is stringently regulated by: PTH through a cAMP mediated pathway; calcitonin in a different region of the proximal tubule, apparently not via a rise in cAMP; 1,25(OH)₂D through its receptor; calcium by unknown mechanisms and by phosphorus mainly via Fibroblast Growth Factor 23 (FGF-23) production in osteocytes and osteoblasts. The 24-hydroxylase enzyme is modulated by cAMP and the receptors for 1,25(OH)₂D similar to the 1 α -hydroxylase enzyme, but in opposing directions. All calciferols are fat soluble and circulate principally bound to an α -globulin-transcalciferin. Most of the body pool of vitamin D is in the body fat while only a small fraction of the pools of 25(OH)D or 1,25(OH)₂D are in fat. Normal daily turnover of vitamin D and 25(OH)D are approximately 30 and 15 mg per day respectively with 1,25(OH)₂D daily production about 1 mg. The fractional conversion of vitamin D to calcitriol is much higher in vitamin D deficient states. It is difficult to measure vitamin D in blood. Circulating vitamin D metabolites measured in clinical practice are 25(OH)D and 1,25(OH)₂D. As 25(OH)D synthesis is substrate i.e. vitamin D dependent, serum levels of this metabolite are being taken as a measure of vitamin D status (for detailed discussion of the topics of this paragraph and the preceding one, see Chapter 3 of this section).

Calcitriol effects are mediated via a high-affinity intracellular vitamin D receptor (VDR). VDR acts as a ligand-modulated transcription factor that belongs to the steroid, thyroid, and retinoic acid receptors gene family (10-13). VDRs were demonstrated in many tissues, leading to the increased recognition of multiple target organs and actions of the hormone. However, it seems that most calcitriol effects of clinical importance are associated

with mineral homeostasis, though effects on muscle function and coordination, as well as on additional systems, may have clinical relevance.

1,25(OH)₂D is the most powerful physiological agent that stimulates active transport of calcium, and to a lesser degree phosphorus and magnesium, across the small intestine (14,15). Thus, disorders in vitamin D action will lead to a decrease in the net flux of mineral to the extracellular compartment causing hypocalcemia and secondary hyperparathyroidism. Hypophosphatemia will ensue, as a result of both increased renal phosphate clearance due to secondary hyperparathyroidism and reduced absorption of phosphorus due to deficient calcitriol action on the gut. Low concentrations of calcium and phosphorus in the extracellular fluid will lead to defective mineralization of organic bone matrix. Defective bone matrix mineralization of the newly formed bone and growth plate cartilage will produce the characteristic morphological and clinical signs of rickets, while at sites of bone remodeling, it will cause osteomalacia. Disorders in vitamin D action may impair the differentiation of osteoblasts and thus their functional capacity to mineralize bone matrix; this may be an additional mechanism of minor importance that contributes to rickets and osteomalacia (16,17). Continuous bone remodeling takes place in the growing skeleton, thus children with rickets will have osteomalacia as well. The clinical term used in this chapter to describe defective bone matrix mineralization in general will be rickets and/or osteomalacia.

Mineralization of the newly formed organic matrix of bone is a complex and highly ordered process. The essential components for normal mineralization include appropriate extracellular concentrations of calcium, phosphorous and normal functions of the bone forming cells. Disturbances in any of these components will lead to a stereotypic response of disturbed mineralization. The histological, radiological and most of the clinical feature characteristics of rickets and/or osteomalacia will be the same independent of the primary disorder. Thus, defective bone matrix mineralization can be caused by: a) calcium deficiency (e.g. a rare nutritional deficiency of the element or the more common form of calcium deficiency secondary to disorders of vitamin D metabolism) – i.e. hypocalcemic rickets and/or osteomalacia; b) phosphorous deficiency (e.g. increased renal phosphate clearance as in X-linked hypophosphatemia (for detailed discussion see Chapter 10 of this section) – i.e. hypophosphatemic rickets and/or osteomalacia; c) primary defects in local bone processes (e.g. hypophosphatasia) i.e. rickets and/or osteomalacia with normal mineral homeostasis.

Serum concentrations of calcium, phosphorous, iPTH, biochemical markers of bone turnover and 24 hour urinary calcium excretion will differentiate among the different primary disturbances leading to defective bone matrix mineralization (Table 1).

Table 1 Biochemical parameters of mineral and bone metabolism in patients with rickets and/or osteomalacia, by etiology

Etiology	Serum levels				24h urinary calcium excretion
	Calcium	Phosphorous	iPTH	Bone specific alk.phos*	
Hypocalcemic e.g. vitamin D deficiency	Low to low normal	Low	Elevated	Elevated	Low
Hypophosphatemic e.g. X-linked hypophosphatemia	Normal	Low	Normal	Elevated	Low to elevated

			to low normal		
No abnormality in mineral homeostasis e.g. hypophosphatasia	Normal	Normal	Normal	Low	Normal

* Alk. phos. alkaline phosphatase activity

This chapter will deal with hypocalcemic rickets and/or osteomalacia. A primary calcium deficiency state due to extremely low calcium intake was reported in growing children (19) but is very uncommon. Thus, the discussion will concentrate on calcium deficiency secondary to disorders in vitamin D action. Such disorders can be due to disturbances along the cascade of $1,25(\text{OH})_2\text{D}$ synthesis leading to a deficiency of the hormonal form of the vitamin (vitamin D deficiency states) or defects in the interaction of calcitriol and its target tissues (resistance to $1,25(\text{OH})_2\text{D}$).

As all disorders in vitamin D action will lead to the same clinical, radiological, histological, and most of the biochemical aberrations, those common features will be discussed first.

CLINICAL AND RADIOLOGICAL FEATURES OF RICKETS AND OSTEOMALACIA

The clinical features of rickets due to disorders in vitamin D action are weakness, bone pain, bone deformity and fracture. The most rapidly growing bones show the most striking abnormalities. Thus, the localization and severity of the clinical features will depend on the age of onset. In children with acquired disorders in vitamin D action, signs and symptoms of rickets will vary with the age in which the deficiency is being manifested. Children with hereditary disorders of vitamin D action will appear normal at birth as calcium and phosphorous levels in fetal plasma are sustained by placental transport from maternal plasma that is not regulated by the fetal vitamin D system. These children usually develop the characteristic features of rickets within the first 2 years of life. Defects in bone mineralization are particularly evident in regions of rapid bone growth, including, during the first year of life, the cranium, wrist, and ribs. Rickets at this time will lead to widened cranial sutures, frontal bossing, posterior flattening of the skull (craniotabes), widening of the wrists, bulging of costochondral junction (rachitic rosary), and indentation of the ribs at the diaphragmatic insertion (Harrison's groove). The rib cage may be so deformed that it contributes to respiratory failure. Dental eruption is delayed, and teeth show enamel hypoplasia. Muscle weakness and hypotonia are severe and result in a protuberant abdomen, that may contribute to respiratory failure, and may cause inability to walk without support. After the first year of life with the acquisition of erect posture and rapid linear growth, the deformities are most severe in the legs. Bow legs (genu varum) or knock-knee (genu valgum) deformities of various severity develop as well as widening of the end of long bones. If not treated, rickets may cause severe lasting deformities, compromise adult height, and increase susceptibility to pathological fractures (Figure 1).

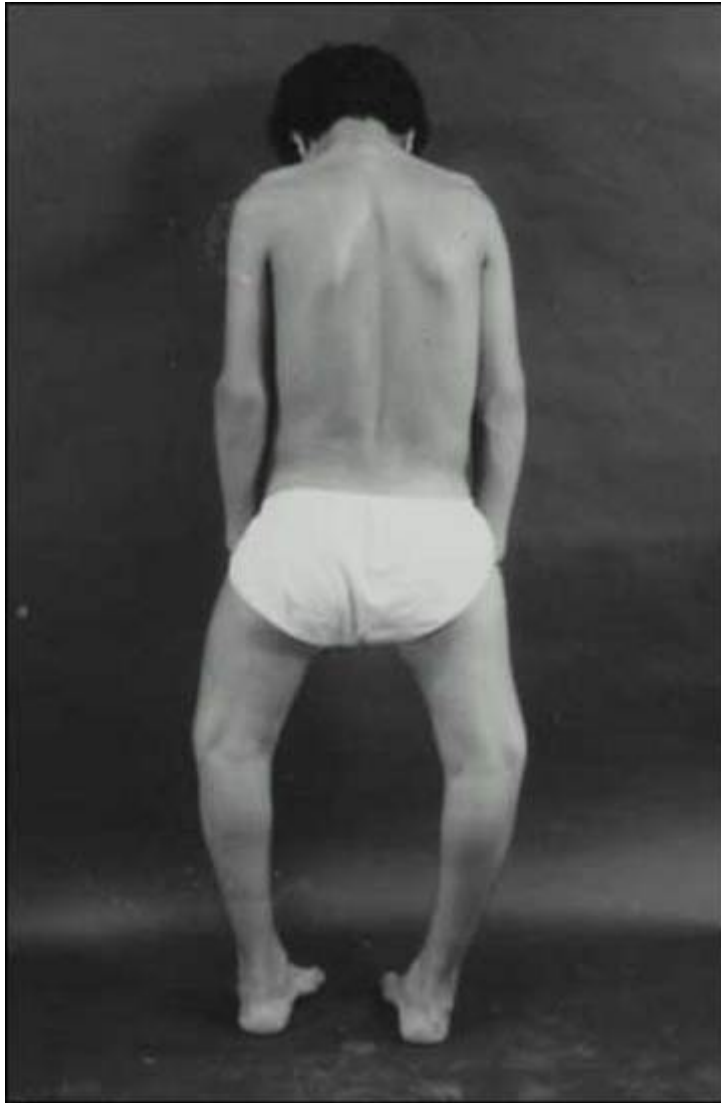


Figure 1. A

teenage male with rickets. Note deformities of legs (bow legs) and compromised height.

The specific radiographic features of rickets reflect the failure of cartilage calcification and endochondral ossification and therefore are best seen in the metaphysis of rapidly growing bones (Figures 2 and 3). The metaphyses are widened, uneven, concave, or cupped and because of the delay in or absence of calcification, the metaphyses could become partially or totally invisible. In more severe forms or in patients untreated for prolonged

periods, rarefaction and thinning of the cortex of the entire shaft, sparse bone trabecularization and bone deformities will become evident. Greenstick fractures may appear as well.

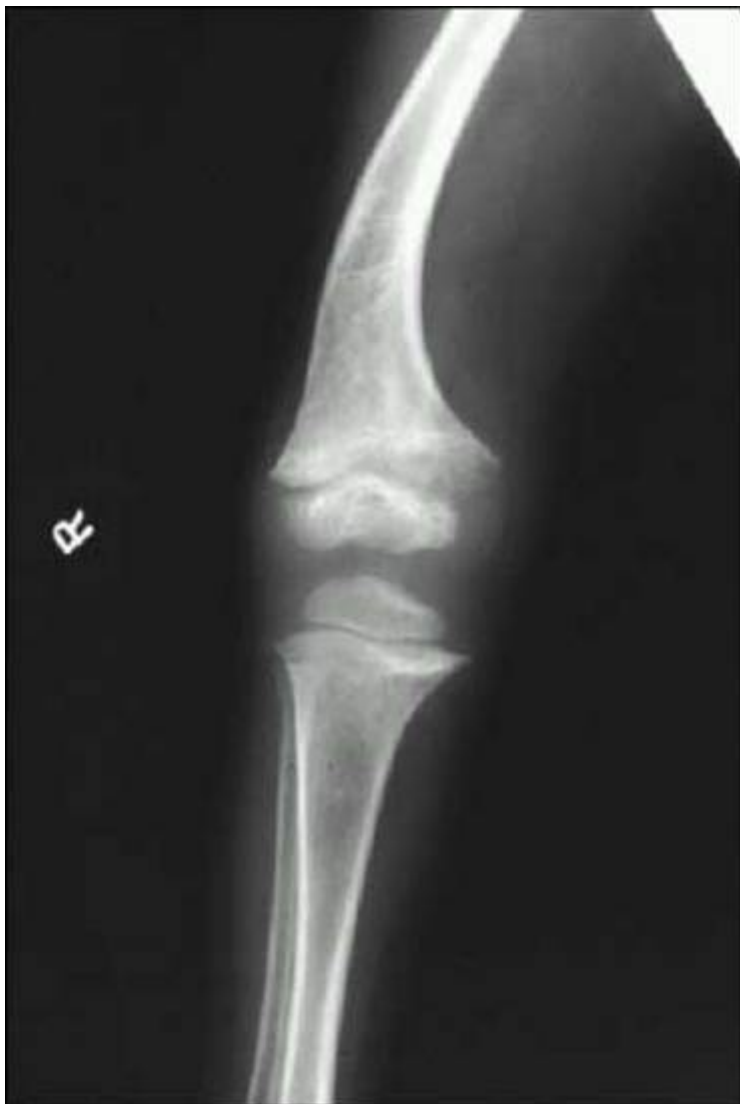

Figure 2

Radiograph of distal femur and proximal tibia and fibula of a patient with rickets. Note widening of epiphysis, resorption of provisional zone of calcification, flaring of metaphysis and bone deformity.

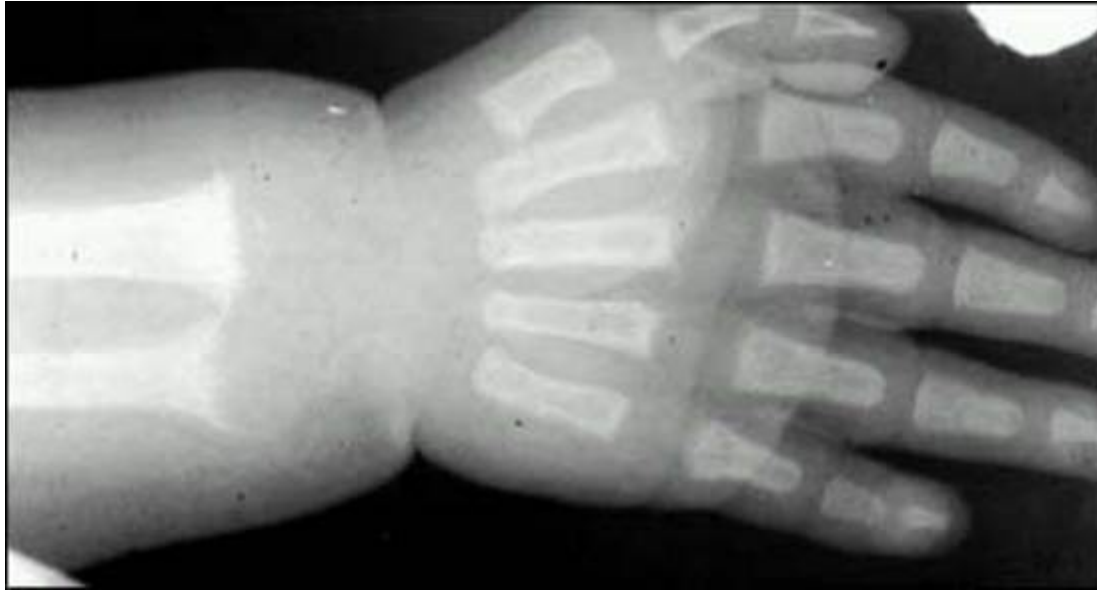


Figure 3

Radiograph of the wrist and hand of a patient with rickets. Note scalloping, widening and irregularity of metaphyseal end of the ulna; apparent widening of the joint space as a result of absence of epiphyseal provisional calcification.

The clinical features of osteomalacia are subtle and could be manifested as bone pain or low back pain of varying severity in some cases. Severe muscle weakness and hypotonia may be a prominent feature in adults with vitamin D deficiency. Improvement of myopathy occurs after very low doses of calcitriol and independently of changes in serum mineral levels.

The first clinical presentation could be an acute fracture of the long bones, pubic ramii, ribs, or spine. The radiographic manifestations could be mild, e.g., generalized, nonspecific osteopenia or more specific, such as pseudofractures, commonly seen at the medial edges of long bones shaft (Figure 4).

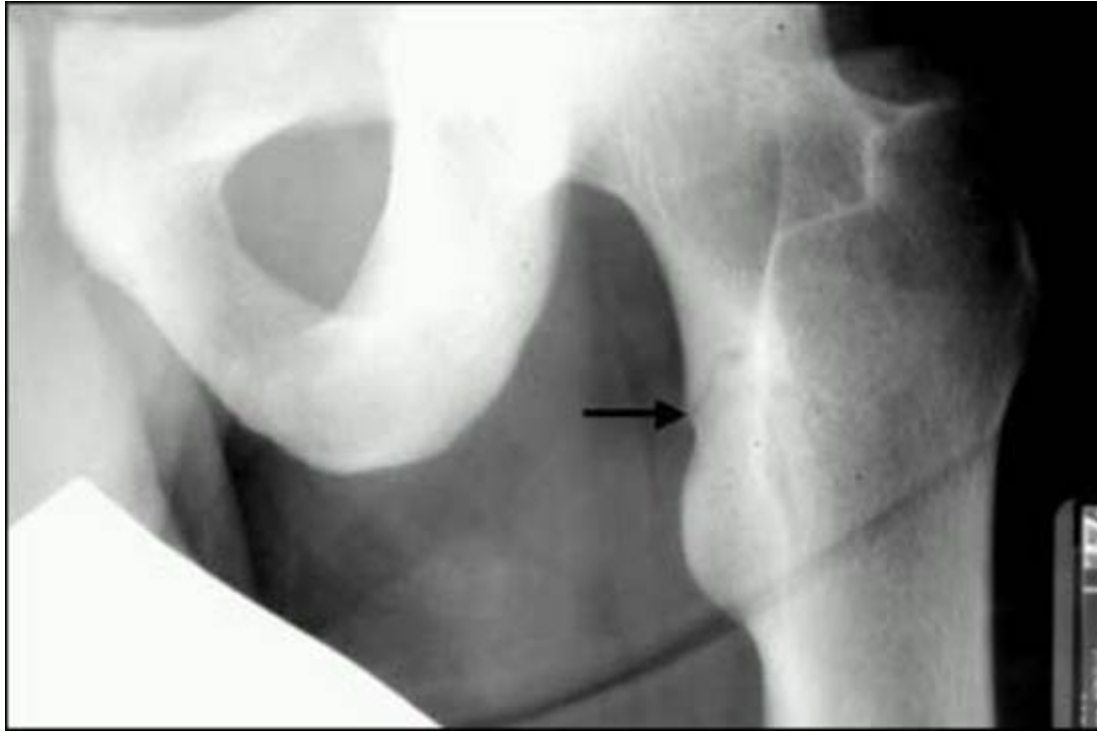

Figure 4. A

young male with osteomalacia. Note a pseudofracture in the medial edge of the upper femoral shaft (arrow).

In hypocalcemic rickets and/or osteomalacia, as is the case in disorders in vitamin D action, there may exist radiographic features of secondary hyperparathyroidism such as subperiosteal resorption and cysts of the long bones.

HISTOLOGICAL FEATURES OF RICKETS AND OSTEOMALACIA

The characteristic histological feature of rickets and osteomalacia is deficiency or lack of mineralization of the organic matrix of bone. Because in clinical practice bone specimen could only be obtained from the iliac crest, the histological picture is osteomalacia. Osteomalacia is defined as excess osteoid (hyperosteoidosis) and a quantitative dynamic proof of defective bone matrix mineralization obtained by analysis of time-spaced tetracycline labeling (20,21).

Bone Biopsy and Bone Histomorphometry

General

Transiliac bone biopsy is taken at a standard location: 2cm behind the antero-superior iliac spine and just below the crest, with a trephine 7.5mm inner diameter or 5mm for children. The biopsy should contain the inner and outer cortex and intact trabecular bone in between. Double tetracycline labeling is performed by giving the drug: e.g. dimethyl-chlortetracycline 1g/day in two divided doses, for 2 days, followed by a second administration after 10 to 14 days of drug free interval. The bone biopsy is performed 5 to 7 days following the last dose of tetracycline. The biopsy is sectioned undecalcified and is being used unstained or with different stains and techniques to obtain qualitative and quantitative histomorphometric parameters (Figure 5). The following are the commonly used quantitative histomorphometric parameters (22): trabecular bone volume (BV/TV), osteoid volume (OV/BV), osteoid surface (OS/BS), osteoid thickness (O. Th), osteoblast surface (Ob.s/BS), osteoclast surface (Oc.S/BS), osteoclast number (N.Oc/TA), double labeled surface (dLS/BS), single labeled surface (sLS/BS), mineral appositional rate (MAR), bone formation rate (BFR/BS), and mineralization lag time (MLT).

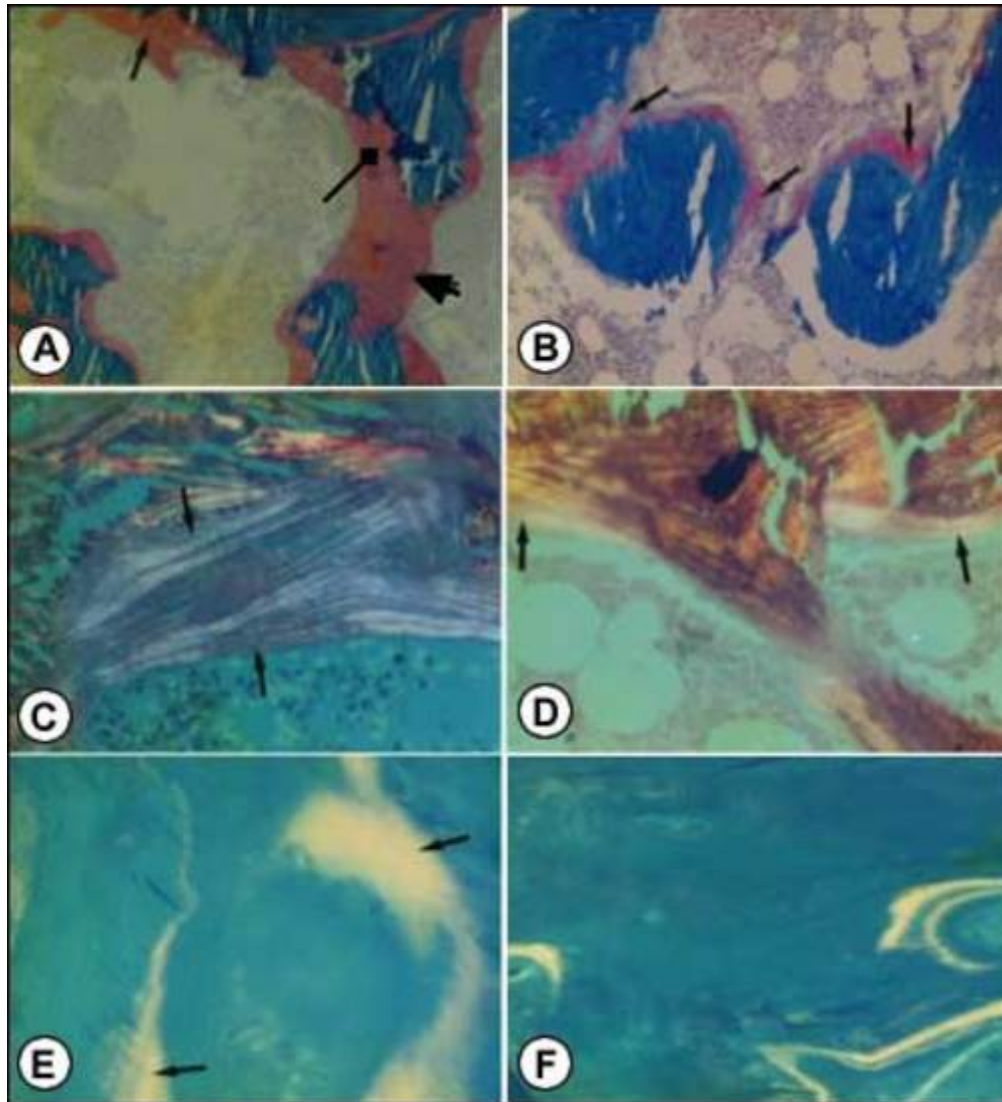


Figure 5

Photomicrographs of transilial bone biopsies of patients with rickets and osteomalacia (A,C and E) and siblings without bone disease (B,D and F) (Courtesy of Drs. D. Gazit and I.A. Bab).A and B: Modified Mason stain; magnification x130. Note in A: broad osteoid seams (arrow), osteoid trabeculae (heavy arrow) and irregular mineralization front (rectangular arrow).C and D: Polarized light; Von Kossa toluidine blue stain; magnification x360. Note in C: increased number of osteoid lamellae (arrows).E and F: Fluorescent photomicrograph, unstained; magnification x200. Note in E wide fluorescent bands (arrows), no double or single tetracycline labels and ground glass appearance.

Osteomalacia

Histologically patients with osteomalacia with or without rickets will represent an abundance of unmineralized matrix, sometimes to the extent that whole trabeculae appeared to be composed of only osteoid (Figure 5A). This will be depicted by quantitative histomorphometry as increases in osteoid volume, surface and thickness (OV/BV, OS/BS and O.TH). However, hyperosteoidosis could be observed in a number of bone diseases with a high turnover. The osteomalacic nature of the hyperosteoidosis is being demonstrated by defective mineralization; irregularity of mineralization fronts (Figure 5A); high number of osteoid lamellae (Figure 5C); broad single tetracycline fluorescent labels (Figure 5E) or no label at all, in contrast to the normal double tetracycline fluorescent labels (Figure 5F). These qualitative observations have to be supported by the unequivocal changes in quantitative histomorphometry, i.e. decreases in a double and single tetracycline labeled surface (dLS/BS and sLS/BS) and in mineral apposition rate (MAR) as well as prolongation of mineralization lag time (MLT).

BIOCHEMICAL FEATURES OF RICKETS AND OSTEOMALACIA

The biochemical parameters characterizing disorders in vitamin D action can be divided into those associated with vitamin D status, the primary disturbance in mineral homeostasis and the respective compensatory mechanisms, and changes in bone metabolism. Changes in mineral and bone metabolism will be similar in all states of disorders in vitamin D action, while serum levels of vitamin D metabolites will characterize each of the classes delineated in the introduction (Table 2).

Table 2. Serum levels of vitamin D metabolites in patients with disorders in vitamin D action, by etiology

*Etiology	Serum levels	
	25(OH)D	1,25(OH) ₂ D
Vitamin D deficiency	Low	Low to normal
1,25(OH) ₂ D deficiency	Normal to elevated	Very low
Resistance to 1,25(OH) ₂ D	Normal to elevated	Markedly elevated

* See section on Definitions and Terminology

As previously discussed, disorders in vitamin D action will lead to hypocalcemia and secondary hyperparathyroidism. Thus, the characteristic biochemical features are low to low-normal concentrations of serum calcium (depending on compensatory parathyroid activity), low urinary calcium excretion, hypophosphatemia, increased serum immunoreactive parathyroid hormone (iPTH) levels, increased urinary cyclic AMP excretion, and decreased tubular reabsorption of phosphate (the last two measures reflecting the biological activity of elevated iPTH). Biochemical markers associated with increased osteoid production as bone specific alkaline phosphatase and osteocalcin will be elevated in states of rickets and osteomalacia (23).

DEFINITIONS AND TERMINOLOGY

Terminology applied to disorders in vitamin D action has led to much confusion. This is principally because the terms were coined prior to our detailed understanding of vitamin D metabolism and mechanism of action. The following will define and clarify the terms deficiency and resistant and point to the limitations and ambiguity of these terms as being currently used as well as additional widely used terms such as pseudodeficiency and dependency.

Deficiency states

It is important to specify the localization of a defect as precisely as possible. The description of a deficiency state should indicate the most proximal metabolite in the vitamin D biosynthetic pathway that is deficient, emphasizing, if possible, that the concentrations of the immediate precursor of the metabolite specified are normal. For example, low serum levels of $1,25(\text{OH})_2\text{D}$ could be the end result of vitamin D deficiency or defects in the activity of the renal tubular enzyme $25(\text{OH})\text{D}1\alpha$ -hydroxylase. Only in the later case it will be appropriate to define it as calcitriol deficiency. Based on our current understanding of vitamin D biosynthesis, three states of deficiency could be envisioned involving the major metabolites: vitamin D, $25(\text{OH})\text{D}$ and $1,25(\text{OH})_2\text{D}$. As mentioned before it is difficult to measure vitamin D in blood. Thus, in clinical practice the diagnosis of vitamin D deficiency states is usually established by measurements of serum $25(\text{OH})\text{D}$ levels. In strict terms, low serum levels of this metabolite imply deficiency of $25(\text{OH})\text{D}$. However, the use of serum $25(\text{OH})\text{D}$ levels as a measure of vitamin D status, is not based just on technical necessity but is being supported by the following: a. the activity of the liver enzyme vitamin D 25 -hydroxylase is not tightly regulated and is driven mainly by the substrate i.e. vitamin D concentrations; b. isolated $25(\text{OH})\text{D}$ deficiency is an extremely rare autosomal recessive disorder, attributed but not proven to be caused by hereditary deficiency of the hepatic enzyme (24); c. the clearance of vitamin D and $25(\text{OH})\text{D}$ is affected similarly by different pathophysiological mechanisms.

Based on the commonly available measurement of only two vitamin D metabolites, two deficiency states could be defined in clinical practice: low serum $25(\text{OH})$ levels implying vitamin D and/or $25(\text{OH})\text{D}$ deficiency, but referred mainly to define a vitamin D deficiency with the limitations mentioned above; and calcitriol deficiency, based on low $1,25(\text{OH})_2\text{D}$ and normal or high $25(\text{OH})\text{D}$ serum levels (Table 2).

In theory, the pathogenic mechanism leading to deficiency of any of these metabolite could be categorized to either defective synthesis or increased clearance, with the exception of the parent vitamin D in which the additional possibility of deficient intake has to be taken into account. Each category: deficient synthesis or increased clearance could have a hereditary or acquired etiology and each subcategory could be further divided into simple (implying that the defect is localized only to vitamin D metabolism) or complex (implying that the defect is a part of a more generalized disturbance affecting other metabolic pathways).

To demonstrate the practical use and usefulness of the terminology, the following are some examples. Calcitriol deficiency could be caused by hereditary or acquired defects of the renal tubular enzyme $25(\text{OH})\text{D}1\alpha$ -hydroxylase. If a hereditary defect involves only the vitamin D metabolic pathway it will be termed simple hereditary calcitriol deficiency. If the defect is a part of a more generalized hereditary disturbance, involving other metabolic pathways as well, e.g. Fanconi syndrome, renal tubular acidosis, X-linked hypophosphatemic rickets, or all states of increased FGF-23 secretion, etc, the disorder will be defined as a complex hereditary $1,25(\text{OH})_2\text{D}$ deficiency. Decreased calcitriol synthesis could be caused by

acquired diseases that usually affect additional metabolic pathways, e.g. chronic renal failure, hypoparathyroidism, tumor induced osteomalacia, etc, thus the appropriate term will be complex acquired 1,25(OH)₂D deficiency due to defective synthesis. Some drugs as barbiturates and the antiepileptic-hydantoin may affect the liver cytochrome P450 enzyme system and increase vitamin D catabolism. It may accelerate vitamin D deficiency usually in patients that have vitamin D insufficiency. Such disturbances will be termed complex acquired vitamin D deficiency due to increased clearance. Intestinal malabsorption either hereditary or acquired interferes with the absorption and enterohepatic recirculation of vitamin D and its metabolites and thus may lead to complex hereditary or acquired vitamin D deficiency due to decreased input.

Resistant states

Resistance to a factor may be defined as a state where normal levels of the factor are associated with subnormal bioeffects. This definition has two important determinants, the factor and the bioeffect. In the case of the vitamin D system, the factor can be the parent vitamin D, the 25-hydroxylated metabolite or calcitriol. Based on vitamin D metabolism and mechanism of action, the term resistance should only be used with the most distal metabolite or the active hormonal form of vitamin D, i.e. 1,25(OH)₂D. For example, patients with a renal defect in calcitriol synthesis are resistant to vitamin D or 25(OH)D caused by defective calcitriol production, but have a complete normal response to physiological replacement doses of 1 α -hydroxylated vitamin D metabolites.

Several bioeffects in vivo have potential relevance in evaluating states of resistance to 1,25(OH)₂D. These include the effects on bone matrix mineralization and the effect on calcium transport through the small intestine. However, as discussed before, rickets and/or osteomalacia are stereotypic responses of the mineralizing bone matrix to a variety of perturbations not all of which are correlated to disturbances in 1,25(OH)₂D action. Two clinical examples are presented to clarify this point: a. X-linked hypophosphatemic rickets (XLH) was and still is termed vitamin D resistant rickets. However, the unresponsiveness to vitamin D of the bone disease in XLH is due to the fact that the defective mineralization is caused mainly by phosphorus deficiency though there is some suppression of calcitriol synthesis caused by increased FGF-23 secretion; b. Hereditary hypophosphatemic rickets with hypercalciuria is a disease characterized by defective bone matrix mineralization, low serum phosphorus and elevated serum 1,25(OH)₂D levels, taken together, it may look as a resistance to the hormone. However, these patients have increased intestinal absorption of calcium and hypercalciuria. The primary defect in this disease is an isolated defect in a renal phosphate transporter leading to increased renal phosphate clearance, hypophosphatemia, an increased 1,25(OH)₂D production and the appropriate physiological response i.e. increased intestinal calcium absorption. The rickets and/or osteomalacia are the result of phosphorus deficiency rather than unresponsiveness to calcitriol (for details see section 10 of this chapter).

There is no doubt about the pivotal role of calcitriol on net calcium transport across the intestinal epithelium. Thus intestinal calcium absorption measured directly or assessed by secondary changes in serum and urine calcium and iPTH levels can be utilized as a bioeffect in evaluating states of resistance to 1,25(OH)₂D. When the defect in bone matrix mineralization is caused by calcium deficiency, rickets and/or osteomalacia could be used as an additional bioeffect to define calcitriol resistance.

Resistance to 1,25(OH)₂D is defined here as a state in which normal or high levels of the hormone are associated with hypo-or normocalcemia, secondary hyperparathyroidism, rickets and/or osteomalacia caused by calcium deficiency.

Pseudovitamin D deficiency and vitamin D dependency

The term pseudovitamin D deficiency refers to a state with biochemical and tissue features of vitamin D deficiency (calcium deficiency, secondary hyperparathyroidism, impaired bone matrix mineralization) with no history of vitamin D or calcium deficiency or low serum levels of 25(OH)D. This is an ambiguous term as it includes two different diseases: 1,25(OH)₂D deficiency and resistance to 1,25(OH)₂D, the so-called pseudovitamin D deficiency type I and II respectively, and does not include the known etiology and pathogenesis of these disturbances.

The term vitamin D dependency has been used interchangeably with pseudovitamin D deficiency. It meant to describe patients capable or responding to, and thus dependent on, supraphysiological doses of vitamin D. This is the situation in patients with simple hereditary 1,25(OH)₂D deficiency due to defects in the renal enzyme 25(OH)vitamin D 1 α -hydroxylase. Patients with this disease have a complete clinical remission on physiological replacement doses of calcitriol. The term vitamin D dependency type II was applied to describe patients with simple hereditary resistance to 1,25(OH)₂D, the majority of whom are unresponsive to any dose of vitamin D or its active metabolites, and therefore are not dependent on vitamin D.

DISORDERS IN VITAMIN D ACTION

Three disorders in vitamin D action will be discussed in this chapter: vitamin D deficiency, mainly simple acquired vitamin D deficiency (i.e. involving only the vitamin D metabolic pathway); simple hereditary 1,25(OH)₂D deficiency resulting from defects in calcitriol biosynthesis; simple hereditary resistance to 1,25(OH)₂D caused by defects in calcitriol receptor-effector system. While acquired vitamin D deficiency is the most common disorder, the other two rare inborn errors in vitamin D metabolism will be discussed because of its immense contribution to the understanding of vitamin D metabolism and mode of action in human beings.

Vitamin D deficiency

Pathogenesis

Vitamin D deficiency can be caused by decreased input or increased clearance. Decreased input of vitamin D may be the end result of: a) defective intake due to dietary (nutritional) deficiency or intestinal malabsorption; b) deficient photosynthesis of vitamin D in the skin. Increased vitamin D clearance could result from increased catabolism, mainly in the liver, or increased loss via the kidneys or intestine. As discussed, each of these disturbance could be, at least in theory, hereditary or acquired, and further subcategorized as simple (involving only the vitamin D metabolic pathway) or complex (implying a more generalized disturbance). Thus, whenever the diagnosis of vitamin D deficiency is established, there is a need to define the etiology and pathophysiology of the disorder and categorize it accordingly.

Vitamin D deficiency due to increased clearance is relatively uncommon in clinical practice and usually is part of more general diseases (i.e. complex disturbances) e.g. protein losing nephropathy, intestinal malabsorption and increased liver catabolism sometimes caused by certain drugs (e.g. barbiturates, antiepileptics, etc). The rest of this section will deal with vitamin D deficiency caused by decreased input.

Vitamin D content of various unfortified food substances is very low with the exception of fatty fish such as herring, mackerel or cod liver oil. It is

estimated that under normal unfortified food consumption, less than 20% of the total circulating 25(OH)D is contributed by nutritional vitamin D. In some countries the dietary content of vitamin D is higher due to vitamin D supplementation of some food products. In the United States, milk is being fortified by 400IU per quart. Increased vitamin D intake could result from habitual use of multivitamins that usually contain 400IU of vitamin D per tablet, or some calcium salt preparations that contain vitamin D as well. These supplements will of course increase the relative contribution of dietary vitamin D intake to the total body vitamin D pool in general, and when cutaneous production of vitamin D is limited, in particular.

Gastrointestinal malabsorption will interfere with vitamin D input from the gut and it may affect the enterohepatic recirculation of vitamin D metabolites as well. Thus, intestinal malabsorption may contribute to vitamin D deficiency by decreasing the input and increasing the clearance of the vitamin and its metabolites. Vitamin D deficiency and its clinical and biochemical consequences may be the first sign of occult-malabsorption due, for example, to non-tropical sprue.

Vitamin D synthesis in the skin is under the influence of UV light with a maximal effective wave length between 290-310 nm. Cutaneous vitamin D production is affected by the intensity of the UV light that reaches the body, the surface area of the skin exposed and intrinsic properties of the epidermis. In northern latitudes, during the winter, almost no UV reaches the ground. In the northern parts of the United States, Canada and Northwestern Europe, between October to March, very little or practically no vitamin D is produced in exposed skin. Clothing affected by religious or cultural habits, glass, plastic and sunscreens that are widely used due to concerns of skin cancer effectively block UV radiation and prevent cutaneous vitamin D synthesis. Vitamin D production is much less effective in dark skin, melanin absorbs UV radiation, and in elderly relative to young people. However, even in the elderly, dermal vitamin D production remains very effective. It has been estimated that in summer, a 10 minute exposure, three times a week of the unprotected skin of the head and arms is adequate to prevent vitamin D deficiency in the elderly (for detailed discussion see Chapter 3 of this section and references 25-27).

Diagnosis

The diagnosis of vitamin D deficiency is established by low serum concentrations of 25(OH)D. As discussed, circulating levels of 25(OH)D are a good and reliable measure of vitamin D status in almost all clinical relevant situations. All additional biochemical parameters as well as clinical signs and symptoms reflect the primary and secondary perturbations in mineral and bone metabolism caused by vitamin D deficiency and are common to all disorders in vitamin D action and calcium deficiency (Tables 1,2). Those parameters include low to low normal serum calcium levels, hypocalciuria, secondary hyperparathyroidism, hypophosphatemia, increased levels of biochemical markers of bone turnover, rickets and/or osteomalacia. Therefore, all these measures can be used to support but not to establish the diagnosis, and mainly to assess the relative severity of the vitamin D deficiency and the response to treatment. It is important to note that in vitamin D deficiency, circulating levels of 1,25(OH)₂D could vary from low to elevated (Table 2) and thus are useless for the diagnosis.

25(OH)D serum levels are currently being determined in clinical practice by methods that have become more accurate and reproducible, though still with some variability. Reference values of serum 25(OH)D that were population based introduce uncertainty. These reference values differed according to geography, season, dress habits, bed or housebound situations and age, all of which may affect sunshine exposure and thus vitamin D synthesis, as well as: eating habits, local regulation on food fortification and customs of vitamin supplementation, all of which will affect vitamin D intake. An alternative approach to obtain clinical meaningful reference values was to define health based parameters, i.e. values of serum 25(OH)D

levels below which adverse health outcome may occur. In actuality it is an intervention threshold reference value, below which therapy may prevent adverse effects on the musculoskeletal system (38). This approach is based on the current notion that though severe vitamin D deficiency will lead to rickets and/or osteomalacia, milder vitamin D deficiency states will not affect bone matrix mineralization, but via its effect on mineral homeostasis will cause secondary hyperparathyroidism, increased bone turnover and bone loss. These aberrations in mineral and bone metabolism will contribute to the development and acceleration of osteoporosis and together with the non-skeletal effects of vitamin D on physical function, will increase the risk of low impact skeletal fractures (for a detailed discussion see chapters 11 to 13 of this section and references 27,38). The relationship between serum concentrations of 25(OH) D and iPTH in various vitamin D states was analyzed in multiple studies (27-30). The aim was to define serum 25(OH)D concentrations below which serum iPTH levels started to increase, or base line 25(OH)D levels above which vitamin D supplementation caused a significant decrease of iPTH serum concentrations. Both approaches yielded similar functional thresholds of serum 25(OH)D levels that affect circulating iPTH concentrations.

Based on these studies, a diagnostic staging of vitamin D deficiency states, based on serum 25(OH)D levels and secondary perturbation in mineral and bone metabolism has been proposed (27). Mild vitamin D deficiency (or vitamin D insufficiency) is diagnosed when serum 25(OH)D levels are below 50 nmol/liter (20 ng/ml). This is associated with mild elevations of serum iPTH and biochemical markers of bone turnover. Moderate vitamin D deficiency is defined when serum 25(OH)D levels are below 25 nmol/liter (10 ng/ml). Serum iPTH concentration is moderately increased with high bone turnover. Severe vitamin D deficiency occurs when serum 25(OH)D levels are lower than 12.5 nmol/liter (5 ng/ml), iPTH circulating concentration may be markedly increased and rickets and/or osteomalacia may occur. It is obvious that according to this scheme, vitamin D sufficiency is defined as serum 25(OH)D levels above 50 nmol/liter (20 ng/ml).

A somewhat similar definition was suggested recently by an expert panel for the Institute of Medicine (IOM) recommending that a level of 50 nmol/liter (20 ng/ml) of 25(OH)D was sufficient for 97.5% of the adult USA population, although up to 125 nmol/liter (50 ng/ml) was considered safe (31). At the same time, another group of experts, from the American Endocrine Society, suggested that the most advantageous value of 25(OH)D for musculoskeletal health is 75 nmol/liter (30 ng/ml) (32). Thus vitamin D insufficiency will be defined as serum 25(OH)D levels below the above, and serum concentrations below 50 nmol/liter (20 ng/ml) will already be considered as vitamin D deficiency.

Prevalence

Serum 25(OH)D levels vary widely among different populations. On average serum 25(OH)D concentration are lower in European countries than in the USA and even lower in some countries in the Middle East and the Asia-Pacific region. A multinational study (with the exception of North America), in post-menopausal women treated for osteoporosis, revealed that 30-90% (depending on location and season), had serum levels of 25(OH)D below 75 nmol/liter (30 ng/ml), (the highest frequency of women below this level was observed in the Middle East and Asia (two countries in each region)). If the threshold is taken as 50 nmol/liter (20 ng/ml), 31% of the women fell below that threshold. Based on more than 40 studies from Europe, North America, the Middle East and the Asian-Pacific regions (27), it seems that a gradual decline in mean serum 25(OH)D levels is apparent starting from healthy adults to independent elderly, institutionalized elderly and the lowest value in patients with hip fracture. Several studies on patients hospitalized for non-traumatic fractures, revealed that few (about 5%) of these subjects had serum 25(OH)D levels above 50 nmol/liter (20 ng/ml), the majority of them had vitamin D deficiency of various severity.

As discussed, vitamin D status will be determined by cutaneous photosynthesis and intake. The populations at risk to develop vitamin D deficiency are those who have limited sunshine exposure and no vitamin D supplementation. Thus, vitamin D insufficiency and deficiency will be more prevalent in populations that are not exposed to sunshine due to geography-latitude, cultural, religious and life-style habits, or are less efficient in cutaneous vitamin D synthesis due to age or pigmentation. The most vulnerable populations are those who are unable to move freely, bedridden or their mobility is severely diminished. This is more common at the beginning or the end of the life cycle, i.e. infants and the elderly, but of course it can happen at any age when free movement is limited due to physical or mental handicap.

The prevalence of osteomalacia is much lower and will depend on the criteria used for diagnosis, i.e. clinical, biochemical, bone histology or quantitative bone histomorphometry. In a review by Paul Lips (27) of 19 publications describing bone histomorphometry of the femoral head or iliac crest biopsy in a total of about 1400 patients with hip fracture, the frequency of osteomalacia ranged from none to more than 30%. This difference may reflect different populations but also the histological criteria used to define osteomalacia. The very high incidence of vitamin D deficiency recorded in patients with hip fractures supports the notion that increased fracture risk is not just the outcome of frank osteomalacia but may result from secondary hyperparathyroidism, increased bone turnover, bone loss and increased risk of low impact fractures caused by vitamin D deficiency. This is further supported by the positive relationship observed between serum 25(OH)D levels (below a certain threshold) and hip BMD (27,33,35), and the negative relationship observed between hip BMD and serum iPTH (27,33,35,36). Moreover, a daily dose of 700-800 IU and above of vitamin D and calcium supplementation caused a significant reduction in the incidence of hip and other nonvertebral fractures in women with post-menopausal osteoporosis, including nursing home residents (37,38,38a).

Treatment

Adequate intake of vitamin D was defined recently in the USA by two working groups (IOM and the American Endocrine Society) as discussed above. Both reports agree on the recommended dose for infants (400 IU/day) and children (600 IU/day). There is a difference in the recommendations for adults (600 IU/day) until the age of 70 (including pregnant and lactating women) and 800 IU/day above this age (IOM report), while the American Endocrine Society recommendations are 1,500-2,000 IU/day for all of the adult population (31,32). In Europe, vitamin D intake recommendations are similar or somewhat lower than the IOM. The upper tolerable daily doses of vitamin D were suggested to be 4,000 IU, 10,000 IU and 2,000 IU by the IOM, the American Endocrine Society guidelines and the European Commission, respectively. There is an unresolved debate on the equipotency of vitamin D₂ versus D₃, but as vitamin D₃ is widely available, all recommendations are actually for vitamin D₃. These recommended intakes of vitamin D are usually unachievable if widely consumed food substances are not fortified with vitamin D. Thus, the population at large and the elderly population in particular are dependent on adequate cutaneous vitamin D synthesis, i.e. sunshine exposure, or vitamin D supplementation. In the United States and a few additional countries, milk is fortified with vitamin D, 400 IU per quart or liter, and the consumption of multivitamins containing vitamin D as well is relatively common, but not uniform or mandatory. Thus, in most countries and even in the USA, the elderly and especially the immobile, housebound elderly are prone to develop vitamin D deficiency.

Treatment has to be targeted towards the population with the highest risk to develop vitamin D deficiency. For a long period, vitamin D supplementation for infants up to 1 year of age, is mandatory in many countries and the daily dose recommendations was increased from 200 IU/day to 400 IU/day (31,32). Unfortunately, this has not yet become common practice for the elderly population. As discussed, nursing home residents,

institutionalized and hospitalized elderly and patients with hip and other non-traumatic fractures and neurological disorders are among the ones with the highest risk of having and developing vitamin D deficiency. Treatment with the recommended doses of vitamin D and calcium (see below) can be initiated even before biochemical screening of 25(OH)D serum levels and indices of mineral and bone metabolism is obtained. This is based on the very high incidence of vitamin D deficiency in this population of patients and on the fact that with the recommended vitamin D doses and the tight physiological control of 1,25(OH)₂D production, no toxicity is likely to occur at doses of up to 10,000 IU/day for a limited period.

It is important to remember that in concordance with vitamin D treatment, the recommended daily calcium allowance must be achieved as well, usually by calcium salt supplementation (see also chapter 13).

The usual recommended oral doses of vitamin D as discussed above are 600 to 1,500 IU daily. In severe vitamin D deficiency, doses of 4,000 IU- to 6,000 IU per day (or the equivalent weekly or twice weekly dose) could be given for the first 4-6 weeks, followed by dose adjustment in accordance with the biochemical response, with the final aim to achieve the recommended maintenance dose. Because vitamin D is stored in fat and released slowly and the half-life of 25(OH)D is 2-3 weeks, the vitamin can be given orally once a week or once a month. Oral administration of vitamin D in megadoses once every 6 or 12 months or once a year by injection (27,39-42) was tried as well but seems to be less efficient. A dose of 500,000 IU once a year seemed to even increase adverse events in the first three months following vitamin D administration (42a). This way of administration has the advantage of better compliance both in independent elderly and especially in dependent institutionalized patients, but the experience gathered with this mode of vitamin D administration is relatively limited.

The response to treatment with vitamin D will depend on the degree and severity of vitamin D deficiency and the secondary changes in mineral and bone metabolism. In severe vitamin D deficiency with osteomalacia, a dramatic response in the signs, symptoms and laboratory parameters will be observed. Bone pain and muscle weakness will improve quickly, pseudofractures will show signs of healing on x-ray, and serum calcium, iPTH and biochemical markers of bone turnover will return towards the normal range. In moderate or mild vitamin D deficiency or insufficiency, the response to treatment is more subtle. Muscle weakness and bone pain may improve, serum 25(OH)D levels will increase towards the normal, serum iPTH and biochemical markers of bone turnover will return towards normal (this will be a function of the severity of the initial vitamin D deficiency). In the long run, bone mineral density may increase somewhat and the incidence of fractures may decrease. These results are based on responses of groups of patients in clinical trials and not individuals (27).

1,25 Dihydroxyvitamin D Deficiency

As discussed, 1,25(OH)₂D deficiency is defined as low circulating levels of this metabolite with normal or elevated (depending on preceding vitamin D therapy) serum concentrations of 25(OH)D. In theory, it could be the end result of decreased production or increased clearance. Increased clearance of 1,25(OH)₂D is uncommon and usually a part of increased clearance of additional vitamin D metabolites such as 25(OH)D, thus it would fit the definition of vitamin D deficiency.

Decreased production of 1,25(OH)₂D could be hereditary or acquired and each one can be subcategorized as simple or complex. Acquired 1,25(OH)₂D deficiency due to defective synthesis is usually part of a more general disease (i.e. complex) as chronic renal failure, acquired Fanconi syndrome or hypoparathyroidism, etc., that will affect mineral and bone metabolism in a multiple and complex way that is beyond the scope of this

chapter. Thus, the entity to be discussed here will be simple hereditary 1,25(OH)₂D deficiency caused by defective synthesis of calcitriol.

Prader et al. (42b) were the first to describe two young children who showed all the usual clinical features of vitamin D deficiency despite adequate intake of the vitamin, thus coining the name “pseudovitamin D deficiency.” Complete remission was dependent on continuous therapy with high doses of vitamin D, thus the term “vitamin D-dependent rickets.” However, remission of the disease could be achieved by continuous therapy with physiological (microgram) doses of 1α-hydroxylated vitamin D metabolites (43,44) (Table 3).

Table 3 Response to treatment of patients with disorders in vitamin D action, by etiology

Etiology	Vitamin D or 25(OH)vitamin D*		1α-hydroxylated vitamin D metabolites*	
	Physiological	Pharmacological	Physiological	Pharmacological
Vitamin D deficiency	+	+	+	toxic
1,25(OH) ₂ D deficiency	-	+	+	toxic
Resistance to 1,25(OH) ₂ D	-	- or +	-	- or +

* Note: physiological doses are those recommended or being used as replacement therapy. Pharmacological doses are 10 times and more of the physiological dose.*see section on Definitions and Terminology. §1α-hydroxylated vitamin D metabolites in clinical use are: 1,25(OH)₂D₃ (calcitriol) and 1α(OH)D₃ (alphacalcidol) a synthetic analog.(+) means responsive, (-) nonresponsive

Family studies have revealed it to be an autosomal recessive disease. Linkage analysis in a subset of French-Canadian families assigned the gene responsible for the disease to chromosome 12q13 (45,46). The gene encoding the 25(OH)D-1α-hydroxylase of mouse kidney, human keratinocyte and peripheral mononuclear cells was localized on chromosome 12q 13.1-13.3 which maps to the disease locus of simple hereditary 1,25(OH)₂D deficiency (47-52). There are no direct measures of the renal enzyme proving defective 1α-hydroxylase activity. This is virtually impossible both because of the difficulty in obtaining tissue and low level of expression. There are several indirect observations to support this etiology. First, circulating levels of 25(OH)D are normal or elevated, depending on previous vitamin D treatment. Second, serum concentrations of 1,25(OH)₂D are very low (Table 2). Third, while massive doses (100-300 times the daily recommended dose) of vitamin D or 25(OH)D are required to maintain remission of rickets, physiological replacement doses of calcitriol are sufficient to achieve the same effect (Table 3). Fourth, it was reported that cells isolated from the placenta of two women with this disease had deficient activity of the decidual enzyme 25(OH)D-1α-hydroxylase (53). It is noteworthy that human decidual cells do produce 1,25(OH)₂D and that this enzyme was regulated by feedback mechanisms (54-56). Finally, the 1α-hydroxylase gene from more than 25 families with simple hereditary 1,25(OH)₂D deficiency and some of their first degree healthy relatives were analyzed by direct sequencing, site directed mutagenesis and cDNA expression in transfected cells (47-52). All patients had homozygous mutations while parents or other healthy siblings were heterozygous for the mutation. Most patients of French-Canadian origin had the same mutation causing a frameshifting and a premature stop codon in the putative heme-binding domain (49). The same mutation was observed in additional families of

diverse origin (52). All other patients had either a base-pair deletion causing premature termination codon upstream from the putative ferredoxin and heme-binding domains, or missense mutations (47,49-52). No 1 α -hydroxylase activity was detected when the mutant enzyme was expressed in various cells. The sequence of the human 1 α -hydroxylase gene from keratinocytes and peripheral blood mononuclear cells has been shown to be identical with the renal gene (47,49-52), thus supporting the use of these accessible cells as a proxy to study the renal tubular enzymatic defect. Taken together, these observations support the notion that the etiology of this hereditary disease is a defect in the renal tubular 25(OH)D-1 α -hydroxylase activity.

The beneficial therapeutic effect of high serum concentrations of 25(OH)D in patients treated with massive doses of vitamin D, while 1,25(OH)₂D levels remain low, may have several possible explanations. First, high levels of 25(OH)D may activate the VDR whose affinity for this metabolite is approximately two orders of magnitude lower than for 1,25(OH)₂D. Second, a metabolite of 25(OH)D may act directly on target tissue, and finally, high levels of 25(OH)D may drive the local production of 1,25(OH)₂D via a paracrine-autocrine pathway, assuming that the tissue enzyme is controlled differently than the renal and decidual enzyme.

The differential diagnosis of simple hereditary 1,25(OH)₂D deficiency from other hereditary or acquired forms of hypocalcemic rickets and/or osteomalacia especially the one associated with defects in the vitamin D receptor-effector system is based on serum concentrations of calcitriol and the response to treatment with 1-alpha hydroxylated vitamin D metabolites (Tables 2 and 3).

A similar syndrome has been described and studied in a mutant strain of pigs where the mode of inheritance as well as the clinical and biochemical features are similar to the human disease (56a, 56b). Piglets affected by the disease have rickets, elevated 25(OH)D with low or undetectable 1,25(OH)₂D serum concentrations, normal specific tissue binding sites for tritiated 1,25(OH)₂D, and no detectable activity of 25(OH)D-1 α -hydroxylase in renal cortical homogenates. Thus, there is strong evidence that the disease state in the pig is caused solely by an inherited defect in the renal enzyme. An animal model in which the gene encoding 25(OH)D-1 α -hydroxylase was knocked out by homologous recombination reproduced all the clinical and biochemical features of this disease including undetectable serum 1,25(OH)₂D levels (56c).

Simple hereditary resistance to 1,25 dihydroxy-vitamin D

This is a rare disorder and only about 60 patients have been reported (57-95c, and personal communications). Brooks et al. (57) described an adult patient with hypocalcemic osteomalacia and elevated serum concentration of 1,25(OH)₂D. Treatment with vitamin D, causing a further increase in serum calcitriol levels, cured the patient. The term vitamin D-dependent rickets type II was suggested to describe this disorder. However, reports on additional patients, about half of whom did not respond to vitamin D therapy, as well as in vivo and in vitro studies to be discussed below, seem to prove that vitamin D dependency is a misnomer. The term simple hereditary resistance to 1,25(OH)₂D caused by defects in the vitamin D receptor-effector system is therefore more appropriate to describe the etiology and pathogenesis of this syndrome.

Clinical and Biochemical Features

General Features

The clinical, radiological, histological, and biochemical features (except serum levels of vitamin D metabolites) are typical of hypocalcemic rickets and/or osteomalacia as previously discussed. Notable exceptions are two unrelated patients with hyperphosphatemia, despite elevated serum levels of iPTH (60,85) which can be the end result of long-standing and severe hypocalcemia, that paradoxically may inhibit the phosphaturic response to PTH or represents an additional hereditary renal tubular defect.

In these patients there is no history of vitamin D deficiency and no clinical or biochemical response to physiological doses of vitamin D or its 1 α -hydroxylated active metabolites (Table 3). Serum levels of 25(OH)D are normal or elevated (depending on preceding vitamin D therapy); 1,25(OH)₂D concentrations are markedly elevated before or during therapy with vitamin D preparations (Table 2).

The disease manifests itself as an active metabolic bone disease in early childhood. However, late onset at adolescence and adulthood was documented in several sporadic cases including the first report by Brooks et al. (57,61). These patients represented the mildest form of the disease and had a complete remission when treated with vitamin D or its active metabolites. It is unclear if the adult onset patients belonged to the same hereditary entity, as no further studies on their VDR status have been published.

Ectodermal Anomalies

A peculiar clinical feature of the patients, appearing in more than half of the subjects, is total alopecia or sparse hair (Figure 6). Alopecia usually appears during the first year of life and in one patient, at least, has been associated with additional ectodermal anomalies (60) (Figure 6).

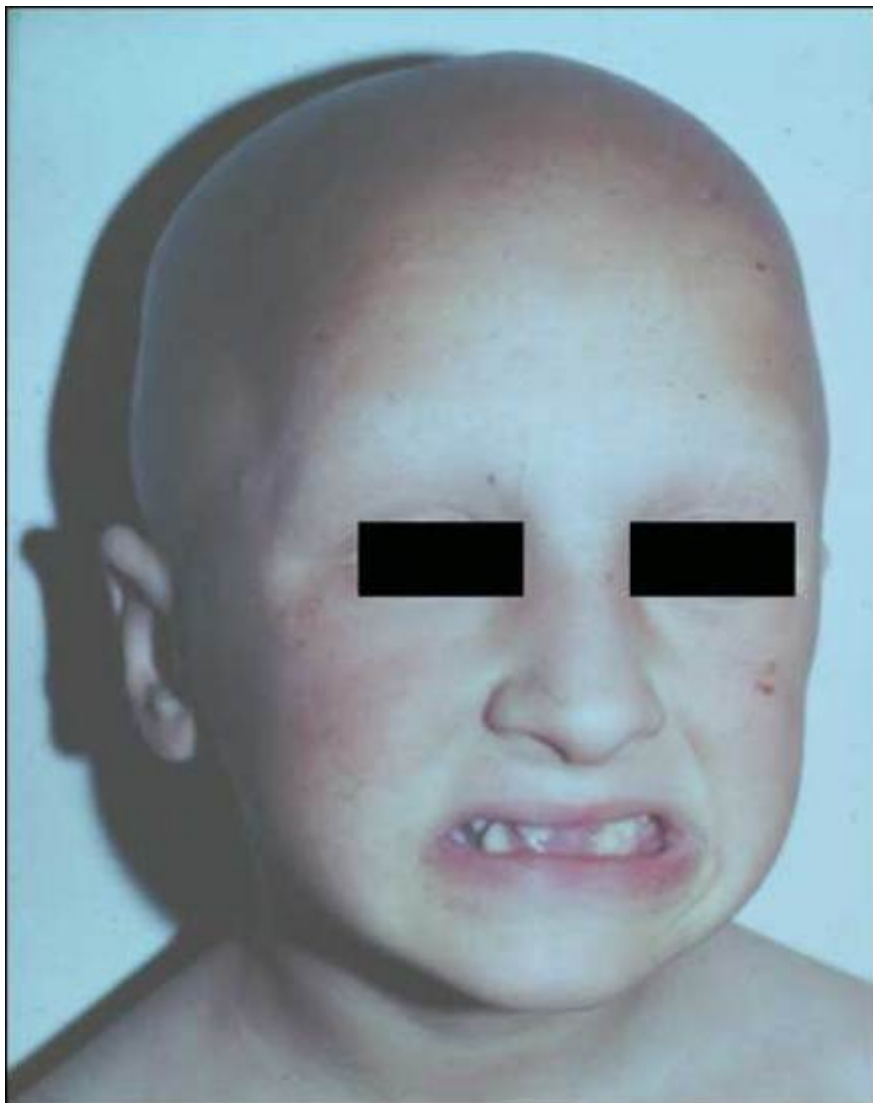

Figure 6. A

patient with simple hereditary resistance to 1,25(OH)₂D. Note total alopecia and oligodontia.

It seems that alopecia is a marker of a more severe form of the disease as judged by the earlier onset, the severity of the clinical features, the proportion of patients who do not respond to treatment with high doses of vitamin D or its active metabolites, and the extremely elevated levels of serum 1,25(OH)₂D recorded during therapy (74,96). Though some patients with alopecia could achieve clinical and biochemical remission of their

bone disease, none have shown hair growth. The notion that total alopecia is probably a consequence of a defective vitamin D receptor-effector system is supported by the following: alopecia has only been associated with hereditary defects in the VDR system, i.e., with end-organ resistance to the action of the hormone, and has not been recorded with hereditary deficiency in $1,25(\text{OH})_2\text{D}$ synthesis, i.e., low circulating levels of the hormone; alopecia is present in kindreds with different defects in the VDRs; high-affinity uptake of tritiated $1,25(\text{OH})_2\text{D}_3$ in the nucleus of the outer root sheath of the hair follicle of rodents has been demonstrated by autoradiography (97); and the epidermis and hair follicle contain a calcium-binding protein that is partially vitamin D-dependent (74). Finally, alopecia developed in homozygote VDR knockout mice (98-100). Taken together, it could be hypothesized that an intact VDR-effector system is important for the differentiation of the hair follicle in the fetus, which is unrelated to mineral homeostasis.

Vitamin D Metabolism

Serum concentrations of $1,25(\text{OH})_2\text{D}$ range from upper normal values to markedly elevated before therapy, but on vitamin D treatment may reach the highest levels found in any living system (100 times and more than the upper normal range) (96). These values may represent the end results of four different mechanisms acting synergistically to stimulate strongly the renal $25(\text{OH})\text{D}-1\alpha$ -hydroxylase. Three of the mechanisms are hypocalcemia, secondary hyperparathyroidism, and hypophosphatemia. The fourth mechanism may be a failure of the negative feedback loop by which the hormone inhibits the renal enzyme activity caused by the basic defect in the VDR-effector system. This was demonstrated in a patient in remission (normal serum levels of calcium, phosphorus and PTH) in whom a load of $25(\text{OH})\text{D}_3$ had caused a marked increase in serum $1,25(\text{OH})_2\text{D}_3$ concentration (67,74). It was reported that the 1α -hydroxylase gene expression was not suppressed by $1,25(\text{OH})_2\text{D}_3$ in renal tubular cells from VDR knock out mice while it was suppressed in cells with normal VDR or heterozygote for the null mutation (6,9).

Mode of Inheritance

In approximately half of the reported kindreds, parental consanguinity and multiple siblings with the same defect suggest autosomal recessive mode of inheritance (74). Parents or siblings of patients who are expected to be obligate heterozygotes have been reported to be normal, i.e., no bone disease or alopecia and normal blood biochemistry. However, studies on cells (cultured dermal fibroblasts, Epstein-Barr transformed lymphoblasts, and mitogen-stimulated lymphocytes) obtained from parents or siblings of affected children revealed decreased bioresponses, decreased normal VDR protein and its mRNA, and a heterozygote genotype exhibiting both normal and mutant DNA alleles (101-104). There is a striking clustering of patients around the Mediterranean, including patients reported from Europe and America who originated from the same area. A notable exception is a cluster of some kindred from Japan (61,63,78-81,85).

Cellular and Molecular Defects

Methods

The near ubiquity of a similar if not identical VDR-effector system among various cell types including cells originating from tissues easily accessible for sampling made feasible studies on the nature of the intracellular and molecular defects in patients with simple hereditary resistance to

1,25(OH)₂D. The cells used were mainly fibroblasts derived from skin biopsies (65-72,74-77,80,92-95,101-103) and peripheral blood mononuclear (PBM) cells (78,85,103-105). PBM cells contain high-affinity receptors for 1,25(OH)₂D₃ that are expressed constitutively in monocytes and are induced in mitogen-stimulated T-lymphocytes and Epstein-Barr (EB) transformed lymphoblasts. All cells have been used to assess most of the steps in 1,25(OH)₂D₃ action from cellular and subcellular uptake of the hormone to bioresponse as well as to elucidate the molecular aberrations in the VDR protein, RNA, and DNA.

The hormone-receptor interaction has been analyzed by several methods including binding characteristics of 3H 1,25(OH)₂D₃ to intact cells, nuclei or high salt cellular soluble extracts-so called cytosol (65-68, 70-77, 101-108); measurements of VDR protein content by monoclonal antibodies with radiological immunoassay or Western blot analysis (102,103); by immunocyto-chemical methods in whole cells (109); characterization of the hormone-receptor complex on continuous sucrose gradient and nonspecific DNA-cellulose columns (65-68, 70-75, 101,108,110).

The cloning and nucleotide sequencing of the human VDR gene made feasible studies of the molecular defects in patients with this disease. The methods used included, among others, isolation, amplification and sequencing of genomic VDR DNA, as well as cloning and sequencing of VDR complementary DNA (cDNA). The mutant DNA was recreated in vitro and was transfected into cells that do not express endogenous VDR. Post-transcriptional action of 1,25(OH)₂D was tested in cells originating from patients or in cells co-transfected with VDR (either mutant or wild type) fused to a promoter containing vitamin D response element (VDRE).

Types of Defects

Studies with the above mentioned methods in cells originating from a variety of patients revealed heterogeneity of the cellular and molecular defects in the VDR-effector system. Based on the known functional properties of the VDR, different classes of defects could be identified.

Defect in the hormone binding region (including heterodimerization).

Deficient Hormone Binding. There are three subgroups in this class: (i) No Hormone Binding. This is the most common abnormality observed and is characterized by unmeasurable specific binding of 3H 1,25(OH)₂D₃ to either intact cells, nuclei, or cell extracts (66,67,70,72,74,88,89,91-94,102,103,105,110,111). Studies in several kindreds with this defect (including an extended kindred with 8 patients studied) revealed undetectable levels of VDR by immunoblots on an immunoradiometric assay in most kindreds (94,102,103,111,112). DNA from these affected subjects exhibited a single base mutation that was different in each kindred resulting in a premature stop codon. The truncated VDRs produced, lacked hormone binding or both hormone and DNA binding domains (Figure 7) (88,89,91,112). The recreated mutant VDR cDNA was expressed in mammalian cells, and the resulting mutant VDR was demonstrated to be the truncated protein that exhibited no specific hormone binding. In cells cultured from parents of some patients, expected to be obligate heterozygotes, binding of 3H 1,25(OH)₂D₃, VDR protein, and mRNA content of cells ranged from the lower limit of normal to about half the normal level.

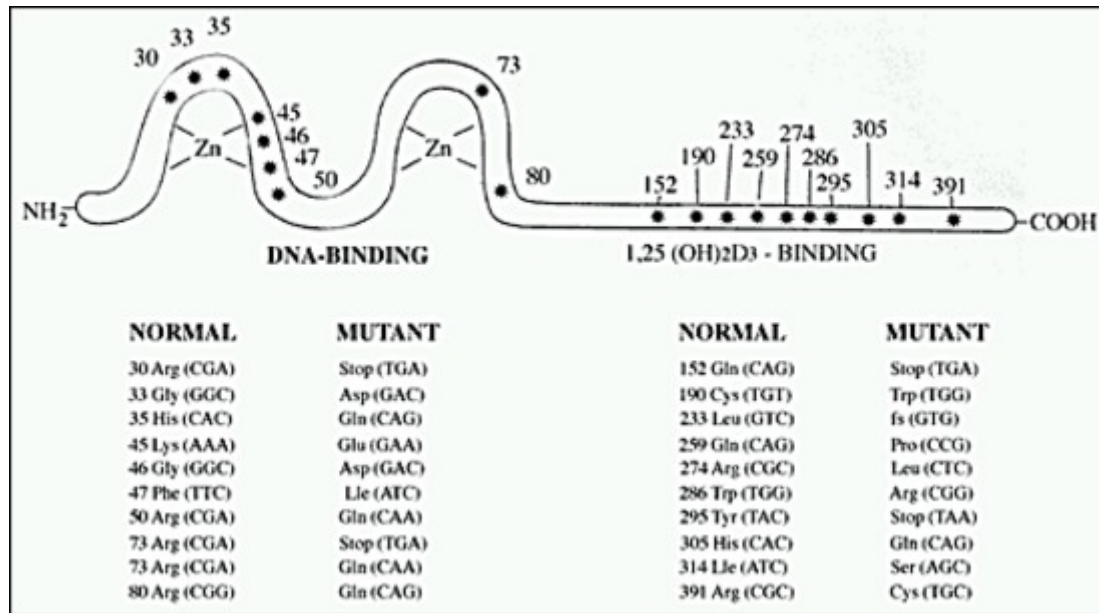


Figure 7

Schematic presentation of homozygous mutation in the VDR protein in simple hereditary resistance to 1,25(OH)₂D. The asterisks depict sites of amino acid substitutions due to point mutation and codon changes, using the numbering system of Baker et (11); fs-frame shift.

In one patient representing a kindred with no hormone binding, a missense mutation resulted in the substitution of the hydrophobic basic arginine 274 by the hydrophilic nonpolar leucine in the hormone binding region (111) (Figure 7). In this patient, normal transcription could be elicited by 1000-fold higher concentrations of calcitriol than needed for the wild-type receptor. However, no *in vivo* or *in vitro* stimulation of 25(OH)D-24-hydroxylase could be obtained by high concentrations of 1,25(OH)₂D₃ (see below).

Two siblings without alopecia and no response to any dose of 1,25(OH)₂D *in vivo* and *in vitro* had a missense mutation that caused a substitution of tryptophan by arginine at amino acid 286 of the VDR (94). This substitution in a normal size VDR abolished completely the binding of 1,25(OH)₂D to its receptor. The tryptophan in this position is critical for the positioning of calcitriol in the VDR as was unveiled by the three dimensional arrangement of the VDR and its ligand based on its crystal structure (113).

(ii) Defective Hormone Binding Capacity. In a patient representing one kindred, the number of binding sites in nuclei and soluble cell extracts was 10% of control, with an apparent normal affinity (67,70,110). Recently, a boy with total alopecia, severe rickets and growth retardation was found to have two heterozygote different molecular defects in the ligand binding domain (95c). The patient VDR had a low hormone binding capacity, 10% to 30% of controls, with normal affinity and a marked deficient stimulation of 25(OH)D₃-24-hydroxylase. The recreated mutations, each one tested

separately in vitro, showed also deficient heterodimerization as well as different transactivation of two gene promoters. This patient, similar to another one described more than 20 years ago, could be completely cured by very high doses of 25(OH) vitamin D, 250 µg a day initially, followed by 100 µg/day and then 75 µg/day as a maintenance dose for years, plus modest calcium supplementation. In both patients, it could be shown that during remission (normocalcemia, normophosphatemia, normal iPTH), 1,25(OH)₂D production is driven by the substrate, i.e., 25(OH) vitamin D concentrations.

An additional patient with hereditary resistance to 1,25(OH)₂D and alopecia was found to have compound heterozygous mutations in the VDR (95d). This girl's cultured fibroblasts were found to have about 30% binding sites of 1,25(OH)₂D in comparison to her parents or normal controls. However, RXR heterodimerization, co-activators interaction and gene transactivation were completely abolished, and no response in vitro to high doses of 1,25(OH)₂D₃ was observed. Treatment with 3,000mg of calcium carbonate orally per day and 3µg/kg of calcitriol caused some improvement in the clinical features and biochemical parameters.

(iii) Defective Hormone Binding Affinity. Binding affinity of tritiated calcitriol was reduced 20- to 30-fold, with normal capacity, in soluble dermal fibroblast extracts from one kindred (76). An additional patient, representing a different kindred had a modest decrease of VDR affinity when measured at 0°C (90).

Deficient Nuclear Uptake. The following features characterize the hormone-receptor-nuclear interaction in this defect: normal or near normal binding capacity and affinity of 3H 1,25(OH)₂D₃ to soluble cell extracts with low to unmeasurable hormone uptake into nuclei of intact cells (65,70,80,83,86). These features were demonstrated in skin-derived fibroblasts in all kindreds, in cells cultured from a bone biopsy of one patient (110a), and in EB-transformed lymphoblasts of one patient (83). Occupied VDR obtained from fibroblast extracts of two kindreds demonstrated normal binding to nonspecific DNA cellulose (100). Immuno-cytological studies in fibroblasts of a patient with this defect showed that immediately after 1,25(OH)₂D₃ treatment, VDR accumulated along the nuclear membrane with no nuclear translocation (115). Patients with this defect included a kindred with normal hair and several kindreds with total alopecia. Finally, almost all patients responded with a complete clinical remission to high doses of vitamin D and its active 1α-hydroxylated metabolites.

Attempts to characterize the molecular defect were carried in six kindreds. In three of them, no mutation in the coding region of the VDR gene was observed (83, and personal communication). Studies in three kindreds, revealed a normal molecular mass and quantitative expression of the VDR (86). Complete sequencing of the VDR coding region revealed a different single nucleotide mutation in each kindred, in a region that is considered to play a role in heterodimerization of VDR with RXR (Figure 7) (86,91). Thus, it has been suggested that these patients' receptors have defects that compromise RXR heterodimerization, which is essential for nuclear localization and probably for recognition of the vitamin D responsive element as well. The fact that no mutation in the VDR coding region was observed in three additional kindreds with the same phenotypical defect may suggest that the genetic defect affects another component of the receptor effector system that is essential for the VDR function as a nuclear transcription factor. It has been shown that coactivation complexes are essential for the ligand induced transactivation of VDR (116).

Deficient coactivators of the calcitriol-VDR complex. A patient with simple hereditary resistance to 1,25(OH)₂D without alopecia was described (95). Sequencing of the VDR-DNA revealed a missense mutation in the ligand binding domain that caused a substitution of glutamic acid to lysine

at amino acid 120. This receptor exhibits many normal properties including calcitriol binding, dimerization and binding to vitamin D response elements in the DNA, but a marked impairment in binding coactivators that are essential for the transactivation of the hormone receptor complex and the initiation of the physiological response (95).

Defects in DNA binding region

Deficient Binding to DNA. Cell preparations derived from patients with this defect demonstrate normal or near normal binding capacity and affinity for $3H$ $1,25(OH)_2D_3$ to nuclei of intact cells and soluble cell extracts, as well as normal molecular size. Hormone receptor complexes, however, have decreased affinity to nonspecific DNA (75,81,85,106,107). A single nucleotide missense mutation within exon 2 or 3, encoding the DNA binding domain of the VDR, was demonstrated in genomic DNA isolated from dermal fibroblasts and/or EB-transformed lymphoblasts from ten unrelated kindreds (71,81,85,87,89,101,108,114). Eight different single nucleotide mutations were found in the ten kindreds (Figure 7). Two apparently unrelated kindreds share the same mutation (81,108). All point mutations caused a single substitution of an amino acid that resides in the region of the two zinc fingers of the VDR protein that are essential for the functional interaction of the hormone-receptor complex with DNA. Interestingly, all these altered amino acids are highly conserved in the steroid receptor superfamily that includes the receptors for steroid hormones, thyroid hormones and retinoic acid.

Studies on cells obtained from parents and some of the siblings of these patients revealed, as expected, a heterozygous state, i.e., expression of both normal and defective forms of VDR as well as normal and mutant gene sequences (94,101,107), but without any clinical and biochemical abnormalities.

In vitro posttranscriptional and transcriptional effect of $1,25(OH)_2D_3$

In vitro bioeffects of the hormone on various cells in patients with simple hereditary resistance to $1,25(OH)_2D_3$ have been assayed mainly by two procedures, induction of $25(OH)D-24$ -hydroxylase and inhibition of mitogen stimulated PBM cells.

$1,25(OH)_2D_3$ induces $25(OH)D-24$ hydroxylase activity in skin-derived fibroblasts (66-69,72,75-77,83,85,92-95,102,103,107,108,114,117), mitogen-stimulated lymphocytes (104), and cells originating from bone (110a,118) in a dose-dependent manner. In cells from normal subjects, maximal and half-maximal induction of the enzyme was achieved by 10^{-8} and 10^{-9} M concentrations of $1,25(OH)_2D_3$, respectively. Dermal fibroblast or PBM cells from patients with no calcemic response to maximal doses of vitamin D or its metabolites in vivo did not show any $25(OH)D-24$ -hydroxylase response to very high concentration of $1,25(OH)_2D_3$ in vitro, while dermal fibroblasts from patients with a calcemic response to high doses of vitamin D or its metabolites in vivo showed inducible 24 -hydroxylase with supraphysiological concentrations of $1,25(OH)_2D_3$ in vitro. Physiological concentrations of $1,25(OH)_2D_3$ partially inhibit mitogen-induced DNA synthesis in peripheral lymphocytes with a half maximal inhibition achieved at 10^{-10} M of the hormone (78,105). Mitogen stimulated lymphocytes from several kindreds with defects characterized as no hormone binding or deficient binding to DNA, with no calcemic response to high doses of vitamin D and its metabolites in vivo, showed no inhibition of lymphocyte proliferation in vitro with concentrations of up to 10^{-6} M $1,25(OH)_2D_3$. Additional methods to measure bioeffects of $1,25(OH)_2D_3$ on various cells in vitro were carried out only in few patients and included inhibition of dermal fibroblasts proliferation

(69), induction of osteocalcin synthesis in cells derived from bone (118), a mitogenic effect on dermal fibroblasts (115), and stimulation of cGMP production in cultured skin fibroblasts (119). It is noteworthy that in all assays mentioned and without exception, each patient's cell showed severely deficient responses.

With the elucidation of the molecular defects in simple hereditary resistance to $1,25(\text{OH})_2\text{D}$, the transactivation abilities of naturally occurring mutant or recreated mutant VDRs were evaluated in a transcriptional activation assay. In this assay a gene promoter responsive to VDR is fused to a gene reporter that its message is easily measured, and the plasmid is transfected into patients or normal cells (81,83,85,102,103,107,11). Treating normal transfected cells with $1,25(\text{OH})_2\text{D}_3$ caused a concentration-dependent induction of transcription. No induction of transcription was observed in cells originating from patients with defects characterized as no hormone binding (102,103,111) or deficient binding to DNA (81,85,107,108). Moreover, in a cotransfection assay, the addition of a normal human VDR cDNA expression vector to the transfected plasmid that directed synthesis of a normal VDR, restored hormone responsiveness of resistant cells. Finally, in a patient characterized as deficient nuclear uptake defect, no mutation was identified within the coding region of the VDR gene; no induction of 25(OH)D-24-hydroxylase activity by up to 10^{-6} $1,25(\text{OH})_2\text{D}_3$ was observed in cultured skin fibroblasts, but there was normal transactivation by $1,25(\text{OH})_2\text{D}_3$ in the transcriptional activation assay (83).

Cellular Defects and Clinical Features

Normal hair was described with most phenotypes of the cellular defects the exception being patients with deficient hormone binding capacity and affinity, but this could be due to the fact that only one or two kindreds were described per subgroup. Normal hair is usually associated with a milder form of the disease, as judged by the age of onset, severity of the clinical features, and usually the complete clinical and biochemical remission on high doses of vitamin D or its metabolites. Notable exceptions are 3 kindreds (4 patients), two of them, without alopecia that displayed resistance both in vivo (no clinical remission on circulating calcitriol level up to 100 times the mean normal adult values) and in vitro (no induction of 25(OH)D-24-hydroxylase activity in dermal fibroblasts by up to 10^{-8} M $1,25(\text{OH})_2\text{D}_3$) (77,94,95). Only approximately half of the patients with alopecia have shown satisfactory clinical and biochemical remission to high doses of vitamin D or its active 1 α -hydroxylated metabolites, but the dose requirement is ~10-fold higher than in patients with normal hair (96).

It seems that patients defects characterized as deficient hormone binding affinity and deficient nuclear uptake achieve complete clinical and biochemical remission on high doses of vitamin D or its active 1 α -hydroxylated metabolites. Most of the patients with other types of defects could not be cured with high doses of vitamin D or its metabolites. However, it should be emphasized that not all of the patients received treatment for a long enough period of time and with sufficiently high doses (see Treatment, below).

Diagnosis

Clinical features of early onset rickets with no history of vitamin D deficiency, total alopecia, parental consanguinity, additional siblings with the same disease, serum biochemistry of hypocalcemic rickets, elevated circulating levels of $1,25(\text{OH})_2\text{D}$, and normal to high levels of 25(OH)D (Table 2) support the diagnosis of simple hereditary resistance to $1,25(\text{OH})_2\text{D}$. The issue becomes more complicated when the clinical features are atypical, i.e., late onset of the disease, sporadic cases, and normal hair. Failure of a therapeutic trial with calcium and/or physiological replacement doses of

vitamin D or its metabolites may support the diagnosis but the final direct proof requires the demonstration of a cellular, molecular, and functional defect in the VDR-effector system.

Based on the clinical and biochemical features, the following additional disease states should be considered: (1) extreme calcium deficiency: a seemingly rare situation described in a group of children from a rural community in South Africa, who consumed an exceptionally low calcium diet of 125 mg/day (19). All had severe bone disease with histologically proven osteomalacia, biochemical features of hypocalcemic rickets with elevated serum levels of $1,25(\text{OH})_2\text{D}$, and sufficient vitamin D. Calcium repletion caused complete clinical and biochemical remission. Nutritional history and the response to calcium supplementation support this diagnosis. (2) Severe vitamin D deficiency: during initial stages of vitamin D therapy in children with severe vitamin D-deficient rickets, the biochemical picture may resemble $1,25(\text{OH})_2\text{D}$ resistance, i.e., hypocalcemic rickets with elevated serum calcitriol levels. This may represent a “hungry bone syndrome,” i.e., high calcium demands of the abundant osteoid tissue becoming mineralized. This is a transient condition that may be differentiated from simple hereditary resistance to $1,25(\text{OH})_2\text{D}$ by a history of vitamin D deficiency and the final therapeutic response to replacement doses of vitamin D.

Treatment

In about half of the kindreds with simple hereditary resistance to $1,25(\text{OH})_2\text{D}$, the bioeffects of $1,25(\text{OH})_2\text{D}_3$ were measured in vitro (see above). An invariable correlation (with one exception) was documented between the in vitro effect and the therapeutic response in vivo; i.e., patients with no calcemic response to high levels of serum calcitriol showed no effects of $1,25(\text{OH})_2\text{D}_3$ on their cells in vitro (either induction of $25(\text{OH})\text{D}$ -24-hydroxylase or inhibition of lymphocyte proliferation) and vice versa. If the predictive therapeutic value of the in vitro cellular response to $1,25(\text{OH})_2\text{D}_3$ could be substantiated convincingly, it may eliminate the need for time consuming and expensive therapeutic trials with massive doses of vitamin D or its active metabolites. In the meantime, it is mandatory to treat every patient with this disease irrespective of the type of receptor defect.

An adequate therapeutic trial must include vitamin D at a dose that is sufficient to maintain high serum concentrations of $1,25(\text{OH})_2\text{D}_3$ as the patients can produce high hormone levels if supplied with enough substrate. If high serum calcitriol levels are not achieved, it is advisable to treat with 1 α -hydroxylated vitamin D metabolites in daily doses of up to 6 mg/kg weight or a total of 30-60 mg and calcium supplementation of up to 3 g of elemental calcium daily; therapy must be maintained for a period sufficient to mineralize the abundant osteoid (usually 3-5 months). Therapy may be considered a failure if no change in the clinical, radiological, or biochemical parameters occurs during continuous and frequent follow up while serum $1,25(\text{OH})_2\text{D}$ concentrations are maintained at ~100 times the mean normal range.

In some patients with no response to adequate therapeutic trials with vitamin D or its metabolites, a remarkable clinical and biochemical remission of their bone disease, including catch-up growth, was obtained by treatment with large amounts of calcium. This was achieved by long-term (months) intracaval infusions of up to 1000 mg of calcium daily (84,94, 118,120,121). Another way to increase calcium input into the extra cellular compartment is to increase net gut absorption, independent of vitamin D, by increasing calcium intake (122). This approach is limited by dose and patient tolerability and was actually used successfully in only very few patients.

Several patients have shown unexplained fluctuations in response to therapy or in presentation of the disease. One patient after a prolonged remission became completely unresponsive to much higher doses of active 1 α -hydroxylated vitamin D metabolites (67), and another patient seemed to show amelioration of resistance to 1,25(OH) $_2$ D $_3$ after a brief therapeutic trial with 24,25(OH) $_2$ D (60). In several patients, spontaneous healing occurred in their teens (73) or rickets did not recur for 14 years after cessation of therapy (80).

Animal Models

Some New World primates (marmoset and tamarins) that develop osteomalacia in captivity are known to have high nutritional requirements for vitamin D and maintain high serum levels of 1,25(OH) $_2$ D, thus exhibiting a form of end-organ resistance to 1,25(OH) $_2$ D (123-126). Cultured dermal fibroblasts and EB-virus transformed lymphoblast have shown deficient hormone binding capacity and affinity (123,124). It has been observed that marmoset lymphoblasts contain a soluble protein of 50-60 kDa that binds 1,25(OH) $_2$ D $_3$ with a low affinity but high capacity and thus may serve as a sink that interferes with the hormone binding and its cognate receptor (127). The same group described another protein present in the nuclear extract of these cells capable of inhibiting normal VDR-RXR binding to the vitamin D response element (128).

It is of interest that these New World primates also exhibit a compensated hereditary end-organ resistance to the true steroid hormones including glucocorticoids, estrogens, and progestins (129). This of course raises the interesting possibility that the defect in the hormone-receptor-effector system involves an element shared by all the members of this superfamily of ligand modulated transcription factors.

Recently, VDR knock out mice have been created by targeted ablation of the first or second zinc finger (98,99) Only the homozygote mice were affected. Though phenotypically normal at birth, after weaning however, they become hypocalcemic, develop secondary hyperparathyroidism, rickets, osteomalacia and progressive alopecia. The female mice with ablation of the first zinc finger are infertile and show uterine hypoplasia and impaired folliculogenesis. Otherwise, both VDR cell mutant mice show clinical, radiological, histological and biochemical features that are identical to the human disease. Supplementation with a calcium enriched diet can prevent or treat most of the disturbances in mineral and bone metabolism in these animal models except alopecia (100).

It is of interest that targeting expression of the human VDR to keratinocytes of VDR null mice prevented alopecia (130).

CONCLUDING REMARKS

Acquired vitamin D deficiency, especially moderate or mild (the so called vitamin D insufficiency) are much more common than previously appreciated. It may affect more than 50% of populations with limited sunshine exposure and no vitamin D supplementation. In the less severe forms of vitamin D deficiency, there is no defective bone matrix mineralization, but an increased bone loss secondary to the perturbations in calcium homeostasis and secondary hyperparathyroidism, which accelerates the development of osteoporosis in post-menopausal women, the elderly population at large in general and some subgroups in particular. Osteomalacia, which marks severe vitamin D deficiency, may affect some of these patients as well. Based on these observations, it is highly recommended for anyone taking care of the elderly, especially the house or bed bound, institutionalized or patients with physical or mental deficiencies that limit their free movement, to consider and evaluate their vitamin D status. It seems to be good clinical practice and cost effective to recommend vitamin D supplementation for populations at risk, as a measure to prevent the

deleterious effects of vitamin D deficiency on the musculoskeletal system.

Hereditary deficiencies in vitamin D action are rare disorders. The importance of studying these diseases, stems from the fact that they represent a naturally occurring experimental model that helps to elucidate the function and importance of vitamin D and the VDR-effector system in human beings *in vivo*.

VDRs are abundant and widely distributed among most tissues studied and multiple effects of calcitriol are observed on various cell functions *in vitro*. Yet, the clinical and biochemical features in patients with simple hereditary 1,25(OH)₂D deficiency and resistance seems to demonstrate that the most important disturbances of clinical relevance are perturbations in mineral and bone metabolism. This emphasizes the pivotal role of 1,25(OH)₂D in transepithelial net calcium fluxes. Moreover, the fact that in patients with extreme end-organ resistance to calcitriol, calcium infusions correct the disturbances in mineral homeostasis and cure the bone disease may support the notion that defective bone matrix mineralization is secondary to disturbances in mineral homeostasis. Characterization of the molecular, cellular, and functional defects of the different natural mutants of the human VDR in simple hereditary 1,25(OH)₂D deficiency and resistance, demonstrates the essentiality of the VDR as the mediator of calcitriol action and the importance and function of its different domains, i.e. binding of the hormone, an RXR isoform, and binding to a specifically defined DNA region, as well as coactivators and corepressor complexes. Thus, studies in patients with hereditary deficiencies in vitamin D action are the essential link between molecular defects and physiological relevant effects in human beings.

References

1. Ohyama, Y., Noshiro, M., Eggersten, G., Gotoh, O., Kato, Y., Bjorkhem, I., and Okuda, K. (1993). Structural characterization of the gene encoding rat 25-hydroxyvitamin D₃ 24-hydroxylase. *Biochemistry* 32, 76-82.
2. Akeno, N., Saikatsu, S., Kawane, T., and Horiuchi, N. (1997). Mouse vitamin D-24 hydroxylase molecular cloning, tissue distribution, and transcriptional regulation by 1α,25-Dihydroxyvitamin D₃. *Endocrinology* 138, 2233-2240.
3. Fu, G.K., Portale, A.A., and Miller, W.L. (1997). Complete structure of the human gene for the vitamin D 1α-hydroxylase. *Cell. Biol.* 16, 1499-1507.
4. Monkawa, T., Yoshida, T., Wakino, S., Shinki, T., Anazawa, H., DeLuca, H.F., Suda, T., Hayashi, M., and Sarut, T. (1997). Molecular cloning of cDNA and genomic DNA for human 25-hydroxyvitamin D₃ 1α-hydroxylase. *Biochem. Biophys. Res. Commun.* 239, 527-533.
5. Shinki, T., Shimada, H., Wakino, S., Anazawa, H., Hayashi, M., Saruta, T., DeLuca, H.F., and Suda, T. (1997). Cloning and expression of rat 25-hydroxyvitamin D₃-1α-hydroxylase cDNA. *Proc. Natl. Acad. Sci. (USA)* 94,12920-12925.
6. Takeyama, K., Kitanaka S., Sato, T., Kobori, M. Yanagisawa, J., and Kato, S. (1997). 25-hydroxyvitamin D₃ 1α-hydroxylase and vitamin D synthesis. *Science* 277, 1827-1830.
7. Jehan, F., Ismail, R., Hanson, K., and DeLuca, H.F. (1998). Cloning and expression of the chicken 25-hydroxyvitamin D₃ 24-hydroxylase

cDNA. *Biochem. Biophys. Acta.* 1395, 259-265.

8. Jones, G., Ramshaw, H. Zhang, A., Cook, R., Byford, V., White, J., and Petkovich, M. (1999). Expression and activity of vitamin D-metabolizing cytochrome P450s (CYP1(and CYP 24) in human nonsmall cell lung carcinomas. *Endocrinology* 140, 3303-3310.
9. Murayama, A., Takeyama, K., Kitanaka, S., Kodera, Y., Kawaguchi, Y., Hosoya, T., and Kato, S. (1999). Positive and negative regulations of the renal 25-hydroxyvitamin D₃ 1 α -hydroxylase gene by the parathyroid hormone, calcitonin and 1 α ,25(OH)₂D₃ in intact animals. *Endocrinology* 140, 2224-2231.
10. Evans, R. M. (1988). The steroid and thyroid hormone receptor superfamily. *Science* 240, 889-895.
11. Baker, A. R., McDonnell, D. P., Huges, M., Crisp, T. M., Mangelsdorf, D. J., Haussler, M. R., Pike, J. W., Shine, J., and O'Malley, B. W. (1988). Cloning and expression of full-length cDNA encoding human vitamin D receptor. *Proc. Natl. Acad. Sci. (USA)* 85, 3294-3298.
12. Burmester, J. K., Maeda, N., and DeLuca, H. F. (1988). Isolation and expression of rat 1,25-dihydroxyvitamin D₃ receptor DNA. *Proc. Natl. Acad. Sci. (USA)* 85, 1005-1009.
13. Ozur, K., Sone, T., and Pike, J. W. (1991). The genomic mechanism of action of 1,25-dihydroxyvitamin D₃. *J. Bone Miner. Res.* 6, 1021-1027.
14. DeLuca, H. F. (1984). The metabolism, physiology and function of vitamin D. In: "Vitamin D: Basic and Clinical Aspects" (R. Kumar, ed.), pp. 1. Martinus Nijhoff, Boston.
15. Mayer, E., Kadowabi, S., Williams, G., and Norman, A. W., (1984). Mode of action of 1,25-dihydroxyvitamin D. In: "Vitamin D: Basic and Clinical Aspects" (R. Kumar, ed.), pp. 259. Martinus Nijhoff, Boston.
16. Reichel, H., Koeffler, P., and Norman, A. W. (1989). The role of the vitamin D endocrine system in health and disease. *N. Engl. J. Med.* 320, 980-991.
17. Owen, T. A., Aronow, M. S., Barone, L. M., Bettencourt, B., Stein G. S., and Lian, J. B. (1991). Pleiotropic effects of vitamin D on osteoblast gene expression are related to the proliferative and differentiated state of bone cell phenotype: Dependency upon basal levels of gene expression, duration of exposure and bone matrix competency in normal rat osteoblast culture. *Endocrinology* 129, 3139-3146.
19. Pettifor, J. M., Ross, F. P. Travers, R., Glorieux, F. H., and DeLuca, H. F. (1981). Dietary calcium deficiency: A syndrome associated with bone deformities and elevated serum 1,25-dihydroxyvitamin D concentrations. *Metab. Bone Dis. Relat. Res.* 2, 301-305.
20. Teitelbaum, S. L., and Bollough, P. G. (1979). The pathophysiology of bone and disease. *Am. J. Pathol.* 96, 283.
21. Parfitt, A. M. (1983). The physiologic and clinical significance of bone histomorphometric data. In: "Bone Histomorphometric Data" (R. Recker, ed.), pp. 143. CRC Press, Boca Raton, FL.
22. Parfitt, A.M., Drezner, M.K., Glorieux, F.H., Kanis, J.A., Malluche, H., Meunier, P.J., Ott, S.M., and Recker, R.R. (1987). Bone

- histomorphometry: standardization of nomenclature, symbols, and units. Report of the ASBMR histomorphometry nomenclature committee. *J. Bone Miner. Res.* 2, 595-610.
23. Cole, D. E. C., Carpenter, T. O., and Gundberg, C. M. (1985). Serum osteocalcin concentrations in children with metabolic bone disease. *J. Pediatr.* 106, 770-776.
24. Gill, R.K., Ramadan, D., Chesnut, C.H., IV, Lee, M.H., Patel, S.B., and Bell, N.H. (2000) Vitamin D-25-hydroxylase deficiency does not map to the CYP27 or CYP2D6 gene loci. *J. Bone Miner. Res.* 15, S1-S329.
25. Holick, M.F. (1994). McCollum award lecture 1994. Vitamin D: new horizons for the 21st century. *Am. J. Clin. Nutr.* 60, 619-630.
26. Holick, M.F. (1995). Environmental factors that influence the cutaneous production of vitamin D. *Am. J. Clin. Nutr.* 61 (suppl 3), 638S-645S.
27. Lips, P. (2001). Vitamin D deficiency and secondary hyperparathyroidism in the elderly: consequences for bone loss and fractures and therapeutic implications. *Endocr. Rev.* 22, 477-501.
28. Krall, E.A., Sahyoun, N., Tannenbaum, S., Dallal, G.E., and Dawson-Hughes, B. (1989). Effect of vitamin D intake on seasonal variations in parathyroid secretion in postmenopausal women. *N. Engl. J. Med.* 321, 1777-1783.
29. Thomas, M.K., Lloyd-Jones, D.M., Thadhani, R.I., Shaw, A.C., Deraska, D.J., Kitch, B.T., Vamvakas, E.C., Dick, I.M., Prince, R.L., and Finkelstein, J.S. (1998). Hypovitaminosis D in medical inpatients. *N. Engl. J. Med.* 338, 777-783.
30. Lips, P., Duong, T., Oleksik, A., Black D., Cummings, S., Cox, D., and Nickelsen, T. (2001). A global study of vitamin D status and parathyroid function in postmenopausal women with osteoporosis: baseline data from the Multiple Outcomes of Raloxifene Evaluation Clinical Trial. *J. Clin. Endocrinol. Metab.* 86, 1212-1221.
31. Ross, A.C., Manson, J.E., Abrams, S.A., Aloia, J.F., Brannon, P.M., Clinton, S.K., Durazo-Arvizu, R.A., Gallagher, J.C., Gallo, R.L., Jones, G., Kovacs, C.S., Magne, S.T., Rosen, C.J., and Shapses, S.A. (2011). The 2011 report on dietary reference intakes for calcium and vitamin D from the Institute of Medicine. What clinicians need to know. *J. Clin. Endocrinol. Metab.* 96, 53-58.
32. Holick, M.F., Binkley, N.C., Bischoff-Ferrari, H.A., Gordon, C.M., Hanley, D.A., Heaney, R.P., Murad, M.H., and Weaver, C.M. (2011). Evaluation, treatment, and prevention of vitamin D deficiency. An Endocrine Society clinical practice guideline. *J. Clin. Endocrinol. Metab.* 96, 1911-30.
33. Khaw, K.T., Sneyd, M.J., and Compston, J. (1992). Bone density, parathyroid hormone and 25-hydroxyvitamin D concentrations in middle-aged women. *Br. Med. J.* 305, 273-277.
34. Ooms, M.E., Lips, P., Roos, J.C., van der Vijgh, W.J.F., Popp-Snijders, C., Bezemer, P.D., and Bouter, L.M. (1995). Vitamin D status and sex hormone binding globulin: determinants of bone turnover and bone mineral density in elderly women. *J. Bone Miner. Res.* 10, 1177-1184.
35. Mezquita-Raya, P., Munoz-Torres, M., De Dios Luna, J., Luna, V., Lopez-Rodriguez, F., Torres-Vela, E., and Escobar-Jimenez, F. (2001).

- Relation between vitamin D insufficiency, bone density, and bone metabolism in healthy postmenopausal women. *J. Bone Miner. Res.* 16, 1408-1415.
36. Collins, D., Jasani, C., Fogelman, I., and Swaminathan, R. (1998). Vitamin D and bone minimal density. *Osteoporos Int.* 8, 110-114.
37. Delmas, P.D., and Meunier, P.J. (1992). Vitamin D₃ and calcium to prevent hip fractures in elderly women. *N. Engl. J. Med.* 327, 1637-1642.
38. Bischoff-Ferrari, H.A., Giovannucci, E., Willett, W.C., Dietrich, T., and Dawson-Hughes, B. (2006). Estimation of optimal serum concentrations of 25-hydroxy vitamin D for multiple health outcomes. *Am. J. Clin. Nutr.* 84, 18-28.
- 38a. Bischoff-Ferrari, H.A., Willett, W.C., Wong, J.B., Stuck, A.E., Stachelin, H.B., Oscar, E.J., Thomas, A., Kiel, D.P., and Henschkowski, J. (2009). Prevention of nonvertebral fractures with oral vitamin D and dose dependency. A meta-analysis of randomized controlled trials. *Arch. Intern. Med.* 169, 551-561.
39. Davies, M., Mawer, E.B., Hann, J.T., Stephens, W.P., and Tayler J.L. (1985). Vitamin D prophylaxis in the elderly: a simple, effective method suitable for large populations. *Age Ageing* 14, 349-354.
40. Weisman, Y., Schen, R.J., Eisenberg, Z., Amarilio, N., Graff, E., Edelstein-Singer, M., Goldray, D., and Harell, A. (1986). Single oral high-dose vitamin D₃ prophylaxis in the elderly. *J. Am. Geriatr. Soc.* 34, 515-518.
41. Khaw, K.T., Scragg, R., and Murphy S. (1994). Single-dose cholecalciferol suppresses the winter increases in parathyroid hormone concentrations in healthy older men and women. *Am. J. Clin. Nutr.* 59, 1040-1044.
42. Heikinheimo R.J., Inkovaara, J.A., Harju, E.J., Haavisto, M.V., Kaarela, R.H., Kataja, J.M., Kokko, A.M.L., Kolho, L.A., and Rajala, S.A. (1992). Annual injection of vitamin D and fractures of aged bones. *Calci. Tissue Int.* 51, 105-110.
- 42a. Sanders, K.M., Stuart, A.L., Williamson, E.J., Simpson, J.A., Kotowicz, M.A., Young, D., and Nicholson, G.C. (2010). Annual high-dose oral vitamin D and falls and fractures in older women. A randomized controlled trial. *JAMA* 303, 1815-1822.
- 42b. Prader, A., Illig, R., and Heierli, E. (1961). Eline besondere Form der primären/vitamin D-resistenten Rachitis mit Hypocalcämie und autosomal-dominanten Erbgang: Die hereditäre Pseudo-Mangelrachitis. *Hely. Paediatr. Acta* 16, 452-468.
43. Fraser, D., Kooh, S. W., Kind, P., Tanaka, Y., and DeLuca, H. F. (1973). Pathogenesis of hereditary vitamin D-dependent rickets: An inborn error of metabolism involving defective conversion of 25-hydroxyvitamin D to 1,25-dihydroxy-vitamin D. *N. Engl. J. Med.* 289, 817-822.
44. Delvin, E. E., Glorieux, F. H., Marie, P. J., and Pettifor, J. M. (1981). Vitamin D dependency: Replacement therapy with calcitriol. *J. Pediatr.* 99, 26-34.
45. Labuda, M., Morgan, K., and Glorieux, F. H. (1990). Mapping autosomal recessive vitamin D-dependency Type I to chromosome 12q14 by linkage analysis. *Am. J. Hum. Genet.* 46, 28-36.

46. De Braekeleer, M., and Larochell, J. (1991). Population genetics of vitaminD-dependent rickets in Northeastern Quebec. *Ann. Hum. Genet.* 55, 283-290.
47. Fu, G.K., Lin, D. Zhang, M.Y., Bikle, D.D., Shackleton, C.H., Miller, W.L., and Portale, A.A. (1997). Cloning of human 25-hydroxyvitamin D-1 α -hydroxylase and mutations causing vitamin D-dependent rickets type 1. *Endocrinology* 11, 1961-1970.
48. St. Arnaud, R., Messerlian, S., Moir, J.M., Omdahl, J.L., and Glorieux, F.H. (1997). The 25-hydroxyvitamin D 1 α -hydroxylase gene maps to the pseudovitamin D deficiency rickets (PDDR) disease locus. *J. Bone. Miner. Res.* 12,1552-1559.
49. Wang, J.T., Lin, C.J., Burrige, S.M., Fu, G.K., Labuda, M., Portale, A.A., and Miller, W.L. (1998). Genetics of vitamin D 1 α -hydroxylase deficiency in 17 families. *Am. J. Hum. Genet.* 63, 1694-1702.
50. Yoshida, T., Monkawa, T., Tenehouse, H.S., Goodyear, P., Shinki, T., Suda, T., Wakino, S., Hayashi, M., and Saruta, T. (1998). Two novel 1 α -hydroxylase mutations in French-Canadians with vitamin D dependency rickets type I. *Kidney Int.* 54, 1437-1443 (comments).
51. Kitanaka, S., Takeyama, K., Murayama, A., Sato, T., Okumura, K., Nogami, M., Hasegawa, Y., Niimi, H., Yanagisawa, J., Tanaka, T., and Kato, S. (1998). Inactivating mutations in the 25-hydroxyvitamin D₃ 1 α -hydroxylase gene in patients with pseudovitamin D-deficiency rickets. *N. Eng. J Med.* 338, 653-661 (comments).
- 51a. Kitanaka, S., Murayama, A., Sakaki, T., Inoue, K., Seino, Y., Fukumoto, S., Shima, M., Yukizane, S., Takayanagi, M., Niimi, H., Takeyama, K. and Kato, S. (1999). No enzyme activity of 25-hydroxyvitamin D₃ 1 α -hydroxylase gene product in pseudovitamin D-deficiency rickets, including that with mild clinical manifestation. *J. Clin. Endocrinol. Metab.* 84, 4111-4117.
52. Smith, S.J., Rucka, A.K., Berry, J.L., Davies, M., Mylchreest, S. Paterson, C.R., Heath, D.A., Tassabehji, M., Read, A.P., Mee, A.P., and Mawer, E.B. (1999). Novel mutations in the 1 α -hydroxylase (P450c1) gene in three families with pseudovitamin D-deficiency rickets resulting in loss of functional enzyme activity in blood derived macrophages. *J. Bone Miner. Res.* 14,730-739.
53. Glorieux, F. H., Arabian, A., and Delvin, E. E. (1995). Pseudo-vitamin D deficiency: Absence of 25-hydroxyvitamin D 1 α -hydroxylase activity in human placenta decidual cells. *J. Clin. Endocrinol. Metab.* 80, 2255-2258.
54. Weisman, Y., Harell, A., Edelstein, S., David, M., Spierer, Z., and Golander, A. (1979). 1 α , 25-dihydroxyvitamin D₃ and 24,25-dihydroxyvitamin D₃ in vitro synthesis by human decidua and placenta. *Nature* 281, 317-319.
55. Delvin, E. E., and Arabian, A. (1987). Kinetics and regulation of 25-hydroxycholecalciferol 1 α -hydroxylase from cells isolated from human term decidua. *Eur. J. Biochem.* 163, 659-662.
56. Diaz, L., Sanchez, I., Avila, E., Halhali, A., Vilchis, F., and Larrea, F. (2000). Identification of a 25-hydroxyvitamin D₃ 1 α -hydroxylase gene transcription product in cultures of human syncytiotrophoblast cells. *J. Clin. Endocrinol. Metab.* 85,2543-2549.
- 56a. Fox, J., Maunder, E. M. W., Ranall, V. A., and Care, A. D. (1985). Vitamin D dependent rickets type I in pigs. *Clin. Sci.* 69, 541-548.

- 56b. Harmeyer, J. V., Grabe, C., and Winkley, I. (1982). Pseudovitamin D deficiency rickets in pigs. An animal model for the study of familial vitamin D dependency. *Exp. Biol. Med.* 7, 117-125.
- 56c. Dardenne, O., Prudhomme, J.O., Arabian, A., Glorieux, F.H. and St-Arnaud, R. (2001). Targeted inactivation of the 25-hydroxyvitamin D3-1 (alpha)-hydroxylase gene (CYP27-B1) create an animal model of pseudovitamin D-deficiency rickets. *Endocrinology* 142, 3135-3141.
57. Brooks, M. H., Bell, N. H., Love, L., Stern, P. H., Ordei, E., and Queener, S. J. (1978). Vitamin D dependent rickets type II resistance of target organs to 1,25-dihydroxyvitamin D. *N. Engl. J. Med.* 293, 996-999.
58. Marx, S. J., Spiegel, A. M., Brown, E. M., Gardner, D. G., Downs, R. W., Jr., Attie, M., Hamstra, A. J., and DeLuca, H. F. (1978). A familial syndrome of decrease in sensitivity of 1,25-dihydroxyvitamin D. *J. Clin. Endocrinol. Metab.* 47, 1303-1310.
59. Rosen, J. F., Fleischman, A. R., Fineberg, L., Hamstra, A., and DeLuca, H. F. (1979). Rickets with alopecia: An inborn error of vitamin D metabolism. *J. Pediatr.* 94, 729-735.
60. Liberman, U. A., Samuel, R., Halabe, A., Kauli, R., Edelstein, S., Weisman, Y., Papapoulos, S. E., Clemens, T. L., Fraher, L. J., and O'Riordan, J. L. H. (1980). End-organ resistance to 1,25-dihydroxy cholecalciferol. *Lancet* 1, 504-506.
61. Fujita, T., Nomura, M., Okajima, S., and Suzuya, H. (1980). Adult-onset vitamin D-resistant osteomalacia with unresponsiveness to parathyroid hormone. *J. Clin. Endocrinol. Metab.* 50, 927- 931.
62. Sockalsosky, J. J., Westrom, R. A., DeLuca, H. F., and Brown, D. M. (1980). Vitamin D-resistant rickets: End-organ unresponsiveness to 1,25(OH)₂D₃. *J. Pediatr.* 96, 701-703.
63. Tauchiya, Y., Matsuo, N., Cho, H., Kumagai, M., Yasaka, A., Suda, T., Orimo, H., and Shiraki, M. (1980). An unusual form of vitamin-D-dependent rickets in a child: Alopecia and marked end-organ hyposensitivity to biological active vitamin D. *J. Clin. Endocrinol. Metab.* 51, 685-690.
64. Bear, S., Tieder, M., Kohelet, D., Liberman, U. A., Vine, E., Bar-Joseph, G., Gabizon, D., Borochowitz, Z. U., Varon, M., and Modai, D. (1981). Vitamin D resistant rickets with alopecia: A form of end-organ resistance to 1,25-dihydroxyvitamin D. *Clin. Endocrinol.* 14, 395-402.
65. Eil, C., Liberman, U. A., Rosen, J. F., and Marx, S. J. (1981). A cellular defect in hereditary vitamin D-dependent rickets type II: Defective nuclear uptake of 1,25-dihydroxyvitamin D in cultured skin fibroblasts. *N. Engl. J. Med.* 304, 1588-1591.
66. Feldman, D., Chen, T., Cone, C., Hirst, M., Shari, S., Benderli, A., and Hochberg, Z. (1982). Vitamin D resistant rickets with alopecia: Cultured skin fibroblasts exhibit defective cytoplasmic receptors and unresponsiveness to 1,25(OH)₂D₃. *J. Clin. Endocrinol. Metab.* 55, 1020-1025.
67. Balsan, A., Garabedian, M., Liberman, U. A., Eil, C., Bourdeau, A., Guillozo, H., Grimberg, R., DeDeunff, M. J., Lieberherr, M., Guimbaud, P., Broyer, M., and Marx, S. J. (1983) Rickets and alopecia with resistance to 1,25-dihydroxyvitamin D: Two different clinical courses with two different cellular defects. *J. Clin. Endocrinol. Metab.* 57, 824-830.

68. Clemens, T. L., Adams, J. C., Horiuchi, N., Gilchrist, B. A., Cho, H., Ysuchiya, Y., Matsuo, N., Suda, T., and Holick, M. J. (1983). Interaction of 1,25-dihydroxyvitamin D₃ with keratinocytes and fibroblasts from skin of a subject with vitamin D-dependent rickets type II: A model for the study of action of 1,25-dihydroxyvitamin D₃. *J. Clin. Endocrinol. Metab.* 56, 824-830.
69. Griffin, J. E., and Zerwekh, J. E. (1983). Impaired stimulation of 25-hydroxyvitamin D-24-hydroxylase in fibroblasts from a patient with vitamin D-dependent rickets, type II. *J. Clin. Invest.* 72, 1190- 1199.
70. Liberman, U. A., Eil, C., and Marx, S. J. (1983). Resistance to 1,25-dihydroxyvitamin D: Association with heterogeneous defects in cultured skin fibroblasts. *J. Clin. Invest.* 71, 192-200.
71. Malloy, P.J., Weisman, Y., Feldman D. (1994). Hereditary 1 alpha,25-dihydroxyvitamin D-resistant rickets resulting from a mutation in the vitamin D receptor deoxyribonucleic acid-binding domain. *J. Clin. Endocrinol. Metab.* 78, 313-316.
72. Chen, T. L., Hirst, M. A., Cone, C. M., Hochberg, Z., Tietze, H. U., and Feldman, D. (1984). 1,25-Dihydroxyvitamin D resistance, rickets and alopecia: Analysis of receptors and bioresponse in cultured skin fibroblasts from patients and parents. *J. Clin. Endocrinol. Metab.* 59, 383-388.
73. Hochberg, Z., Benderli, Z., Levy, J., Weisman, Y., Chen, T., and Feldman, D. (1984). 1,25-Dihydroxyvitamin D resistance, rickets and alopecia. *Am. J. Med.* 77, 805-811.
74. Marx, S. J., Liberman, U. A., Eil, C., Gamblin, G. T., DeGrange, D. A., and Balsan, S. (1984). Hereditary resistance to 1,25-dihydroxyvitamin D. *Recent Prog. Horm. Res.* 40, 589-620.
75. Hirst, M. A., Hochman, H. I., and Feldman, D. (1985). Vitamin D resistance and alopecia: A kindred with normal 1,25-dihydroxy-vitamin D₃ binding but decreased receptor affinity for deoxyribonucleic acid. *J. Clin. Endocrinol. Metab.* 60, 490-495.
76. Castells, S., Greig, F., Fusi, M. A., Finberg, L., Yasumura, S., Liberman, U. A., Eil, C., and Marx, S. J. (1986). Severely deficient binding of 1,25-dihydroxyvitamin D to its receptor in a patient responsive to high doses of this hormone. *J. Clin. Endocrinol. Metab.* 63, 252-256.
77. Fraher, L. J., Karmali, R., Hinde, F. R. J., Hendy, G. N., Jani, H., Nicholson, L., Grant, D., and O'Riordan, J. L. H. (1986). Vitamin D-dependent rickets type II: Extreme end organ resistance to 1,25-dihydroxyvitamin D₃ in a patient without alopecia. *Eur. J. Pediatr.* 145, 389-395.
78. Takeda, E., Kuzoda, T., Saijo, T., Tushima, K., Naito, E., Kobashi, H., Iwakuni, Y., and Miyao, M. (1986). Rapid diagnosis of vitamin D-dependent rickets type II by use of phyto-hemagglutinin-stimulated lymphocytes. *Clin. Chim. Acta* 155, 245-250.
79. Takeda, E., Kuroda, Y., Saijo, T., Naito, E., Kobashi, H., Yokota, I., and Miyao, M. (1987). 1 alpha-hydroxyvitamin D₃ treatment of three patients with 1,25-dihydroxyvitamin D-receptor-defect rickets and alopecia. *Pediatrics* 80, 97-101.
80. Takeda, E., Yokota, I., Kawakami, I., Hashimoto, T. T., Kuroda, Y., and Arase, S. (1989). Two siblings with vitamin D-dependent rickets type II: No recurrence of rickets for 14 years after cessation of therapy. *Eur. J. Pediatr.* 149, 54-57.
81. Saijo, T., Ito, M., Takeda, E., Mahbubul Huq, A. H. M., Naito, E., Yokota, I., Sine, T., Pike, J. W., and Kuroda, Y. (1991). A unique mutation in

- the vitamin D receptor gene in three Japanese patients with vitamin D-dependent rickets type II: Utility of single-strand conformation polymorphism analysis for heterozygous carrier detection. *Am. J. Hum. Genet.* 49, 668-673.
82. Simonin, G., Chabrol, B., Moulene, E., Bollini, G., Strouc, S., Mattei, J. F., and Giraud, F. (1992). Vitamin D resistant rickets type II: Apropos of 2 cases. *Pediatric* 47, 817-820.
83. Hewison, M., Rut, A. R., Kristjansson, K., Walker, R. E., Dillon, M. J., Hughes, M. R., and O'Riordan, J. L. H. (1993). Tissue resistance to 1,25-dihydroxyvitamin D without a mutation of the vitamin D receptor gene. *Clin. Endocrinol.* 39, 663-670.
84. Lin, J. P., and Uttley, W. E. (1993). Intraatrial calcium infusions, growth and development in end-organ resistance to vitamin D. *Arch. Dis. Child.* 69, 689-692.
85. Yagi, H., Ozono, K., Miyake, H., Nagashima, K., Kuroume, T., and Pike, J. W. (1993). A new point mutation in the deoxyribonucleic acid-binding domain of the vitamin D receptor in a kindred with hereditary 1,25-dihydroxyvitamin D resistant rickets. *J. Clin. Endocrinol. Metab.* 76, 509-512.
86. Whitfield, G.K., Selznick, S.H., Haussler, C.A., Hsieh, J.C., Galligan M.A., Jurutka, P.W., Thompson, P.D., Lee, S.M., Zerwekh, J.E., and Haussler, M.R.(1996). Vitamin D receptors from patients with resistance to 1,25-dihydroxyvitamin D₃: Point mutations confer reduced transactivation in response to ligand and impaired interaction with the retinoid X receptor heterodimeric partner. *Mol. Endocrinol.* 10, 1617-1631.
87. Lin Nu-T., Malloy, P.J., Sakati, N., Al-Ashwal, A., and Feldman, D. (1996). A novel mutation in the deoxyribonucleic acid-binding domain of the vitamin D receptor causes hereditary 1,25-dihydroxyvitamin D resistant rickets. *J. Clin. Endocrinol. Metab.* 81, 2564-2569.
88. Hawa, N.S. Cockerill, F.J., Vadher, S., Hewison, M., Rut, A.R., Pike, J.W., O'Riordan, J.L.H., and Farrow, S.M. (1996). Identification of a novel mutation in hereditary vitamin D resistant rickets causing exon skipping. *Clin. Endocrinol.* 45, 85-92.
89. Mechica, J.B., Leite, M.O.R., Mendoca, B.B., Frazzatto, E.S.T., Borelli, A., and Latronico, A.C. (1997). A novel nonsense mutation in the first zinc finger of the vitamin D receptor causing hereditary 1,25-dihydroxyvitamin D resistant rickets. *J. Clin. Endocrinol Metab.* 82, 3892-3894.
90. Malloy, P.J. Eccleshall, T.R., Gross, C., van Maldergem, L, Bouillion, R., and Feldman, D. (1997). Hereditary vitamin D resistant rickets caused by a novel mutation in the vitamin D receptor that results in decreased affinity for hormone and cellular hyporesponsiveness. *J. Clin. Invest.* 99, 297-304.
91. Cockerill, F.J., Hawa, N.S. Yousaf, N., Hewison, M., O'Riordan, J.F.L., and Farrow, S.M. (1997). Mutations in the vitamin D receptor gene in three kindreds associated with hereditary vitamin D resistant rickets. *J. Clin. Endocrinol. Metab.* 82,3156-3160.
92. Zhu, W.J., Malloy, P.J., Delvin, E., Chabot, G., Feldman, D. (1998). Hereditary 1,25-dihydroxyvitamin D-resistant rickets due to an opal mutation causing premature termination of the vitamin D receptor. *J. Bone. Miner. Res.* 13,259-264.
93. Malloy, P.J., Zhu, W., Zhao, X.Y., Pehling, G.B., Feldman, D. (2001). A novel inborn error in the ligand-binding domain of the vitamin D

receptor causes hereditary vitamin D-resistant rickets. *Mol. Genet. Metab.* 73, 138-148.

94. Nguyen, T.M., Adiceam, P., Kottler, M.L., Guillozo, M., Rizk-Rabin, F., Brouillard, F., Lagier, P., Palix, C., Garnier, J.M., and Garabedian, M. (2002). Tryptophan missense mutation in the ligand-binding domain of the vitamin D receptor causes severe resistance to 1,25-dihydroxyvitamin D. *J. Bone Miner. Res.* 17, 1728-1737.

94a. Malloy, P.J., Pike, J.W., and Feldman, D. (1999). The vitamin D receptor and the syndrome of hereditary 1,25-dihydroxyvitamin D-resistant rickets. *Endocr. Rev.* 20, 156-188.

95. Malloy, P.J., Xu, R., Peng, L., Clark, P.A., and Feldman D. (2002). A novel mutation in helix 12 of the VDR impairs coactivator interaction and causes hereditary 1,25-dihydroxyvitamin D-resistant rickets without alopecia. *J. Bone Miner. Res.* 2002 Program & abstract, S216.

95a. Malloy P.J., Zhu W., Bouillon R., Feldman D. (2002). A novel non-sense mutation in the ligand binding domain of the vitamin D receptor causes hereditary 1,25-dihydroxyvitamin D-resistant rickets *Mol. Genet. Metab.* 77:314-318.

95b. Malloy P.J., Xu R, Peng I., Peleg S., Al-Ashwal A., Feldman D. (2004). Hereditary 1,25-dihydroxyvitamin D-resistant rickets due to a mutation causing multiple defects in vitamin D receptor function. *Endocrinology* 145, 5106-5114.

95c. Nguyen M., d'Alesio A., Pascussi J.M., Kumar R., Griffin M.D., Dong X., Guillozo H., Rizk-Rabin M., Sinding C., Bounères P., Jehan F., Garabédian M. (2006). Vitamin D resistant rickets and type 1 diabetes in a child with compound heterozygous mutations of the vitamin D receptor (L263R and R3915): dissociated responses of the CYP-24 and rel-B promoters to 1,25-dihydroxyvitamin D₃. *J. Bone Miner. Res.* 21:886-894.

95d. Zhou, Y., Wang, J., Malloy, P.J., Dolezel, Z. and Feldman, D. (2009). Compound heterozygous mutations in the vitamin D receptor in a patient with hereditary 1,25-dihydroxyvitamin-resistant rickets with alopecia. *J. Bone Miner. Res.* 23, 974-979.

96. Marx, S. J., Bliziotis, M. M., and Nanes, M. (1986). Analysis of the relation between alopecia and resistance to 1,25-dihydroxyvitamin D. *Clin. Endocrinol.* 25, 373-381.

97. Strumpf, W. E., Sar, M., and Reid, F. A. (1979). Target cells for 1,25-dihydroxyvitamin D in intestinal tract, stomach, kidney, skin, pituitary and parathyroid. *Science* 206, 188-190.

98. Li, Y.C., Piroo, A.E., Amling, M., Delling, G., Baron, R., Bronson, R., and Demay, M.B. (1997). Targeted ablation of the vitamin D receptor: An animal model of vitamin D-dependent rickets type II with alopecia. *Proc. Natl. Acad. Sci. (USA)* 94, 9831-9835.

99. Yoshizawa T., Handa, Y., Uematsu, Y., Takeda, S., Sekine, K., Yoshihara, Y., Kawakami, T., Arioka, K., Sato, H., Uchiyama, Y., Masushige, S., Fukamizu, A., Matsumoto, T., and Kato, S. (1997). Mice lacking the vitamin D receptor exhibit impaired bone formation, uterine hypoplasia and growth retardation after weaning. *Nat. Genetics* 16, 391-396.

100. Delling, G., Demay, M.B. (1998). Normalization of mineral ion homeostasis by dietary means prevents hyperparathyroidism, rickets, and osteomalacia, but not alopecia in vitamin D receptor-ablated mice. *Endocrinology* 139, 4391-4396.

101. Malloy, P. J., Hochberg, Z., Pike, J. W., and Feldman, D. (1989). Abnormal binding of vitamin D receptors to deoxyribonucleic acid in a kindred with vitamin D dependent rickets type II. *J. Clin. Endocrinol. Metab.* 68, 263-269.
102. Malloy, P. J., Hochberg, Z., Tiosano, D., Pike, J. W., Hughes, M. R., and Feldman, D. (1990). The molecular basis of hereditary 1,25-dihydroxyvitamin D3 resistant rickets in seven related families. *J. Clin. Invest.* 86, 2017-2079.
103. Ritchie, H. H., Hughes, M. R., Thompson, E. T., Hochberg, Z., Feldman, D., Pike, J. W., and O'Mally, B. W. (1989). An ochre mutation in the vitamin D receptor gene causes hereditary 1,25-dihydroxyvitamin D3 resistant rickets in three families. *Proc. Natl. Acad. Sci. (USA)* 86, 9783-9787.
104. Takeda, E., Yokota, I., Ito, M., Kobashi, I., Saijo, T., and Kuroda, Y. (1990). 25-hydroxyvitamin D-24-hydroxylase in phyto-hemagglutinin-stimulated lymphocytes: Intermediate bioresponse to 1,25-dihydroxyvitamin D3 of cells from parents of patients with vitamin D dependent rickets type II. *J. Clin. Endocrinol. Metab.* 70, 1068 -1074.
105. Koren, R., Ravid, A., Liberman, U. A., Hochberg, Z., Weisman, J., and Novogrodsky, A. (1985). Defective binding and functions of 1,25-dihydroxyvitamin D3 receptors in peripheral mononuclear cells of patients with end-organ resistance to 1,25-dihydroxyvitamin D. *J. Clin. Invest.* 76, 2012-2015.
106. Liberman, U. A., Eil, C., and Marx, S. J. (1986). Receptor positive hereditary resistance to 1,25-dihydroxyvitamin D. Chromatography of hormone-receptor complexes on DNA-cellulose shows two classes of mutations. *J. Clin. Endocrinol. Metab.* 62, 122-126.
107. Hughes, M. R., Malloy, P. J., Kieback, D. G., Kesterson, R. A., Pike, J. W., Feldman, D., and O'Malley, B. W. (1988). Point mutations in the human vitamin D receptor gene associated with hypocalcemic rickets. *Science* 242, 1702-1705.
108. Sone, T., Marx, S. J., Liberman, U. A., Pike, J. W. (1990). A unique point mutation in the human vitamin D receptor chromosomal gene confers hereditary resistance to 1,25-dihydroxyvitamin D3. *Mol. Endocrinol.* 4, 623-631.
109. Barsony, J., Pike, J. W., DeLuca, H. F., and Marx, S. J. (1990). Immunocytology with microwave-fixed fibroblasts shows 1 alpha, 24-dihydroxyvitamin D3-dependent rapid and estrogen-dependent slow reorganization of vitamin D receptors. *J. Cell Biol.* 111, 2385-2395.
110. Sone, T., Scott, R. A., Hughes, M. R., Malloy, P. J., Feldman, D., O'Malley, B. W., Pike, J. W. (1989). Mutant vitamin D receptors which confer hereditary resistance to 1,25-dihydroxyvitamin D3 in human are transcriptionally inactive in vitro. *J. Biol. Chem.* 264, 20230-20234.
- 110a. Liberman, U. A., Eil, C., Holst, P., Rosen, J. F., and Marx, J. S. (1983). Hereditary resistance to 1,25-dihydroxyvitamin D: defective function of receptors for 1,25-dihydroxyvitamin D in cells cultured from bone. *J. Clin. Endocrinol. Metab.* 57, 958-962.
111. Kristjansson, K., Rut, A. R., Hewison, M., O'Riordan, J. L. H., and Hughes, M. R. (1993). Two mutations in the hormone binding domain of the vitamin D receptor causes tissue resistance to 1,25-dihydroxyvitamin D3. *J. Clin. Invest.* 92,12-16.
112. Weise, R. J., Goto, H., Prahl, J. M., Marx, S. J., Thomas, M., Al-Aqeel, A., and DeLuca, H. F. (1993). Vitamin D-dependency rickets type II:

Truncated vitamin D receptor in three kindreds. *Mol. Cell Endocrinol.* 90, 197-201.

113. Rochel N., Wurtz, J.M., Mitschler, A., Klaholz, B., Moras, D. (2000). The crystal structure of the nuclear receptor for vitamin D bound to its natural ligand. *Mol. Cell* 5, 173-179.
114. Rut, A. R., Hewison, K., Kristjansson, K., Luisi, B., Hughes, M., and O'Riordan, J. L. H. (1994). Two mutations causing vitamin D resistant rickets: Modelling on the basis of steroid hormone receptor DNA-binding domain crystal structures. *Clin. Endocrinol.* 41, 581-590.
115. Barsony, J., McKoy, W., DeGrange, D. A., Liberman, U. A., and Marx S. J. (1989). Selective expression of a normal action of 1,25-dihydroxyvitamin D3 receptor in human skin fibroblasts with hereditary severe defects in multiple action of this receptor. *J. Clin. Invest.* 83, 2093-2101.
116. Freedman, L.P. (1999). Increasing the complexity of coactivation in nuclear receptor signaling. *Cell* 97, 5-8.
117. Gamblin, G. T., Liberman, U. A., Eil, C., Downs, R. W., Jr., DeGrange, D. A., and Marx, S. J. (1985). Vitamin D-dependent rickets type II, defective induction of 25-hydroxyvitamin D3-24-hydroxylase by 1,25-dihydroxyvitamin D3 in cultured skin fibroblasts. *J. Clin. Invest.* 75, 954-960.
118. Balsan, S., Garabedian, M., Larchet, M., Gorski, A. M., Cournot, G., Tau, C., Bourdeau, A., Silve, C., and Ricour, C. (1986). Long term nocturnal calcium infusions can cure rickets and promote normal mineralization in hereditary resistance to 1,25-dihydroxyvitamin D. *J. Clin. Invest.* 77, 1661-1667.
119. Barsony, J., and Marx, S. J. (1988). A receptor-mediated rapid action of 1,25-dihydroxycholecalciferol: Increase of intracellular cyclic GMP in human skin fibroblasts. *Proc. Natl. Acad. Sci. (USA)* 85, 1223-1226.
120. Bliziotis, M., Yergey, A. L., Nanes, M. S., Muenzer, J., Begley, M. G., Vieira, N. E., Kher, K. K., Brandi, M. L., and Marx, S. J. (1988). Absent intestinal response to calciferols in hereditary resistance to 1,25-dihydroxyvitamin D: Documentation and effective therapy with high dose intravenous calcium infusions. *J. Clin. Endocrinol. Metab.* 66, 294-300.
121. Weisman, Y., Bab, I., Gazit, D., Spierer, Z., Jaffe, M., and Hochberg, Z. (1987). Long-term intracaval calcium infusion therapy in end-organ resistance to 1,25-dihydroxyvitamin D. *Am. J. Med.* 83, 984-990.
122. Sakati, N., Woodhouse, N. T. Y., Niles, N., Harji, H., DeGrange, D. A., and Marx, S. J. (1986). Hereditary resistance to 1,25-dihydroxyvitamin D: Clinical and radiological improvement during high-dose oral calcium therapy. *Hormone Res.* 24, 280-287.
123. Adams, J. S., and Gacad, M. A. (1988). Phenotypic diversity of the cellular 1,25-dihydroxyvitamin D3-receptor interaction among different generations of new world primates. *J. Clin. Endocrinol. Metab.* 66, 224-229.
124. Liberman, U. A., DeGrange, D., and Marx, S. J. (1985). Low affinity of the receptor for 1 alpha, 25-dihydroxyvitamin D3 in the marmoset, a New World monkey. *FEBS Lett.* 182, 385-389.
125. Shinki, T., Shiina, Y., Takanshi, N., Tamoika, Y., Koizumi, H., and Suda, T. (1983). Extremely high circulating levels of 1,25-

dihydroxyvitamin D₃ in the marmoset, a New World monkey. *Biochem. Biophys. Res. Commun.* 114, 452-457.

126. Takahashi, N., Suda, S., Shinki, T., Horiuchi, N., Shina, Y., Tanioka, Y., Koizumi, H., and Suda, T. (1985). The mechanisms of end-organ resistance to 1 alpha, 25-dihydroxycholecalciferol in the common marmoset. *Biochem. J.* 227, 555-563.

127. Gacad, M. A., and Adams, J. S. (1993). Identification of competitive binding component in vitamin D resistant new world primate cells with a low affinity but high capacity for 1,25-dihydroxyvitamin D₃. *J. Bone Miner. Res.* 8, 27-35.

128. Arbelle, J.E., Chen, H., Gacad, M.A., Allegretto, E.A. Pike, J.W., and Adams, J.S. (1996). Inhibition of vitamin D receptor-retinoid X receptor-vitamin D response element complex formation by nuclear extracts of vitamin D-resistant New World primate cells. *Endocrinology* 137, 786-789.

129. Lipsett, M. B., Chrousos, G. P., Tomita, M., Brandon, D. D., and Loriaux, D. L. (1985). The defective glucocorticoid receptor in man and non-human primates. *Recent Prog. Horm. Res.* 41, 199-241.

130. Chen, C.H., Sakai, Y., and Demay, M.B. (2001). Targeting expression of the human vitamin D receptor to the keratinocytes of vitamin D receptor null mice prevents alopecia. *Endocrinology* 142, 5386.

Copyright © 2000-2016, MDText.com, Inc.

This electronic version has been made freely available under a Creative Commons (CC-BY-NC-ND) license. A copy of the license can be viewed at <http://creativecommons.org/licenses/by-nc-nd/2.0/>.

Bookshelf ID: NBK279150 PMID: 25905373